J. N. CAUDLE, DDS

Dr J. H. Nicholson
U of Pa

BOOKS

BY

CHARLES L. SCUDDER, M.D.

---

**The Treatment of Fractures**

Octavo of 708 pages, with 994 illustrations. Cloth, $6.00 net; Half Morocco, $7.50 net. *Seventh Edition.*

---

**Tumors of the Jaws**

Octavo of 391 pages, with 353 illustrations. *Just Ready.*

PLATE I

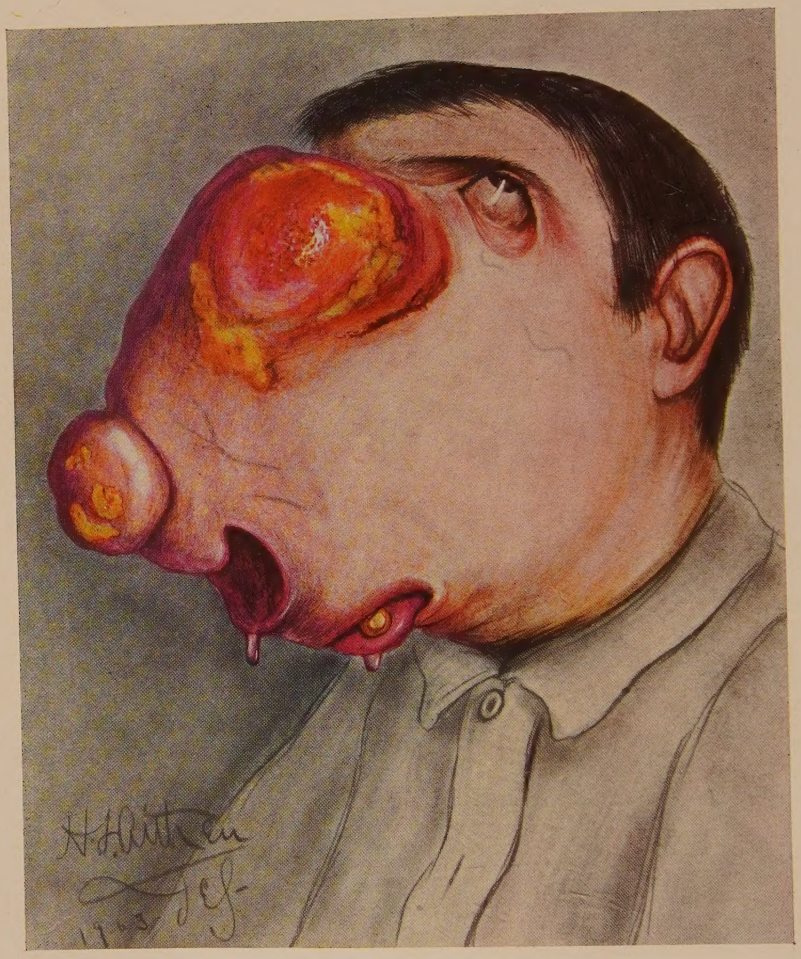

Case of osteo-chondro-myxo-sarcoma before operation (Mixter).

# TUMORS OF THE JAWS

BY

CHARLES LOCKE SCUDDER, M. D.

SURGEON TO THE MASSACHUSETTS GENERAL HOSPITAL; LECTURER ON SURGERY IN THE HARVARD MEDICAL SCHOOL; FELLOW OF THE AMERICAN SURGICAL ASSOCIATION; MEMBER OF THE SOCIETY OF CLINICAL SURGERY

*With 353 Illustrations, 6 in Colors*

PHILADELPHIA AND LONDON

W. B. SAUNDERS COMPANY

1912

Copyright, 1912, by W. B. Saunders Company

PRINTED IN AMERICA

TO

JOHN COLLINS WARREN

# PREFACE

New-growths of the jaws are uncommon. Certainly no one physician meets many cases. The infrequency of these cases increases the responsibility of the practitioner. It is important that he inform himself of these tumors.

My object in this monograph is, first of all, to assist the physician in determining in a given case what form of new-growth is present and what is its best treatment. The second aim of this monograph is to make vivid the picture of each tumor of the jaw by statistical story and by case-history, so that the physician may recognize the new-growths of the jaws in their early stages.

In American medical literature no complete description of the growths of the jaws exists.

Christopher Heath's book upon "Injuries and Diseases of the Jaws"* illustrates the case method of teaching an unfamiliar subject. It is a valuable contribution.

Perthes, of the University of Leipzig, in a monograph published as a volume of the Deutsche Chirurgie in 1907, has contributed to German medical literature the best upon this important subject. The bibliography of Perthes is valuable and is complete.

Bloodgood, of Johns Hopkins University, has contributed the most satisfactory articles in America upon new-growths

* J. and A. Churchill, 1894

of the jaws. He has paid especial attention to the pathology of these diseases.

The early recognition, by the physician, of new-growths of the jaws is the first step toward their effective treatment.

It is true of jaw growths, as of gastric diseases, that terminal conditions of malignancy are easy to recognize—early malignant diseases are difficult to diagnosticate. The terminal conditions of cancer and sarcoma have a high operative mortality; early malignant disease has a low operative mortality. Sarcoma and carcinoma of the jaws are curable if recognized and treated early, but they are most malignant and incurable if operative treatment is delayed.

The greatest effort is now being made by laboratory investigations to discover the cause of malignant disease (carcinoma, sarcoma). While this effort is being made, and until it is crowned by success, the surgeon must continue his attacks, through operative measures, upon malignant disease of the jaws. It behooves him to discover the new-growth in its initial stages if he would rid the individual of all traces of its presence.

The relative malignancy of tumors of the jaws should be more generally recognized.

Operation should depend largely upon the character of the tumor. A mutilating operation should not be done for a relatively benign form of malignant growth. On the other hand, a very thorough and much more extensive operation is demanded for the malignant growths than has been practised in the past. The surgeon should study to cure each case of jaw tumor with the least mutilation possible.

There are certain cases of malignant disease of the jaw in which a complete operation will actually do harm. These cases must be carefully selected and treated as may be most helpful, by partial operation, by *x*-ray exposure, by serums.

In cases of malignant tumor of the jaw I believe that American surgery has been too readily satisfied with getting the patient off the operating table alive, and less content to undertake, excepting in a few instances, the most radical operation.

In advanced cases of malignant disease of the jaws suitable for operative treatment a large percentage of cures is necessarily associated with a great immediate mortality. Operative technic has very greatly diminished the deaths from shock, hemorrhage, wound sepsis, pneumonia, and embolism.

The tendency of malignant disease of the jaws is to grow into the accessory sinuses of the face and toward the base of the skull. An intimate knowledge, therefore, of the anatomy of these sinuses is necessary to the operating surgeon. Illustrations of the anatomy of the various sinuses, which may prove helpful, have been here included.

I have made use of all available general medical literature in the study of this subject. I thank Dr. Richard G. Wadsworth, Dr. Robert M. Green, Dr. William C. Quinby, and Dr. Fred T. Murphy for assistance in the search of the literature.

As a basis for this monograph I have studied with great thoroughness the clinical material at the Massachusetts General Hospital, and I thank my associates upon the staff of the hospital for opportunities for study. My own surgical

experience for the past twenty years has been helpful in the study of this subject.

I thank Dr. Wm. F. Whitney, the curator of the Warren Museum of the Harvard Medical School, for valuable assistance in the study of specimens.

I am indebted to Dr. Allen B. Kanavel, of Chicago, for permission to use his article on Leontiasis, it being the latest word on this subject.

Charles L. Scudder.

209 Beacon Street, Boston, Mass.
*February, 1912.*

# CONTENTS


CHAPTER I

PAGE

Epulis . . . . . 17

CHAPTER II

Sarcoma of the Jaws . . . . . 40

CHAPTER III

Benign Tumors of the Jaws . . . . . 140

CHAPTER IV

The Odontomata . . . . . 162

CHAPTER V

Carcinoma of the Jaws . . . . . 240

CHAPTER VI

The Diagnosis and Operative Treatment of Malignant Disease of the Upper and Lower Jaws . . . . . 284

CHAPTER VII

Tumors of the Palate . . . . . 319

CHAPTER VIII

Leontiasis Ossea . . . . . 333

CHAPTER IX

Prosthesis . . . . . 354

Index of Names . . . . . 375

Index . . . . . 379

# TUMORS OF THE JAWS

## CHAPTER I

### EPULIS

CONTENTS OF CHAPTER: Epulis defined.—Age of occurrence.—Sex frequency.—Local causes.—Liability of the two jaws.—Varieties of: Fibrous; Giant-cell.—Symptoms: Beginning period; Well-marked tumor; Period of ulceration.—Course of epulis of two types.—Prognosis.—Diagnosis.—Treatment.—Summary.

EPULIS is **a topographic term.** It is applied to a new-growth apparently seated upon the gum or upper edge of the alveolar border of the jaw. Epulis really originates from the alveolar periosteum or connective tissue beneath the mucous membrane. (See Figs. 1 and 3.) It is one of the most common tumors of the jaw and one of the least malignant. It is a slowly growing jaw tumor.



Fig. 1.—Colored girl, aged sixteen. Upper jaw. Tumor one year. Tumor surrounds teeth between canine and last molar; lobulated, smooth, covered with mucous membrane. Sections: angiofibroma, some evidence of inflammation (Bloodgood).

An epulis is a border-line tumor: it lies midway between inflammation, on the one hand, and a neoplasm, on the other. When looked upon as a neoplasm, it is still a border-line lesion between the benign and the malignant

connective-tissue tumors. It is frequently called a sarcoma (Bloodgood).

**Age of Occurrence.**—It appears most often in childhood and young adults. In a series of 117 cases, the third and fourth decades were most frequently involved.

**Sex Frequency.**—In a series of 167 cases it occurred 49 times in men and 118 times in women.

**Local causes** are recognized as important. The irri-

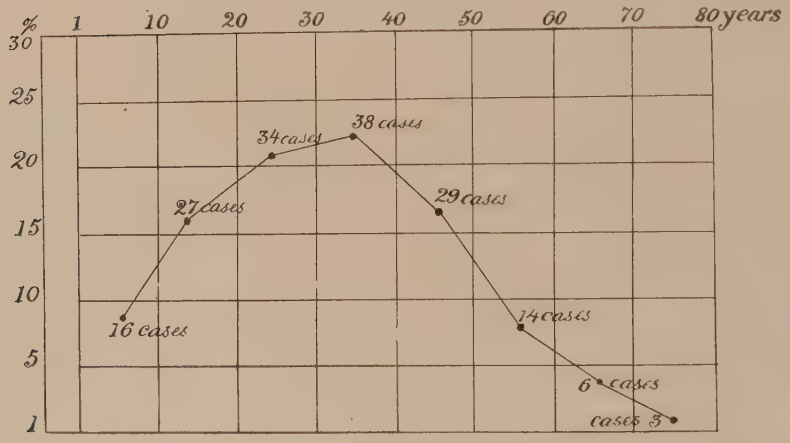


Fig. 2.—Table showing the frequency, in percentage, according to age of the occurrence of sarcomatous epulis (167 cases taken from several clinics).

tation of a carious tooth may start an epulis. If a tooth has been broken in extraction, the remaining root may serve as irritation enough to cause an epulis to grow. Trauma to a preëxisting epulis which has been almost stationary may cause it to grow rapidly. Epulis may start next a normal tooth.

**Liability of the Two Jaws.**—The two jaws are about equally liable to the disease. In a series of 132 cases 61 were in the upper jaw and 71 were in the lower jaw.

When the teeth are simply pushed apart, the growth is usually less malignant than when the teeth are lifted or pushed directly up. When the teeth are lifted and loosened by the growth, the tumor is more likely to have originated within the bone. The tumor originating within the bone is often a giant-cell epulis.

Fig. 3.—Microscopic appearances of a typical giant-cell epulis (W. F. Whitney).

Epulis appears in order of frequency near the canine, the bicuspids, the first molars, and the incisors. It almost never appears behind or fastened to the root of the last molar. (See Figs. 18 and 19, illustrating an exception to the common experience.)

Epulis stands between the slightly malignant, really benign connective-tissue tumors, and the malignant connective-tissue tumors (Bloodgood).

The **two varieties of epulis** are the fibrous epulis and the giant-cell epulis or sarcomatous epulis. The giant-cell variety of epulis is the most common form of epulis (Figs. 3, 4, 6, and 7).

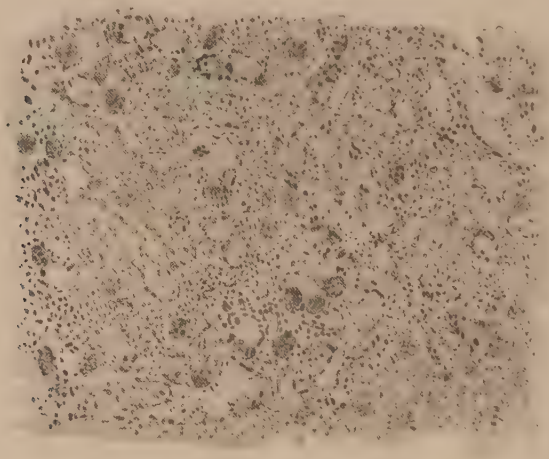

Fig. 4.—Microscopic appearances of a typical giant-cell epulis (W. F. Whitney).

The **fibrous epulis** is ordinarily of small size, projecting between two teeth, which it loosens. It then spreads out over the alveolar border (Figs. 5, 8, and 13).

The fibrous epulis may become calcified extensively or in limited areas throughout its substance.

The fibrous epulis is not very vascular (see Fig. 18), consequently the mucous membrane over it is normal in appearance. At a later period in the growth of the fibrous epulis there may appear areas of necrosis and ulceration

PLATE III

Epulis of the upper jaw. Note the color, mucous membrane evidently intact, situation of the tumor, one tooth already extracted (after Mikulicz).

from pressure of the teeth upon the surface of the growth. The fibrous epulis arises from the alveolar dental periosteum or the connective tissue between the bone of the alveolar border and the mucous membrane of the gum surrounding the teeth (Bloodgood). It often appears that the epulis arises from the interior of the tooth socket. It may arise



Fig. 5.—Microscopic appearances of a typical fibrous epulis (W. F. Whitney).

from a normal tooth socket, whereas from the socket of a carious tooth the giant-cell epulis more often seems to develop.

The softer **giant-cell sarcomatous epulis** forms a soft, red, irregularly rounded mass, seen at the gum border in the inside of the tooth. In it are many vessels; conse-

Fig. 6.

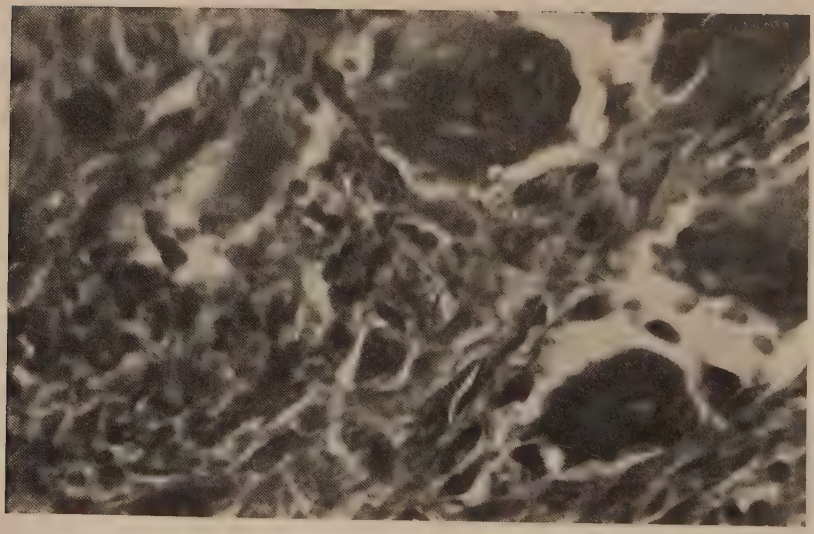

Fig. 7.

Figs. 6 and 7.—Photomicrographs of giant-cell epulis. Fig. 6 represents a low-power view; Fig. 7, one in which details are more highly magnified (from originals, loaned by Joseph C. Bloodgood).

quently it bleeds easily upon slight trauma. A very vascular epulis may pulsate.

The epulis rarely grows to a large size, for the patient is usually operated upon early. The bone is rarely invaded by epulis. Cases are recorded in which the tumor has grown upward and invaded other parts, or has protruded

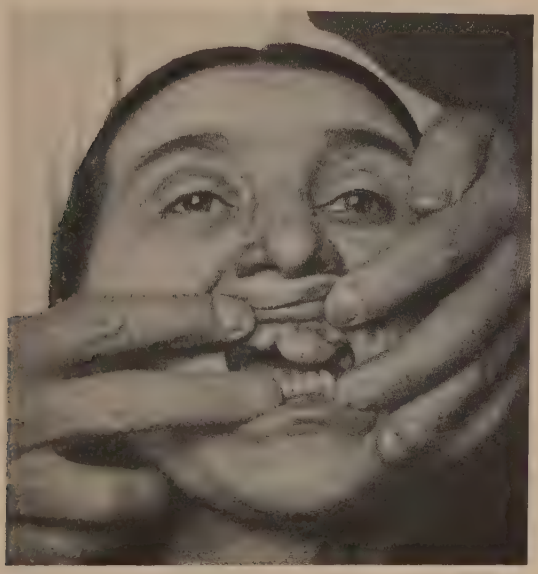

Fig. 8.—Fibrous epulis of the upper jaw, alveolar margin. Note the dry firm-looking tumor (Perthes).

from the mouth and caused great deformity. It resembles, under these conditions of rapid and destructive growth, the more malignant types of sarcoma.

There may be spicules of bone through the giant-cell epulis. These spicules of bone suggest the origin of the tumor from periosteal cells which are capable of forming

new bits of bone. There may be, too, cysts found upon section of these tumors.

Gunzert has called attention to the fact that epulis which has remained quiescent may begin to grow rapidly during pregnancy. Recurrences of epulis are likely to appear during pregnancy and to grow less rapidly after confinement.

Fig. 9.—A case of chloroma of the jaw. These photographs (see Fig. 10) represent the condition six months after the onset of the disease. The patient lived one year after this time. There were enlarged glands in the neck. The growth extended across the roof of the mouth, and the oral mucous membrane was universally hypertrophied so that the patient could take only liquid food for some months before death (case of S. L. McCurdy). (See Trans. of Asso. of Am. Physicians, 1904, vol. xix, Annals of Surgery, Jan., 1910, and Aug., 1910.)

**Symptoms.**—Three periods are distinguishable in the growth of epulis (Gruet):

1. The beginning period (the tumor is not easily recognized).

2. The period of well-marked tumor.

3. The period of ulceration—a rare ending for epulis.

1. **The Beginning Stage.**—At this time we cannot find a tumor: it is not yet visible. The patient seeks aid from a physician solely on account of the functional distress occasioned by the growth.

If the tumor arises in the socket of the tooth, it presses on the nerve at the root and causes a toothache or neuralgia, or simply a feeling of pressure. The pain may not



Fig. 10.—A case of chloroma of the jaw. A rare condition, affecting here both jaws on lingual and buccal aspects. The growth suggests a leukemic lymphoma, resembles in some ways a sarcoma, in other ways a myeloid proliferation not easily confused with ordinary epulis (case of S. L. McCurdy). (See Trans. of Asso. of Am. Physicians, 1904, vol. xix, Annals of Surgery, Jan., 1910, and Aug., 1910.)

be limited to any particular tooth, but may radiate throughout the surrounding gum and cheek and jaw.

Upon examination of each tooth carefully one tooth will be found to be more painful than the others, especially after the paroxysm of pain has ceased. It will be in the alveolus of this particular tooth that the tumor will be found to be developing.

Fig. 11.—Giant-cell epulis, rapidly growing type. This tumor had been but five weeks developing. Note the vascular (dark) tumor. This tumor bleeds readily when touched (Perthes).

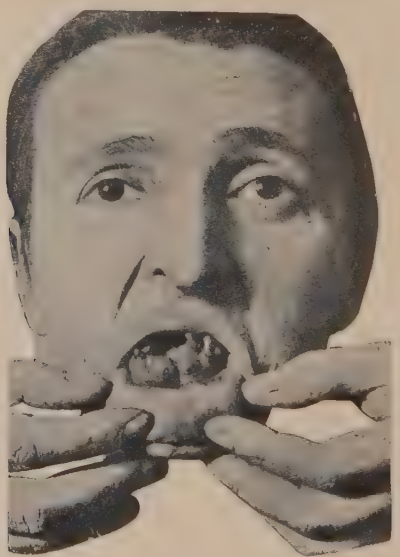

Fig. 12.—Epulis, giant-cell. Note the situation. Note the fullness of the tumor under the alveoli of the incisor teeth roots. These teeth are loose. Note the soft appearance of this tumor. The teeth situated in the tumor and on it are almost seen to be movable (Partsch).

As the tumor grows it may gradually raise the tooth above the level of the adjoining teeth. The tooth may even be pushed out of its socket completely. The patient goes to a dentist. If there is a "bad tooth" in the immediate neighborhood, the dentist extracts it or he applies local remedies. If the tooth is extracted, there is instant relief.

Fig. 13.—Typical fibroid epulis (S. L. McCurdy).

The patient thinks himself well until he sees a small tumor growing out of the alveolus.

**2. The Established Period, the Period of the Tumor.**—The epulis appears as a small, smooth, rounded, red, finely lobulated, vascular tumor. (See Figs. 8 to 12.)

Its size is variable. It may be as small as a pea or the size of a cherry or an olive. (See Figs. 11, 12, 13.) If the patient has had nothing done for it and has allowed it to

grow uninterruptedly for some time, it may attain great size. (See Figs. 21, 23.) Ordinarily, the growth is small—like an olive or smaller.

The epulis is always seated upon the alveolar border or edge near the neck of the teeth or empty teeth sockets. One or more teeth are usually included in the tumor (Fig.

Fig. 14.

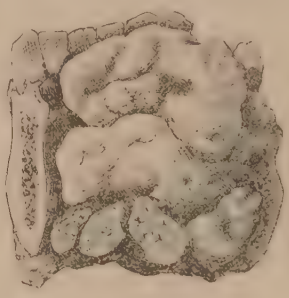

Fig. 15.

Fig. 14.—Fibrous epulis of the lower jaw.

Fig. 15.—Same as Fig. 14, showing the attachment and probable origin from the inner side of the alveolus.

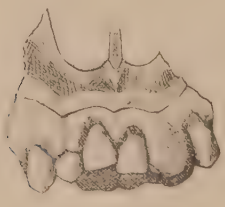

Fig. 16.

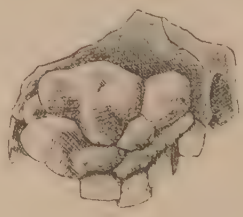

Fig. 17.

Fig. 16.—Epulis of the upper jaw.

Fig. 17.—Same as Fig. 16, showing the development of the tumor on the inner side of the alveolar process.

12). The swelling is first seen on the inner side of the alveolar process. (See Figs. 14, 15, 16, and 17.) The tumor extends to the outer side eventually, but almost always involves the inner side most definitely.

There is little or no infiltration of the mucous membrane

Fig. 18.—Giant-cell epulis of right lower jaw; painless growth three years in white male, aged fifty. The last two molars have been lost, after the appearance of the tumor (from original, loaned by Joseph C. Bloodgood).

Fig. 19.—Fresh specimen showing section and surface of tumor illustrated in Fig. 18. Giant-cell epulis (from original, loaned by Joseph C. Bloodgood).

or gum. This fact serves to differentiate it from an inflammatory process (Bloodgood). The epulis may at first be thought to be an ordinary "gum-boil." It may be that the immediate occasion of the detection of an epulis is the patient coming to the physician to have the supposed gum-boil lanced.

In epulides of the upper jaw the thickening or infiltra-

Fig. 20.—Giant-cell epulis of the alveolar border of the jaw (Perthes).

tion will extend farther than in the lower jaw, often extending over on to the hard palate. The gum in the region of an epulis is perfectly healthy. Epulis rarely, if ever, originates beyond the last molar tooth. (See Figs. 18 and 19.) Epulis is most commonly found about the canine and bicuspid and first molar teeth; quite rarely about the incisor teeth (Fig. 20).

Broca reports a fibrous epulis that grew so large in eight years that the nose disappeared within the tumor.

Liston records a case (see Figs. 21 and 22) which illus-

Fig. 21.—Fibrous epulis of the upper jaw. Duration of growth, eight years. Removed successfully by Liston in 1836. (Liston, "London Lancet," Nov. 5, 1836.) Note the firm, solid appearance of the tumor (Heath).

Fig. 22.—Same patient as shown in Fig. 21, after the removal of the large fibrous epulis (Heath).

trates the great size to which the fibrous epulis may grow. This was removed successfully. There is no true hemorrhage from an epulis, but there may be an oozing of blood occasioned by trauma of the surface of so vascular a growth. The case of Bannister is of interest in this connection. (See Figs. 23, 24, and 25.)

Palpation finds the tumor closely attached to the bone.

Fig. 23.—Epulis of lower jaw which has attained enormous size (Bannister, Barbados, W. I.).

Fig. 24.—Epulis of lower jaw. A side view of Fig. 23. Note the encroachment of the tumor upon the opening of the mouth (Bannister, Barbados, W. I.).

The attachment is sometimes broad, but more often narrow. If the growth starts from the socket of a tooth, a distinct pedicle of the tumor will be found.

The consistence of these epulides is dependent upon their vascularity and upon the amount of fibrous tissue present. The more vascular, the more soft and fluctuating they feel. (See Fig. 26.)

**3. Period of Ulceration.**—Epulis rarely ulcerates, but sometimes does. The picture may be complicated if ulceration occurs. The ulceration is like that of sarcoma, rather than that associated with carcinoma. It is the ulceration caused by pressure rather than by infiltration. The mucous membrane, distended over the tumor and irritated by friction, breaks down through lack of circu-

Fig. 25.—Epulis of the lower jaw. Appearance after removal of the tumor (Bannister).

lation, and the irregular opening thus caused, with edges undermined, permits of a protrusion of the growth.

Following such ulceration glandular enlargement may occur, due usually to a secondary infection.

The **course of epulis** of the fibrous type is very slow indeed. After years of growth the tumor may attain considerable size. The softer, more vascular, giant-cell type of epulis is more rapidly growing.

Certain of the giant-cell growths may become more malignant, invading the jaw and manifesting all the signs of a truly malignant sarcoma. The recurrences of what seem to be simple epulis are very apt to be more malignant than the original growth.

The **prognosis** of epulis after the operation of excision is good. The fibrous form never recurs once it is removed.

Fig. 26.—Fibrous epulis developing in a woman fifty-nine years old. It had been growing for about two years. Note that the tumor seen within the mouth has pushed the cheek outward. The nasolabial fold is obliterated on the side of the tumor (Perthes).

The giant-cell type of epulis does not recur if the tumor and its seat and a bit of the bone beneath its seat be removed.

Very rarely an alveolar epulis may develop as rapidly as a central sarcoma, and grow with terrible speed, the most radical operation failing to check the growth and prevent a fatal end.

Certain epulides after a slow growth for a long time will suddenly begin to grow rapidly and develop in a dangerous way.

The prognosis in epulis of the sarcomatous type should be guarded. Benignancy is the rule, but malignancy may be the rare exception.

**Diagnosis.**—In the early stage all causes of neuralgia must be considered before it can with definiteness be stated that in the particular case it is due to epulis. Local conditions giving rise to pain must also be considered—a carious tooth, sensitive to heat and cold, a periostitis about the tooth, sensitive to pressure and percussion. Each of these conditions must be reckoned with. Caries of the tooth may be the beginning of epulis.

In a young individual an *odontoma* and a *cyst* about the root of a tooth are to be considered.

Lymphatic involvement is absent ordinarily unless there be some secondary infection present.

*Granulomata* or papillary growths from a malignant base must not be confused with an epulis.

Haasler has described *root granulomata*—granulomata attached to and starting from the roots of carious teeth.

A *gum-boil* or dental abscess—*alveolar abscess*—is recognized by its local tenderness, its circumscribed edema and infiltration, and the presence of pus.

*Fungosity* of the gums need not be confused with epulis.

*Actinomycosis*, which usually begins in a carious tooth socket, soon has distinctive characteristics, such as the ray fungus in the puriform discharge, great swelling of the gums extending to the body of the jaw, and swelling of the submaxillary region.

*Retained wisdom teeth* may be confusing in diagnosis at first because they cause pain and swelling. In a tumor of the gum one should be sure that no teeth are missing from the patient's jaws. An *odontoma* (dentigerous cyst and an adamantine epithelioma) growing at first within the jaw, later coming to the alveolar surface, projecting beneath the gum, may suggest an epulis. Usually one or more teeth are absent. Any tumor which appears in the jaw after the full development of all the teeth cannot be an odontoma.

*Sarcoma* of the jaw, even if it starts in the alveolar border, spreads so rapidly to the body of the jaw that it is ordinarily distinguishable from an epulis.

*Carcinoma of the mucous membrane* of the alveolar border is a common disease and may be mistaken for epulis. The early ulceration, the rather rapid progress, the easy bleeding, the fetid characteristic discharge from the mouth, the early involvement of the submaxillary lymphatics, the severity of the pain, the constitutional disturbance—all present a picture characteristic of carcinoma and not characteristic of epulis. The ulceration of sarcomatous epulis is quite rare and presents a different picture. It occurs from mechanical causes, is not complicated by hemorrhage nor usually by glandular enlargement, and its progress is much slower and without any impairment of the general health.

With an epulis the anatomic characteristics of the jaw are maintained; the sulcus between lip and jaw, and that between cheek and jaw, remain normal. The epulis tumor rests on the alveolar ridge; it does not eat into the bone.

Having determined that the growth is an epulis, the

question arises, Is it a fibrous epulis, or a giant-cell epulis more nearly resembling a sarcoma?

*The fibrous epulis* is well circumscribed; it is uniformly firm and smooth, without projections. The mucous membrane over it is usually perfectly healthy. It grows very slowly and rarely reaches great size. It demands less radical treatment than the more common giant-cell epulis.

*The giant-cell epulis* has, on the other hand, a deeper red venous color, appears more vascular, and bleeds easily. It also may appear like erectile spongy tissue. There are projections and irregularities on the surface. It resembles at times granulation tissue. The consistence is not uniform. In certain places it is hard; in other parts it is soft. It grows more rapidly than the fibroma, and attains a larger size. It is the common form of epulis.

**Treatment.**—Epulis is a tumor that can be cured.

As ordinarily treated, the tendency is for epulides to recur locally. In fibrous epulis excision and cauterization of the base of the growth are sufficient to effect a cure.

In the case of a giant-cell epulis the adjacent teeth and a portion of the alveolar process of the jaw should be removed, together with the overlying gum and mucous membrane.

Patients having been operated on for epulis should be carefully watched at intervals until all likelihood of recurrence is past. The recurrence of an epulis is likely to prove more obstinate in removal than the original growth.

Shaving off the epulis and applications of nitrate of silver are unsatisfactory. The growth often seems stimulated thereby. Sometimes, in extracting the tooth from the alveolus of which the epulis springs, the whole epulis

is attached to the root of the tooth and comes away with the tooth.

Removal should be early and complete.

*The Safest Treatment for Epulis.*—Draw the tooth situated on either side of the growth, notch the bone with a thin small saw on both sides of the tumor, and with a chisel remove the alveolar border bearing the growth thus marked out.

In a certain few cases I should agree with Bloodgood that if it is important to save a normal tooth next an epulis, and if the anatomic relations of the growth to the alveolar process and tooth socket are favorable, a removal by the knife and thorough cauterization with the actual cautery are justifiable. This may be done safely, however, in my opinion, in comparatively few cases.

Drawing the teeth assists in the eradication of the growth, and also (Salter) causes a wasting of the alveolus and very materially assists in combating recurrence.

It is never necessary to make a complete section through the lower jaw for the removal of an ordinary epulis. It is wise to avoid an incision from the angle of the mouth to reach a difficult epulis. It is better to incise at the midline of the lip. This will rarely be necessary.

**Results in several clinics after operation:**

The radical operation in 18 cases at the Heidelberg clinic, according to Wassermann, resulted in 15 cures and 3 recurrences.

Gunzert reports 38 cases—35 well and 3 recurrences. He also records one death from metastatic sarcoma of the brain following extirpation of a fibrosarcomatous epulis of the jaw.

Bloodgood has never known epulis to give rise to metastasis. Of 40 operations for epulis at the Johns Hopkins Hospital clinic, all have remained well, including the recurrent cases.

At the Massachusetts General Hospital clinic there were 19 cases of epulis during a ten-year period. Those in which the alveolar border was removed have had no recurrence. I know of no metastasis at the Massachusetts General Hospital clinic in epulis cases.

Recurrences after operation are likely to occur if the base and origin of the growth is not removed. Otherwise recurrence is unusual.

**Summary.**—An epulis is a connective-tissue tumor midway in malignancy between a fibroma and a giant-cell sarcoma. It is seated on the alveolar border of the jaws about the teeth. It occurs in very young adults. It occurs in girls more often than in boys. It is often caused by local irritation about the teeth. It may be fibrous or contain many giant-cells. It is often mistaken in its early stages for a gum-boil. It is locally malignant. It is curable by operation. Metastases do not occur. It may be confused with an alveolar giant-cell sarcoma or a carcinomatous ulcer. It should be thoroughly removed.

# CHAPTER II

## SARCOMA OF THE JAWS

CONTENTS OF CHAPTER: (*A*) *Facts regarding sarcoma of both upper and lower jaws:* Origin of sarcoma.—Histologic groups.—Rate of growth.—The relations of sarcoma to the age of the individual.—Occurrence in the two jaws according to age periods.—Material studied.—Central and periosteal varieties.—Mixed sarcoma.—Round-cell sarcoma.—Part of jaw first attacked.—Relative frequency of occurrence in male and female.—Etiologic importance of trauma.—Melanosarcoma. (*B*) *Sarcoma of the upper jaw:* Symptoms—(1) Early period: Troubles with the teeth; The antrum; Nasal polyp—(2) Well-established period—(3) Late period.—Summary of clinical picture.—Characteristic signs of sarcoma of the upper jaw.—Diagnosis.—Prognosis.—Mortality from operation *per se.*—Causes of death after operation: (*a*) Sepsis; (*b*) Hemorrhage; (*c*) Pneumonia; (*d*) Shock.—Partial operation vs. total operation.—Significance of early vs. late operation.—Ultimate cures following operation for sarcoma of the upper jaw.—Cases of sarcoma from the Massachusetts General Hospital clinic.—Should operation be done in every case?—Table of cases of sarcoma of jaws occurring at the Massachusetts General Hospital clinic.—Necessity for dissecting the neck in sarcoma.—When do recurrences appear and where?—The time after operation of the appearance of the recurrence.—The necessity for the removal of the eye and the orbital plate.—Table of results of operative treatment of sarcoma of the upper and lower jaws from European clinics. (*C*) *Sarcoma of the lower jaw:* Kinds of sarcoma.—Rate of growth.—Operative mortality.—Case of sarcoma of the lower jaw followed by carcinoma.—Causes of death after operation.—Ultimate results of operation for sarcoma of the lower jaw.—End results of cases of lower jaw sarcomata from the Massachusetts General Hospital clinic.—The duration of the disease previous to operation.—Detailed account of some of the cases of lower jaw sarcomata studied.—Detailed account of certain inoperable sarcomata of the lower jaw. (*D*) *The treatment of sarcoma of the upper and lower jaw.*

### (A) FACTS REGARDING SARCOMA OF BOTH UPPER AND LOWER JAWS

SARCOMA is the new-growth of the connective-tissue group of tumors most often found in bone. It is malignant, that is, it reappears where it has been apparently completely removed, and it produces metastases through the blood-channels.

**Origin.**—Sarcoma may arise from the marrow of the bone or apparently from the periosteum covering the bone,

or from the walls of the blood-vessels of the bone. If it arises from the medulla, it is called a central (Virchow) or medullary sarcoma; if from the periosteum, it is called a peripheral or periosteal (Virchow) sarcoma; and if from the blood-vessel wall, it is called a perithelioma. The perithelioma is relatively uncommon.

**Histologic Groups.**—The sarcomata are grouped histologically according to the predominance of certain forms of cells. Many of the sarcomata contain multiple cell forms, and it is sometimes difficult to classify definitely the individual tumors. The giant-cell, round-cell, and spindle-cell forms are the usual microscopic varieties. Certain bones and limited portions of certain bones are the seats of sarcomata of a definite cell type; for instance, the giant-cell sarcoma is found most frequently in the upper end of the tibia and in the jaw.

**Rate of Growth.**—The rate of growth of the sarcoma is associated with the form of the predominant cell. Thus, the fibrosarcoma and the spindle-cell sarcoma are of less rapid growth, hence less malignant, than the round-cell sarcoma. The round-cell sarcoma is very vascular and malignant. The perithelial angiosarcoma is the most malignant of the jaw sarcomata. The giant-cell sarcoma is the least malignant type of sarcoma (Koenig).

**The Relations of Sarcoma and Age.**—Sarcoma of the jaw is a new-growth of youth and young adult life. It occasionally appears in old age. Estlander records a case at sixty-nine years of age.

Sarcoma is quite common in children, but sarcoma of the jaws is extremely rare in childhood. Dauphin in 1902 finds only 11 cases occurring in the jaws of children. A

case of sarcoma of the upper jaw in a child ten years old is illustrated in Figs. 90 and 94. In childhood the cases have usually occurred between six and fourteen years of age. There is one case of sarcoma of the upper jaw recorded by Williams in a child three and a half years old.

The form occurring in infancy and childhood is the giant-cell variety. Giant-cell sarcoma is rather unusual after thirty-five years of age. Spindle-cell and round-cell sarcomata most often occur in adult life and old age.

**The occurrence of sarcoma in the two jaws according to age periods** is illustrated by the accompanying tabulation:

| Age at Operation. | Both Jaws. | | Upper Jaw. | | Lower Jaw. | | Total. | Per cent. |
|---|---|---|---|---|---|---|---|---|
| | Birnbaum. | Batzaroff. | Martens. | Stein. | Behm. | Schmidt. | | |
| 1–10 | 2 | 2 | 1 | 5 | 2 | 1 | 13 | 8.8 |
| 11–20 | 2 | 4 | 2 | 6 | 4 | 3 | 21 | 14.1 |
| 21–30 | 6 | 7 | 3 | 8 | 1 | 4 | 29 | 19.5 |
| 31–40 | 7 | 7 | 5 | 5 | 2 | .. | 28 | 18.9 |
| 41–50 | .. | 9 | 3 | 5 | .. | 2 | 17 | 11.5 |
| 51–60 | 3 | 4 | 6 | 2 | 7 | 2 | 24 | 16.2 |
| 61–70 | 2 | .. | 7 | 2 | 2 | .. | 13 | 8.8 |
| 71–80 | .. | .. | .. | 1 | 1 | .. | 2 | 1.4 |
| 81–90 | .. | .. | .. | .. | .. | 1 | 1 | 0.7 |

The largest number of cases appeared under fifty years of age.

In the Massachusetts General Hospital series of cases of sarcoma of the upper and lower jaws the number of cases according to age periods is interesting:

From 1 year to 10 years . . . . . there were 2 cases
From 10 years to 20 years . . . . . there were 4 cases
From 20 years to 30 years . . . . . there were 4 cases
From 30 years to 40 years . . . . . there were 3 cases
From 40 years to 50 years . . . . . there were 6 cases
From 50 years to 60 years . . . . . there were 4 cases
From 60 years to 70 years . . . . . there were 3 cases

There was a total of 26 cases. Nineteen, or more than half, occurred under fifty years of age.

**Material Studied.**—At the Massachusetts General Hospital clinic there are recorded 32 cases of sarcoma of the jaws exclusive of epulis. It is upon this clinical material and upon the literature that this study of sarcoma of the jaws is based. Of these 32 cases of sarcoma of the

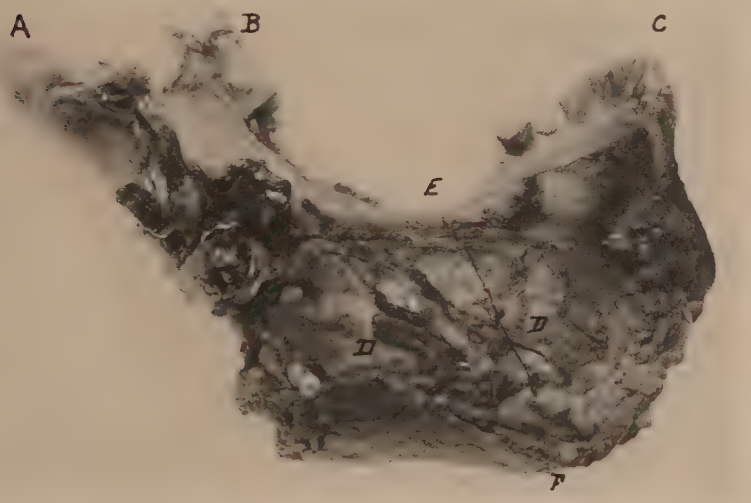


Fig. 27.—Periosteal osteosarcoma of the lower jaw, inner view: *A*, Condyle; *B*, coronoid process; *C*, incisor tooth; *D*, *D*, tumor; *E*–*F*, line of transverse section. Some bony tissue lies in the walls of the tumor. Osteoid sarcoma (Warren Museum, No. 9582).

jaws, 15 cases occurred in the upper jaw and 17 in the lower jaw. Nineteen of these cases of sarcoma occurred in men and 13 occurred in women.

In the jaw, sarcoma is a little less common than carcinoma. Especially is this true of the upper jaw. Sarcoma is more common in the lower than in the upper jaw.

Sarcoma begins in the jaw itself; it is a true tumor or new-growth of bone.

**Central and Periosteal Varieties.**—The central sarcoma of the jaw is usually of the giant-cell type. As it grows it causes a softening of the marrow and an absorption of the bone. This destruction of bone by the central growth from within is characteristic of tumors of central origin. When the growth reaches the periosteal covering, a protective thickening of the periosteum occurs, and this shell of periosteal new bone serves as a bony capsule for

Fig. 28.—White male, aged thirty-six. Tumor two years; slow growth, although the patient has made two cuts into it. Tumor surrounds incisor teeth. Soft, elastic, no ulceration of mucous membrane. Sections: typical giant-cell sarcoma (Bloodgood).

the new-growth. After this capsule is destroyed and broken through by the sarcoma, the soft parts are invaded. (See Figs. 32, 33.)

If a giant-cell sarcoma has its initial appearance elsewhere than at the alveolar margin,—that is, if it starts within the body of the jaw centrally,—it is often difficult to differentiate it from a benign growth of central origin,

for the inferior maxilla will have been expanded very much as it is by a benign cystic tumor.

The peripheral or *periosteal sarcoma* is seen to start from the periosteum, and, as Perthes states, the bone stands unharmed, surrounded completely by disease (see Fig. 29), whereas the central sarcoma destroys the interior

Fig. 29.—Periosteal round-cell sarcoma of the lower jaw. Transverse section of jaw and tumor. Note the tumor surrounding the bone (X), which remains intact, untouched by the sarcoma. *D*, Mass of tumor (Leipsic clinic).

of the jaw-bone and the growth remains surrounded by a thin, bony, shell-like protective covering. In the one instance the jaw is surrounded and only slightly involved by the disease; in the other instance the jaw is destroyed by the disease. (See Figs. 30, 31, 35.)

In the upper jaw it is difficult to distinguish between

the periosteal sarcoma originating in the antrum and a myelogenous or giant-cell sarcoma of the antrum on account of the extreme thinness of the bony wall concerned.

The periosteal sarcoma is apt to be fibrous and tough. The central giant-cell growth is soft. The periosteal

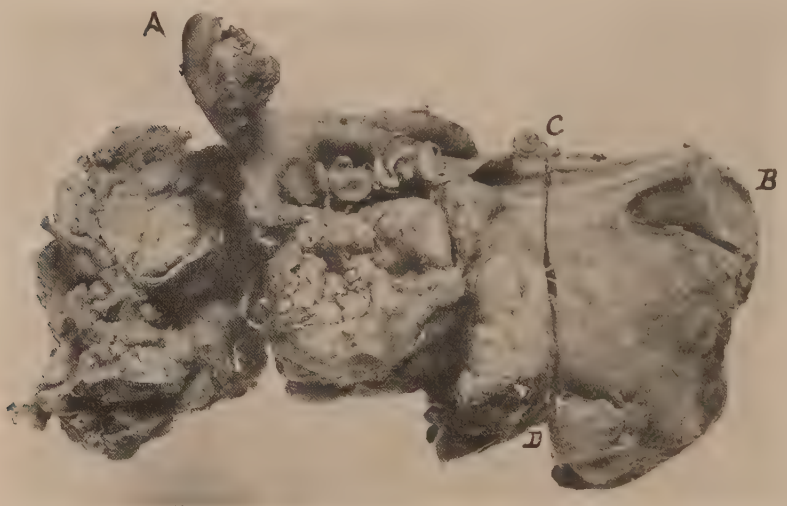


Fig. 30.—Periosteal round-cell sarcoma. Note the situation at the angle of the lower jaw. *A*, Condyle; *B*, section of bone of body of jaw. *C–D*, indicates the line of section the surfaces of which are shown in Fig. 31. Pathologic report by W. F. Whitney. A soft, grayish, lobulated, homogeneous growth, occupying the ascending ramus of the jaw and part of the body, which was atrophied and in one place entirely destroyed by the tumor growth. Microscopic examination showed large round cells with a little fibrillated and cellular substance between them, with spaces hollowed out in the tissues rather than true vessels, for the passage of the blood. In a few places the cells were elongated and rather united in bundles (Warren Museum, No. 9720).

growth often has ossifying forms, streaks of bony spicules throughout the growth.

The periosteal sarcoma of the jaw is either a mixed tumor or a spindle- or round-cell growth.

The periosteal sarcomata are often relatively benign if of the mixed variety. The periosteal sarcomata may be most malignant if of the round- and spindle-cell type, or if of the melanosarcoma type. The giant-cell or central growth is usually benign, but it may be locally quite malignant.

When the periosteal growth bursts through its bony capsule, it infiltrates the soft parts.



Fig. 31.—Cut section of Fig. 30. Periosteal round-cell sarcoma. Arrows point to the body of the jaw remaining. Bone destroyed extensively by the growth. Case from Massachusetts General Hospital series (Warren Museum, No. 9720).

Periosteal growths are attached to the bone and are not very movable. They have rather definite boundaries, a smooth surface, intact skin. The consistence is variable. It is usually softer than bone. It is almost painless.

A central growth forms a tumor or a bulging of the bone, painless to pressure, which simulates at first a tooth cyst. Later the bone on palpation over the tumor crackles, and then the growth breaks through the thin crackling shell of bone and an ulcer is formed.

**Mixed Sarcoma.**—If these periosteal sarcomata are associated with the formation of cartilage, the term *chondro-*



Fig. 32.—Central giant-cell sarcoma of the symphysis of the lower jaw. Anterior view. Note the tumor and the displaced teeth (Warren Museum No. 8429).

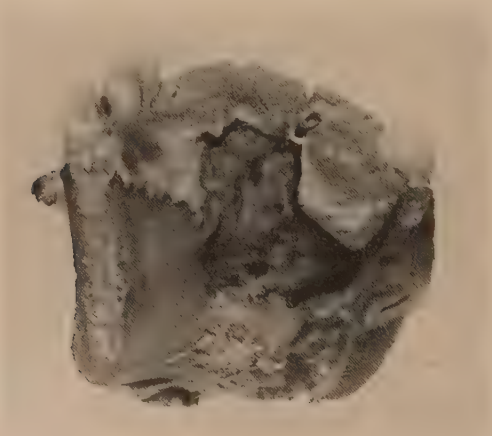

Fig. 33.—Central giant-cell sarcoma of the symphysis of the lower jaw Posterior view. Note growth within the expanded and thinned bony wall of the jaw—rare situation (Warren Museum, No. 8429).

*sarcoma* is applicable. The chondrosarcoma occurs in the upper jaw more frequently than in the lower jaw.



Fig. 34.—Giant-cell sarcoma of the lower jaw of a child six years old. A central growth in front of the molar teeth extending to the surface. Outside view (Warren Museum, No. 8426).




Fig. 35.—Inside view of Fig. 34. Note the central origin of the giant-cel sarcoma within the body of the lower jaw in front of the molar tooth: *A*, Section of symphysis; *C*, incisor tooth; *D*, carious molar tooth; *E*, inferior intact surface of body of jaw; X, tumor seen through destroyed cortex. Arrows point to growth occupying site of alveolar border (Warren Museum, No. 8426).

The term *osteosarcoma* is properly applied to those periosteal sarcomata in both the upper and lower jaws in

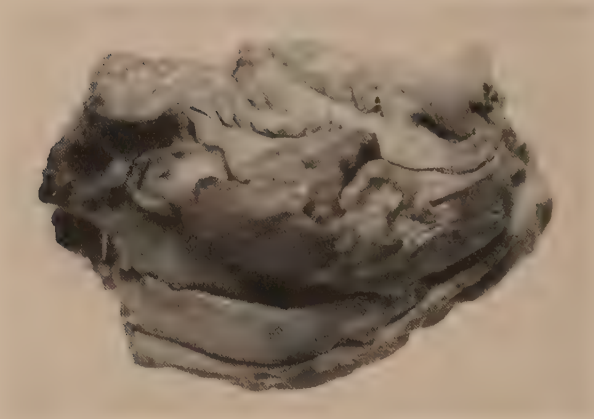

Fig. 36.—A sarcoma of the upper jaw starting within the antrum, filling it, and invading the hard palate (Warren Museum, No. 9999).

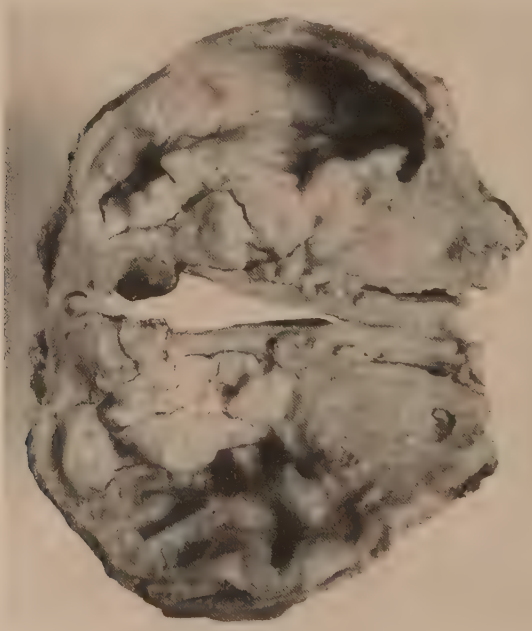

Fig. 37.—Sarcoma of the upper jaw filling the antrum; section of specimen in Fig. 36 (Warren Museum, No. 9999).

PLATE IV

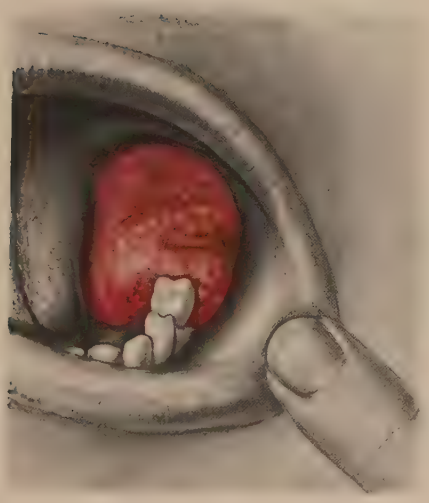

Osteosarcoma involving the lower jaw and appearing at the alveolar border. Appearance through mouth (from Mikulicz).

which ossification has taken place. These tumors are therefore spoken of as osteo- or osteoid or ossifying sarcomata.

Fibro-, chondro-, myxo-, osteo-, sarcomata, as the names indicate, define periosteal growths composed of sarcomatous tissue with large amounts of fibrous, cartilaginous, myxomatous, or bony tissue associated with them. This group of mixed tumors is the least malignant of the sarcomata. (See Plates I and II.)

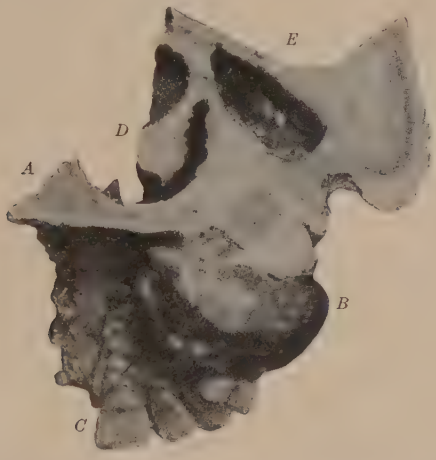


Fig. 38.—Periosteal sarcoma of the upper jaw: *A*, Hard palate; *B*, tumor; *C*, incisor teeth; *D*, nasal cavity; *E*, antrum (from the Leipsic Surgical Clinic).

When these mixed tumors recur after operation, the recurrence will often be more malignant than the original growth, and there will be less of the fibrous tissue and more of the sarcomatous element present.

These mixed tumors are relatively benign and stand between the truly benign and the malignant sarcomata. The mixed tumors are of quite common occurrence. They have their seat in the body of the jaw.

The **round-cell sarcoma** is very malignant. It occurs in the upper jaw most often, and is like the carcinoma in its virulence. It usually starts from the antrum. It is



Fig. 39.—Patient aged sixty. Tumor of lower jaw; first observed ten months ago, on inner side of teeth. Removed by curet seven months ago. Recurrence. Photograph of alcohol specimen. Microscopically, a typical giant-cell sarcoma (Bloodgood).

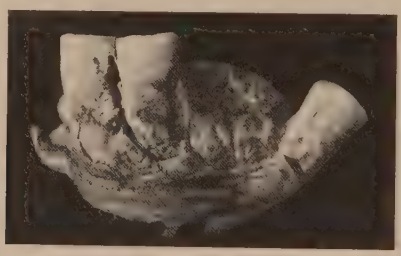

Fig. 40. —Another view of tumor shown in Fig. 39.

Fig. 41.—Another view of tumor shown in Fig. 39.

soft in consistence, of rapid growth. Upon section it is firm and white or grayish-white in color. It is occasionally

mistaken for cancer. It recurs locally early. It occurs most often in the antrum of Highmore, and therefore is known as the antrum sarcoma.

**The Part of the Jaw First Attacked by Sarcoma.**—In the upper jaw sarcoma occupies most commonly the body and alveolar process. The hard palate and frontal process

Fig. 42.—Medullary giant-cell sarcoma of lower jaw, showing tumor surrounding non-erupted tooth. White male, aged ten years; tumor three months. Resected; patient remained cured three years (from original, loaned by Joseph C. Bloodgood).

are least often involved. In the lower jaw the body and alveolar process are alike involved. The periosteal spindle- and round-cell sarcoma more often starts near the angle of the jaw and extends toward the ramus and about it. Epithelioma invades the alveolar process most commonly. The less malignant periosteal osteosarcoma starts on the

body of the lower jaw more often than on the alveolar border or the ramus.

Fig. 43.

Fig. 44.

Figs. 43 and 44.—Giant-cell sarcoma involving body of lower jaw. Patient has remained cured three years since operation. Patient of Dr. Lund, of Boston. Fig. 43 shows a side view of the jaw; Fig. 44 shows a view from above (from originals loaned by Joseph C. Bloodgood).

**The relative frequency of the occurrence of sarcoma among men and women** is seen in the accompany-

ing table. The first six clinics are computed excluding epulis.

| | Author. | Clinic. | Year. | Upper or Lower. | Number of Sarcoma Cases. | Men. | Women. |
|---|---|---|---|---|---|---|---|
| 1. | Bayer | Prag | 1874 | Both jaws | 11 | 4 | 7 |
| 2. | Birnbaum | Augusta Hospital, Berlin | 1871–1887 | Both jaws | 22 | 4 | 18 |
| 3. | Martens | Göttingen | 1875–1899 | Upper | 27 | 14 | 13 |
| 4. | Stein | Bergmann, Berlin | 1890–1900 | Upper | 34 | 17 | 17 |
| 5. | Behm | Göttingen | 1875–1902 | Lower | 19 | 9 | 10 |
| 6. | Schmidt | Greifswald | 1885–1902 | Lower | 13 | 7 | 6 |
| | | | | Total... | 126 | 55 | 71 |
| 7. | Batzaroff (Including epulis cases) | Zürich | 1881–1890 | .. | 33 | 12 | 21 |

**A Case of Giant-cell Sarcoma of the Lower Jaw to the Left of the Symphysis. Curetage. No Recurrence.**—A boy twelve years old was operated upon by Balch at the Massachusetts General Hospital clinic for a small giant-cell sarcoma of the left lower jaw, situated in the region of the incisor and canine teeth. An incision was made (see Figs. 45–48) from the angle of the mouth obliquely backward and downward, dividing the lip and cheek extensively enough to expose the growth thoroughly. The growth was removed from the bone and the seat of the growth was thoroughly cureted and cauterized with the actual cautery.

Microscopic report made by Wm. F. Whitney stated that the growth removed was a giant-cell sarcoma.

A month after the operation a small bit of dead bone was removed through a sinus in the original incision. One year following this operation the boy reports that the sinus closed shortly after the second operation, and that he has gained 13 pounds in weight and feels well.

Fig. 45.—Boy twelve years old. Giant-cell sarcoma of the left lower jaw. Removed by curetage and the actual cautery. No recurrence one year later. Note the tumor of the chin at the site of the growth (Balch).

Fig. 46.—Same as Fig. 45. Giant-cell sarcoma of the lower jaw, to the left of the median line. This case very properly occupies the border-line between an epulis and a sarcoma. No recurrence after removal (Balch).

Fig. 47.—*X*-ray of case in Fig. 45, showing that the bone is not extensively involved (Balch).

Fig. 48.—Giant-cell sarcoma of the lower jaw. Case after operation. (See Fig. 46.) Note line of incision through cheek (Balch).

Examination finds that the boy looks well, that the scar is a linear one, and that the bone at the base of the growth is smooth and covered with mucous membrane. There are no glands in the neck.

The limited operation performed in this case was indicated because of the situation of the growth, its character, and the slight involvement of the ramus of the jaw.

**In the Massachusetts General Hospital series** of cases analyzed here, including the epulis cases, there are about an equal number of male and female patients. Omitting the epulis cases, there are about one-third more male cases of sarcoma than there are female cases. One observer thinks that males are afflicted with sarcoma about three times as often as females. Nélaton says that the giant-cell sarcoma occurs equally often in the two sexes. Females are more often affected with sarcomatous epulis than are males.

**The etiologic importance of a single isolated trauma** in connection with sarcoma is more nearly settled than has been generally supposed. There is some evidence offered by good observers that a blow, acute trauma, in distinction from chronic trauma, such as the continuous irritation of a tooth on the cheek, is a determining factor in the appearance of sarcoma in one point in the bony skeleton rather than at some other point.

Coley, in his paper upon "Injury as a Causative Factor in Carcinoma," presents evidence which tends to substantiate the claim that local trauma of any kind is the direct exciting cause of certain malignant tumors. In a series of 970 cases of sarcoma a definite traumatic history was

Fig. 49.

Fig. 50.

Figs. 49 and 50.—Medullary giant-cell sarcoma beginning centrally in the symphysis. Age, twenty-one. Tumor ten months' duration. Patient has remained cured nine years (Bloodgood: Halsted's clinic).

obtained in 225 cases, that is, in 23 per cent. of the cases. The tumor developed in this 23 per cent. within the first month after the injury in 52 per cent of the 225 cases. Certainly there is a basis for the idea of an "acute traumatic malignancy."

One serious objection which has been raised to the acceptance of the importance of trauma as an etiologic factor in the production of sarcoma has been that no examination has been recorded accurately of the part involved in the disease previous to the receipt of the trauma. Coley in his paper records two cases of importance in this connection. One case was that of a fractured humerus in a man in perfect health. An *x*-ray photograph was taken immediately after the fracture, which showed normal bone. Another *x*-ray was taken a few weeks later showing a typical sarcomatous growth, proved by microscopic examination. A second case is reported by Coley in which in the wound of an inguinal hernia operation, four weeks subsequently a rapidly growing round-cell sarcoma developed.

It would seem, therefore, that evidence is accumulating to establish upon a scientific basis the theory of the etiologic importance of trauma in the causation of sarcoma. How the trauma acts, of course, has not yet been demonstrated. As Coley says, fully to explain the nature of this relation between the tumor and trauma is quite another problem than to prove that the relationship exists.

**A Case of Giant-cell Sarcoma of the Lower Jaw Following Trauma.**—*Centrally located. Resection. Nine years subsequently perfect health.* (Massachusetts General Hospital Series, vol. 383, p. 255. Service of H. H. A.

Beach.)—W. C., a boy, thirteen years old. A year and a half previous to operation he received a kick in the chin while playing foot-ball. A swelling appeared immediately after, and in three weeks had attained its present size. At no time has there been pain.

Examination finds to the right of the symphysis of the lower jaw a mass the size of a small egg, extending from the first molar on the right side to the first bicuspid on the left;

Fig. 51.—Giant-cell sarcoma of the lower jaw at symphysis. Anterior view. Before operation (Massachusetts General Hospital series).

Fig. 52.—Giant-cell sarcoma of lower jaw. Lateral view. Note that the swelling is more to the right of the median line (Massachusetts General Hospital series).

this tumor is soft and fluctuating and contains in places what feels like a shell of bone. The surface of the tumor is purple in color, is covered with large veins, and projects inside as well as outside the alveolar margin. A bit removed is proved by microscopic examination to be a giant-cell sarcoma. The whole symphysis, with a portion of the body of the jaw upon either side of the growth, was removed at operation.

*Pathologic report by J. H. Wright and W. F. Whitney:* Giant-cell sarcoma. A portion of the lower jaw, including the symphysis, covering 8 or 9 cm. in extent. On the right it was swollen to a tumor about 3 inches in its greatest diameter, and covered on the surface with a thin shell of bone. The tumor occupied the center of the bone. On section it was soft, with a reddish-gray, uniform surface.

Fig. 53.—Case of giant-cell sarcoma of lower jaw. Appearance of chin following operation. Note receding chin (Massachusetts General Hospital series).

Fig. 54.—Case of giant-cell sarcoma of lower jaw (Massachusetts General Hospital series).

Microscopic examination showed it to be composed of small spindle- and round-cells in elongated bundles, among which were large nucleated bodies. The blood-supply was in vascular spaces without distinct walls.

Nine years later there was no recurrence of the disease. The illustrations (Figs. 51 and 52) show the appearance of the boy's face. This case was reported in the "Boston Medical and Surgical Journal," 1902.

The question arises in a case of giant-cell sarcoma of the jaw seated as this was, at the symphysis: Should a resection or a partial operation be done? At the time that this resection was done the success attending curetage in giant-cell sarcoma was not recognized. Resection seemed the wise procedure. To-day in a similar case it would seem wise to remove all the growth by curetage, and, if

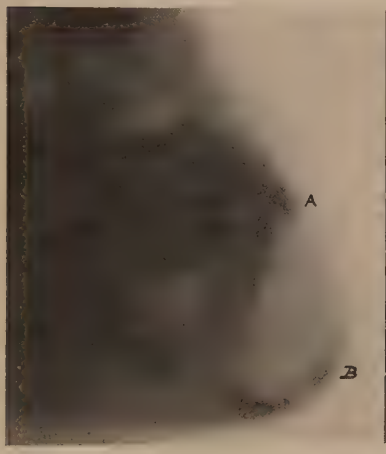


Fig. 55.—Case of giant-cell sarcoma; *x*-ray taken previous to operation. Note the thin shell of bone (*B*) surrounding the soft central growth at the symphysis of the lower jaw. "*A*," incisor teeth of upper jaw.




Fig. 56.—Case of giant-cell sarcoma. *X*-ray taken after operation. Note the absence of the symphysis of the lower jaw and also an absence of considerable of the horizontal ramus of the jaw. "*A*," incisor teeth of upper jaw.

sufficient shell of bone remained for support to the jaw, resection would be unnecessary.

There also arises the very pertinent question: May not the deformity following resection of the symphysis be at least partially corrected by some form of prosthetic apparatus? There is no doubt but that an immediate prosthesis will avoid the approximation of the proximal ends

of the divided rami of the jaw. The width of the chin can be preserved. (See chapter on Prosthesis.)

The case described (Figs. 51–56), of the Massachusetts General Hospital series, illustrated the close relationship in time frequently met with between trauma and the discovery of a swelling.

There are benign lesions following trauma to muscle and bone. The organized hematoma, the different forms of myositis, especially the ossifying myositis, and the tumor

Fig. 57.—Giant-cell sarcoma (central myeloma). Woman thirty-eight years old. Tumor of the lower jaw present for four years (Dudley, Manila, P. I.).

of the rectus abdominis muscle following labor are instances of traumatic lesions of muscles. In bones the ossifying periostitis which follows trauma is familiar. Tuberculous and pyogenic osteomyelitis may be secondary to a simple traumatic lesion. The syphilitic gumma as an ossifying periostitis may be localized by trauma.

The sarcoma may not develop immediately following trauma, but after a varying period of time has elapsed. Coley found that the tumor appeared in 117 cases within one month after the injury. Bloodgood has emphasized the importance of the practitioner being careful to bear constantly in mind the possible late effects of trauma, and I may add no matter how trivial at the time the trauma may seem to have been.




Fig. 58.—Periosteal osteosarcoma of the lower jaw—view in transverse section: X, Arrow points to the bone lying intact within the sarcoma; A, the articular process of lower jaw. A cystic cavity, 3 cm. wide, occupies the center of the tumor (Warren Museum, No. 9582).

**Melanosarcoma** occurs most commonly in the upper jaw and in the hard palate. Of the 19 cases in literature, only 2 occurred in the lower jaw. These latter were reported by Luther and Levi.

Melanosarcoma is extremely malignant, ulcerates often, grows rapidly, and causes metastases. Glands are involved in almost all cases.



Fig. 59.—Case "Loris." Note tumor of the neck in the line of the cicatrix of the original operation. This tumor was an enlarged sarcomatous gland. See text. Massachusetts General Hospital series.)

Fig. 60.—Case "Loris." *X*-ray of sarcoma of lower jaw (Massachusetts General Hospital series).

Of the 19 cases, 15 had died or were dying, 2 could not be found, and 1 only was well four months after operation (Volkmann's case).

The recurrence of a melanosarcoma may or may not contain pigment.

**Case of Sarcoma of the Lower Jaw near the Angle; Resection.**—Case of "Loris." Massachusetts General Hospital series. A man, thirty years old. For nine months he has had a lump underneath the left lower jaw. The tumor was as large as a lemon. This has been sore and tender. After his teeth were removed the soreness disappeared. The tumor is hard and firm and is attached to the jaw. The tumor is not tender.

One half the jaw with the tumor was removed by J. C. Warren. The pathologic report made by Wm. F. Whitney was a round-cell sarcoma.

One year later a gland was removed (see Fig. 59) from the neck. Six months later there was evident recurrence in the neck and region of the ear. It was then thought to be inoperable.

### (B) SARCOMA OF THE UPPER JAW

**Symptoms.**—*1. The Early Period.*—The symptoms depend somewhat upon the variety of sarcoma, its situation, and the age of the patient.

In this early period, which includes the latent time when the growth is not visible to surgeon or patient, the symptoms are largely functional difficulties. A just appreciation of these early functional disturbances will secure

these cases for surgical treatment at a far earlier period than at present.

The patient first seeks advice, perhaps, on account of trouble with his teeth. A neuralgia, referred to the teeth, is annoying. These slight neuralgias are most noticed perhaps in rather delicate individuals. A robust individual may think less of these premonitory neuralgic flashes. The dentist, upon examination, finds sound teeth, uses a counter-irritant to the gums, and, if the pain persists, later extracts a few teeth. Thus the pain may be relieved temporarily. The roots of these teeth may reveal a bit of tumor tissue, or an attached alveolar wall may tell the tale to an observant dentist.

The teeth may become loosened by the growth. The alveolar process and gums become swollen after the teeth are removed, of a blue color, and perhaps bleed easily.

Often at this time the dentist thinks only of a periostitis of the bone—an inflammatory process rare in the absence of carious teeth. He should suspect a malignant process. Careful examination should be made to determine the exact occasion for the persistent neuralgia, the loosened teeth, the spongy, swollen, and bleeding gum.

Other cases, starting in the antrum, complain of pain in the cheek, a foul discharge from one nostril, even a slight fullness of the roof of the mouth on one side, a bulging of the cheek with edema of the same, a numbness of the upper lip, cheek, and side of the nose, a swelling of the gum in the region of the canine teeth, possibly tenderness to pressure in this same anteriorly swollen region, and a swelling of the lower turbinate. The symptoms suggest strongly an inflammation and empyema of the antrum. Trans-

illumination of the cheek may be practised. If pus or a solid mass occupies the antrum, the characteristic dark area as compared with the *x*-ray appearances of the well antrum will be present. In the absence of caries of the teeth, empyema of the antrum must not be diagnosed until it is conclusively demonstrated to be present. Repeated nasal hemorrhages that do not yield to treatment suggest sarcoma.

**A Case of Lymphangiosarcoma of the Jaw.**—"Green." Massachusetts General Hospital series. (See Figs 61 and 62.) A colored man, fifty-five years old, for nine years has had trouble with the lower left half of his jaw.

Fig. 61.—Lymphangiosarcoma. Removed. Recovery (Massachusetts General Hospital series. H. H. A. Beach).

Since the removal of a tooth nine years ago there has been a lump present which has caused little local disturbance, but has steadily increased in size. (See Fig. 61.) The jaw was removed with the tumor, which was found encapsu-

lated. The patient made an excellent recovery and was alive and well six years subsequently. The tumor was a cystic lymphangiosarcoma. The tumor tissue was exam-

Fig. 62.—Lymphangiosarcoma. Removed. Recovery. Note the large ulcerating mass and the projection of the tumor into the floor of the mouth (same as Fig. 61) (Massachusetts General Hospital series).

ined by both W. F. Whitney and J. H. Wright, of the Pathological Laboratory of the Massachusetts General Hospital.

Again, the patient may present the signs of a *nasal polyp*, the polyp being merely symptomatic of the malignant disease. The patient has difficulty in breathing through one nostril, the voice is nasal, and he snores while sleeping. A mucopurulent discharge streaked with blood appears from the affected nostril. Epistaxis is not uncom-

mon. There may be slight deafness due to the involvement of the pharyngeal end of the Eustachian tube. Removal of the polyp affords an opportunity to make a microscopic diagnosis. All polyps from the nose should be carefully examined microscopically, particularly at the point of attachment. Especially is this important in cases of recurrent polyps.

If in the presence of these preliminary suggestions of malignancy no radical osteoplastic procedure is initiated for the removal of the beginning growth, then the more evident signs of sarcoma will become apparent.

In still other instances of the disease the beginning is marked by infraorbital neuralgia or a projection of the eyeball outward and upward or a swelling of the eyelids or a chemosis and a diplopia.

Certain cases seem to have so short an initial period that the disease jumps to a fully established condition, even without premonitory signs. This, of course, occurs in the very rapidly growing and fulminating varieties of sarcoma.

*2. Symptoms of the Well-established Period.*—If the disease begins in the alveolar process of the jaw, it may simulate an epulis. The growth, however, does not remain superficial; it invades the anterior wall of the antrum and finally may push its way into the nose. The nose being closed by the growth, the patient breathes through the mouth; the tongue becomes coated and dry. Sleep is interrupted. Food collecting between the gums and cheeks decomposes, and foul discharges appear in the mouth. Deglutition is difficult. Smell may be destroyed in whole or in part. Hearing may be affected. There may be roaring in the ears, which may keep the individual awake.

All degrees of tenderness of the eye appear. Epiphora exists. Conjunctivitis follows. Diplopia may be present. Pain may not be very marked in this period. A dull aching or heavy disagreeable sensation may be all the discomfort which exists in the diseased part. Crises of infraorbital or auricular pain may exist during this period.

The cheek may be swollen and edematous. The skin usually is normal in appearance; it may be ulcerated. Ulceration, however, is more characteristic of carcinoma than of sarcoma. There may be a certain amount of exophthalmos.

The swelling beneath—that is, under the lip—is rounded, smooth, and often lobulated. The hard palate is swollen and irregular—knobby in appearance. The nose is obstructed on the affected side. The obstructing mass bleeds easily.

*The tumor* is closely adherent to the bone. It is not so closely adherent to the soft parts. The tumor feels firm, although the surface is variable, *i. e.*, it is springy, almost fluctuating in parts. There is often a bogginess which is rather characteristic of sarcoma in this situation. Occasionally, too, there are hard places in the tumor surface.

*Glandular enlargement* is sometimes found at this stage in the submaxillary region, and is due to secondary inflammatory conditions present.

*The general health* now begins to be affected. There is loss of flesh, of appetite, and of color. There is a slight fever and some headache. A malignant cachexia begins to make its appearance.

*3. Symptoms of the Late Period.*—The growth of the sarcoma is at its height. The cutaneous covering of the growth becomes red, inflamed, and ulcerated, and the

sarcomatous mass appears through the ulcerated opening in the soft parts. The nasal septum is destroyed. It is not uncommon to see masses of disease growing out from the nostrils. The palate may be ulcerated through. The lymphatic enlargement becomes sarcomatous. The fever is constant. All the disturbances of function of the region become exaggerated and very marked. Deglutition and respiration become almost impossible. Emaciation is extreme and the patient soon dies.

**Summary of Clinical Picture of Sarcoma of the Upper Jaw.**—There are certain features of the early stages of this disease that it is important to remember. Sarcoma does not always begin to trouble individuals in the same way. There are different initial symptoms as well as different clinical courses.

The characteristic signs of sarcoma of the upper jaw are as follows: A sore spot on the cheek; a swelling or lump with subsequent apparent necrosis of bone; a loosening of teeth; the alveolar margin of the jaw sore, this ulceration extending to the roof of the mouth under "careful watching"; a lump in the right nostril, plugging it; a persistent, foul discharge from the nostril; intermittent bleeding from the nose; a numbness of the upper lip and cheek; "necrosis of the jaw" for many months—these are a few of the early and later manifestations of this disease of the upper jaw.

The hard palate becomes flattened, and later bulges. The orbital plate rises upward, causing a disturbing double vision. Double vision may be the only early symptom of sarcoma of the antrum.

Chronic edema of the eyelids is not rare. An enlargement of the superficial veins of the face is sometimes seen

in early sarcoma. The nasolacrimal duct being obstructed, tears will course over the cheek. Edema may be noted in one-half the nasal mucosa before it is apparent in the face. Cases are at times treated for nasal polyp for so long a time that the disease has advanced too far for successful surgical excision.

Sarcoma of the upper jaw (central), of the antrum, is often complicated with empyema of the antrum. Mikulicz has called attention to this fact. Consequently in all empyemata of the antrum it is important to consider malignant disease. Bleeding from the nose is earlier in carcinoma than in sarcoma.

If cases of sarcoma are left untreated, death usually occurs because of some complicating disease. Metastases take place to other parts, often to the lungs or the brain.

**A Case of Periosteal Sarcoma.**—"McKerlick." Massachusetts General Hospital series. A woman, sixty years old. Twelve years previously she had an ulcerated tooth. An abscess opened upon the cheek at this time and a discharging sinus persisted for a long period. In 1876 a piece of necrotic bone was removed from the left lower jaw at the site of the original ulcerated tooth. In 1880 a swelling appeared upon the lower left jaw about the size of an English walnut, at the site of the former osteomyelitis. After remaining quiescent for three years it grew rapidly. During the past two months there has been considerable pain in this swelling. At present, previous to operation, there is seen a rounded, conical tumor, the size of two adult fists, extending from the angle of the jaw forward to the symphysis. (See Fig. 63.) There are no teeth present in either jaw. The mucous membrane of the mouth is every-

*a* *b*

Fig. 63.—*a*, Osteosarcoma (periosteal) of the lower jaw. The body of the jaw was involved, rather than the ramus. *b*, Appearance soon after excision of one-half of the lower jaw for periosteal sarcoma (Massachusetts General Hospital series).

Fig. 64.—Same as Fig. 63. Appearance of left side of the face three years after removal of the left half of the lower jaw for periosteal sarcoma. No prosthetic appliance has ever been used. Note the sinking in of the region formerly occupied by the jaw, especially in region of ascending ramus in front of and below ear (Massachusetts General Hospital series)

where intact. The skin over the tumor is normal in appearance. The Roentgen ray shows a bony shell inclosing a tumor, together with bony trabeculæ extending in from the surface toward the jaw.

In 1903 one half of the lower jaw was removed. The woman, in 1906, was well and had just recovered from a hysterectomy for chronic endometritis. The illustrations were taken in 1906. (See Figs. 64 and 65.)



Fig. 65.—Appearance of face three years after removal of the left half of the lower jaw for periosteal sarcoma. No prosthetic appliance has ever been used (Massachusetts General Hospital series).

The microscopic examination made by W. F. Whitney of the tumor removed from the jaw proved it to be osteosarcoma of periosteal origin.

**A Case of Sarcoma of the Lower Jaw.**—Case of "Kessel." Massachusetts General Hospital series. (See Figs. 66 and 67.) A man thirty-eight years old had a sore upon the inside of the right cheek for some eight months.

Fig. 66.—Sarcoma of lower jaw. Note the reddening of the skin over the cheek tumor; the glandular enlargement in the neck. Inoperable (Massachusetts General Hospital series).



Fig. 67.—Sarcoma of lower jaw. Inoperable (Massachusetts General Hospital series).

For four months the whole cheek, as seen in the illustrations (Figs. 66 and 67), has been swollen. There has been little or no real pain, but considerable local discomfort. During the past two months the tumor has grown rapidly. The tumor is attached to and involves the lower jaw. The swelling seen in Fig. 66 has appeared recently and is a lymphatic enlargement. The skin over the tumor at the darkest part of the swelling (see Fig. 66) is reddened. The temperature is 100° F. The patient was discharged from the hospital without operative treatment.

Remarks: The evident cachexia (anemia); the rapid extension of the disease locally and into the lymphatics of the neck; the infiltration of the alveolar process —all made it seem unwise to attempt eradication of the disease by operation.

**Diagnosis.**—A suspicion of malignant disease in the early stages may be entertained, but a diagnosis is then most difficult. Cases presenting suspicious signs must be scrutinized with very great care. The dentist seeing such cases should communicate his forebodings of ill to a surgeon, in order that the responsibility may be shared and definite conclusions reached.

*Empyema of the antrum* which is frank and characteristic will hardly be mistaken for sarcoma. If a supposed empyema of the antrum develops slowly and insidiously without improvement under proper treatment for empyema, sarcoma should be suspected, and a bit of tissue should be removed for microscopic examination before an exploratory incision is made.

*Nasal polypi* normally do not resemble sarcoma. If nasal polypi become inflamed and are red and swollen, they

then may simulate sarcomatous tissue in gross appearance.

*Alveolar periostitis* which develops almost painlessly, accompanied by swelling of the gums, should be regarded with suspicion, and especially if a good condition of the teeth exists. When alveolar periostitis is well established, the diagnosis is not difficult.

Fig. 68.—Sarcoma of parotid. Note that the swelling lies behind the body and angle of the jaw and extends forward only secondarily (Massachusetts General Hospital series, C. B. Porter).

The antral cases, the nasal cases, those involving the palate, all present characteristic local symptoms already referred to, and the alveolar cases, which are often cases of epulis, are comparatively easily diagnosed. The multiple ulcerations, whether of cheek or mouth or palate, characterized by an undermined edge through which the tumor mass protrudes as an exuberant growth, are very characteristic.

The great fetor, the ready hemorrhage upon slight trauma, extensive glandular involvement, all may simulate carcinoma. When the disease has advanced so far that it is confused with carcinoma, it matters little, for the treatment is practically similar under either condition.

Tumors of the soft parts overlying the upper jaw must not be confused with sarcoma of the jaw. Tumors of the

Fig. 69.—Enlarged glands of neck. Woman, thirty-five years old. Jaw uninvolved. The tumor is posterior to the seat of a jaw tumor (F. W. Dudley, Manila, P. I.).

soft parts can ordinarily be demonstrated to have no connection with the bone. A sarcoma of the jaw is always very intimately connected with the bone.

*The odontomata*, unless a sarcomatous element is grafted upon them, are of rather slow growth. They are found in young people in the region of the molar teeth; one or more teeth may be lacking from the jaw.

*Dental cysts* will hardly be confused. They grow slowly

and are of small size, and present the parchment-like crepitus.

*Osteomata* are of very slow growth, are extremely hard, and are smooth and rounded.

*Gummata* may appear on the palate, but early ulceration and their association with other apparent syphilitic lesions would make it highly improbable that there could be much difficulty in diagnosis.

Fig. 70.—Enlarged glands of neck. Woman, thirty-five years old. Note temporal region and front of ear not involved. Jaw uninvolved (F. W. Dudley, Manila, P. I.).

*Carcinoma* usually occurs after fifty years of age. The growth of the disease is rapid and progressive. The glandular involvement is early in the submaxillary region. The general health is very early affected. Ulceration of the carcinomatous tumor occurs early. Carcinomatous ulcers are continuous at their edges with the mass of the growth. The margin of the ulcer is not undermined.

Several cases of sarcoma have been supposed to be syphilitic lesions. Prolonged treatment of these cases with iodid of potassium has been followed, of course, with little or no effect. Treatment of such suspected syphilitic cases with mercury has often confused the clinical picture

Fig. 71.—Sarcoma of parotid. Ulcerating. Note situation of swelling at side of face. If a growth involves the jaw and ascending ramus, it extends up more into temporal region and more anteriorly along the body of the jaw (F. W. Dudley, Manila, P. I.).

Fig. 72.—Sarcoma of parotid. Ulcerating. Note situation of swelling at side of face. Jaw uninvolved (F. W. Dudley, Manila, P. I.).

because of the salivation and offensive breath resulting, suggesting, from the picture, carcinoma.

**Prognosis.**—This depends upon the histologic character of the growth, the age of the patient, the time elapsed from the detection of the growth until operation, and the nature of the operation.

In general it may be said that, as in other situations, the giant-cell sarcoma is of slow growth, without glandular enlargement, rarely recurs after operation, and rarely gives rise to metastases.

On the other hand, the round-cell and spindle-cell sarcomata are very malignant. Sometimes an ulceration may take place directly through the cheek, although this is more characteristic of carcinoma.

**Mortality Due to the Operation.**—The exact procedure carried out at the time of the operation, the personality of the individual operator, the final diagnosis of the growth, the physical condition of the patient, the duration of the growth previous to operation—all these facts should be known concerning each case in any series where mortality figures are being studied. Mortality figures are of little value unless accompanied by all these facts.

Comisso has compiled the table (see p. 283) from the literature of resections of the upper jaw. The death-rate following total resection in recent times has dropped only about 4.5 per cent., as compared with resections done previous to 1875.

Bryant's collected cases would be of greater value if the details of the cases were mentioned and the operators' names given. He collected 114 cases of upper jaw malignant disease in which one or both (7 cases) jaws were removed, with a mortality of 13 per cent.

Butlin collects from three hospitals in London,—St. Bartholomew's, St. Thomas', and University Hospital, between the years 1886 1897, 127 cases of upper jaw tumors operated upon, with 16 deaths—practically 13 per cent. mortality.

Martens reports from König's clinic in Göttingen 74 cases with 22 deaths, or 30 per cent. mortality.

The Massachusetts General Hospital clinic presents, from 1898 to 1906,—a period of eight years,—11 cases of sarcoma of the upper jaw, with one death, due to cerebral embolism—a mortality of 9 per cent.

**A Case of Giant-cell Sarcoma of the Upper Jaw.**—R. E., a woman thirty-three years old, married. Service of C. B. Porter, Massachusetts General Hospital.

Fig. 73.—Giant-cell sarcoma of the right upper jaw. Note the tumor of the right cheek (Massachusetts General Hospital series, C. B. Porter).

The teeth of the upper jaw were unsound, so that all roots and teeth in this jaw were removed. Six years ago a false set was fitted and worn. One year ago there was

noticed an ulcer upon the gum, over the upper jaw, upon the right side. The development of this ulcer was associated with a swelling of the right cheek, which at the time of operation was the size of a lemon. This swelling is not tender or painful; the surface is smooth. The feeling of the tumor is that of a semisolid body. There is a small ulceration in the gum of the upper right jaw. There is no

Fig. 74.—After excision of the right upper jaw for giant-cell sarcoma (Massachusetts General Hospital series).

discharge from this ulcer. There are no lymphatic glands to be felt in the neck. The right nostril is occluded. There is an egg-shell crackle upon the inside, over the region of the hard palate. The right upper jaw was excised.

Pathologic report by W. F. Whitney. A growth from the upper jaw projecting forward over the teeth on the right side, covered by a thin, papery bone. On section, there were numerous spaces separated by bony partitions, filled with a homogeneous reddish, soft substance, which,

upon microscopic examination, showed small round- and spindle-cells, lying among which were numerous larger, multinucleated giant-cells. Diagnosis: Giant-cell sarcoma.

Present condition: Several years after operation the patient is in good health and has no trouble with the jaw.

The mortality of the operation in foreign Continental clinics will be seen to be surprisingly larger than that in this country. König, at the Göttingen clinic, as reported

Fig. 75.—After excision of the right upper jaw for giant-cell sarcoma. No prosthesis used (Massachusetts General Hospital series).

by Martens, had a mortality, in 74 total resections of the upper jaw, of 22 cases, or about 30 per cent. As Martens has pointed out, the relatively high mortality is not due to lack of skill in early operations, for the mortality is as great in the later cases, but the explanation lies in the fact of far more radical primary procedures. The disease is

tackled harder—the operations generally are far more extensive than those done in this country. The results of thus operating more radically are seen in the ultimate cures.

Surgeons in this country have been content with a low mortality: they have been concerned in getting the patient off the operating-table alive, and have in the past, perhaps, sacrificed completeness of operations to the immediate safety of the patient.

This is not the proper attitude to take toward malignant disease. More radical measures should be employed in these cases of jaw sarcoma. These remarks apply to sarcoma of both upper and lower jaws. Patients are simply to be told that the disease is desperately malignant, and that desperate and most radical measures are to be employed. Tampering with a growth by a small and inadequate operation is poor surgery. If greater chances are taken than hitherto in these desperate cases, the death-rate may be a little higher, but the cures will be more frequent.

**Causes of Death after Operation.**—A knowledge of the causes of death immediately following operation is of very considerable practical importance. If these causes can be eliminated, it may be possible to diminish the operative mortality.

Rabe's earlier statistics make one shudder at the tremendous mortality from sepsis, as seen in erysipelas, pyemia, etc. *Sepsis* has practically been eliminated as a cause of death. The only hold which sepsis has is shown in the occasional death from meningitis. Martens records from the Göttingen clinic three deaths from purulent meningitis. These deaths suggest the very great care which must be exercised in dealing with the accessory sinuses and the upper

and posterior chambers of the nose. If the dura is to be exposed, it must be only after extreme cleanliness of the overlying parts has been secured. The parts should be protected by a careful occlusive dressing. (See Operative Technic.)

From the Massachusetts General Hospital clinic there were no deaths from sepsis.

*Hemorrhage as a cause of death* is a small factor today as compared with the immediate past. The elimination of sepsis has done away with secondary hemorrhage. The introduction of better technic has (see Operative Technic) almost eliminated primary hemorrhage at least, any alarming primary hemorrhage.

Rabe had 112 deaths in his list of upper jaw cases; of these, 15 died of hemorrhage, or a hemorrhage mortality of 13 per cent.

Küster records 29 total jaw resections with 2 deaths from hemorrhage—a mortality of 6 per cent.

Bryant thought that about 4 per cent. of the cases he had collected had died of primary hemorrhage.

Martens reports 22 deaths following total resections, with only one death from hemorrhage—4 per cent. mortality.

At the Massachusetts General Hospital clinic there has been no death from hemorrhage.

**Case of Sarcoma of Upper Jaw. Repeated Operations.**—In the case of Steele (Fig. 76) is illustrated a very important practical point in the treatment of the less malignant type of sarcomata. The patient was kept under very

rigid observation, being seen every two or three months; the opening in the face, exposing the deeper parts, the posterior nares and the pharynx, was not closed by a plastic operation, in order that it might be possible thoroughly to inspect the most likely seat of any recurrent disease.

By postponing a plastic operation it was comparatively

Fig. 76.—Spindle-cell sarcoma of the right upper jaw. Repeated operations for small local recurrences. After seven years, death (Massachusetts General Hospital series, Steele).

easy to detect, at an early period, any recurrent nodule. The patient herself was able intelligently to inspect the seat of possible recurrence, and several times she reported a suspicious-looking spot in the posterior nares. Not only did the leaving open of the face wound enable the surgeon

and patient to inspect the suspicious area, but easy access was made possible to the very depths of the wound.

This case illustrates the value of repeated operation upon small local recurrences. This patient was operated upon some twenty times during a period of seven years or

Fig. 77.—Spindle-cell sarcoma of right upper jaw (Massachusetts General Hospital series, Steele).

Fig. 78.—Spindle-cell sarcoma of right upper jaw. Artificial eye and cheek worn by patient to preserve facial symmetry (Massachusetts General Hospital series).

more. At no time after the removal of the eye and the clearing out of the orbit was any one operation of great extent. At each procedure sound tissue was apparently divided, but despite this fact local recurrences subsequently appeared.

*The deaths from pneumonia* have been the most common form of death.

Rabe gives 20 deaths from this cause in 112 cases, or 16 per cent.

Martens records 22 deaths as a total, and of these, 16 were due to respiratory troubles, making a pneumonia mortality of 72 per cent. This is perfectly astounding.

At the Massachusetts General Hospital clinic, in the series of 26 cases, there have been no deaths from pneumonia.

In the chapter upon Operative Technic will be discussed the possible methods of eliminating pneumonia as a cause of death.

There are many deaths attributed to *shock* and *exhaustion*. These are most probably cases in which hemorrhage has been the contributing factor to the shock. There is no great shock ordinarily attending a properly executed partial or complete operation upon the upper or lower jaws.

*Martens' series of deaths* is interesting. There were 22 deaths following total resections of the upper jaw for sarcoma and carcinoma. Of the 12 *partial* resections, only one died. Death was due to pneumonia seven days after operation. Of the 22 *total* resection deaths, there were 16 due to respiratory difficulties, pneumonia, bronchitis, etc., and only 1 from hemorrhage. There were 3 deaths from purulent meningitis. There was 1 death from sepsis after six days. There was 1 case reported dead from general marasmus, which must mean from cachexia due to the disease.

Rabe collected, between 1827 and 1873, a series of 606 cases, in which series 112 deaths are recorded. One-fifth of all these cases died of sepsis. Fifteen died of hemorrhage. Twenty died of pneumonia.

Küster records 8 deaths in his series. Two of these deaths were from hemorrhage, and 4 were from pneumonia.

One death was from exhaustion and 1 was from corrosive poisoning.

**A Case of Osteochondromyxosarcoma, with Removal of the Upper Jaw and Formation of New Hard Palate (Massachusetts General Hospital Series).***—W. H. B., a man thirty years old, was sent to the hospital by Seabury W. Allen. Twenty-two years ago he had first noticed a slight swelling under the left eye. This gradually increased, until he presented the appearance seen in the illustrations. (See Figs. 79, 80, 81, 82, and Plate I.)

Fig. 79.—Case of mixed sarcoma (Mixter).

S. J. Mixter removed the tumor, leaving the two eyes and soft palate intact. (See Plate II.) He subsequently formed a hard palate from a piece of bone left in the skin-flap (antral wall). The patient made a good recovery, and was alive one year subsequently, eating, talking, and breathing without difficulty, gaining in weight, and from being shut in his room apart by himself, he now earns his living. This patient died three years later of pneumonia.

*S. J. Mixter: Trans. Am. Surg. Assoc., vol. xxii, p. 227, 1904.

Fig. 80.—Case of mixed sarcoma (Mixter).

Fig. 81.—Case of mixed sarcoma (Mixter).

**Partial Operation vs. Total Operation.** -It may be wise, in certain cases, to remove the disease without sacrificing much, if any, of the maxilla itself.

In the long bones of the body it is now recognized as sometimes wise to remove the whole of a giant-cell sarcoma, leaving the bony shaft. The statistics of Bloodgood and others, and the cases from the Massachusetts General Hospital clinic, demonstrate that in very carefully selected

Fig. 82.—Case of mixed sarcoma (Mixter).

cases of giant-cell sarcoma of the long bones, this course is safe and wise.

So in case of a giant-cell sarcoma arising from the center of the maxilla removal of the growth with the preservation of a bridge of uninvolved bone is the best procedure. The maintenance of the continuity of the bone secures stability to the face, and offers ample support for proper artificial teeth—a great desideratum.

Case of osteo-chondro-myxo-sarcoma. Result after operation (Mixter).

Case of osteo-chondro-myxo-sarcoma after recovery from the operation (Mixter).

The following operations from the Massachusetts General Hospital clinic serveto illustrate cases in which a partial operation for the removal of malignant jaw tumors was done. Microscopic examinations were made in each case.

Case 1 had existed four months. It was an osteoid sarcoma. The patient has been well and free from recurrence for five years.

Case 2 had had symptoms of trouble with the jaw, simulating necrosis of the bone, for one year previous to operation. It was a sarcoma; the type of cell was not recorded. The patient has been well without recurrence for a year and over.

Case 3 had trouble with the jaw for one year. A fibrosarcoma was removed. There has been no recurrence for eight years.

Case 4, a round-cell sarcoma, was operated upon by partial operation, and two years subsequently there is no recurrence.

Of this group, the round-cell sarcoma alone I should exclude from the routine of local excision; of all growths of sarcoma the most malignant, it should, of course, be most radically dealt with in the light of our present knowledge.

In approaching a case to which it is thought likely that a partial operation may pertain, it will be wise to operate tentatively, to make such exposure of the tumor by an incision that will permit subsequent completion of the operation as a most radical procedure, if necessary. The microscopic examination should, of course, go hand in hand with the operation, so that at the completion of the partial steps a pathologic report may be forthcoming from the laboratory, either to indicate the wisdom of the partial operation or to suggest a more radical and complete operation.

Under the above conditions only will it be safe for any operating surgeon to entertain the idea of a partial operation for malignant disease.

A partial operation may be most radical. The term should not be allowed to mean an inefficient operation.

The objects of a partial operation are the complete removal of the disease, with less mutilation and better functional results than by any other method.

**A Case of Round-cell Sarcoma of the Upper Jaw.** A woman, thirty-six years old, in November, 1907, noticed a "gum-boil" at the inner base of the right upper canine tooth. This grew rapidly to the size of a marble, and was removed by partial excision of the upper jaw in December, 1907. It proved to be a small round-cell sarcoma. Shortly after she noticed an enlargement of the glands of the right side of the neck, which were excised in February, 1908. Pathologic report: A large round-cell sarcoma. Signed, W. F. Whitney.

Fig. 83.—Round-cell sarcoma. Photograph taken just after dissection of right neck, and just before evidences of recurrence of the growth appeared (Massachusetts General Hospital series).

She was subsequently treated by Coley toxins, but in April, 1908, developed a rapidly growing recurrence in the upper lip and right cheek. She was readmitted, but was considered inoperable, and died June 14, 1908, one

year and five months following the discovery of the supposed gum-boil.

This case illustrates the futility of partial operation in

Fig. 84.—Round-cell sarcoma. Same as Fig. 83 (Massachusetts General Hospital series).

Fig. 85.—Round-cell sarcoma of the right upper jaw. Recurrent, following excision of the upper jaw (compare with Figs. 83 and 84) (Massachusetts General Hospital series).

cases of malignant sarcoma, the uselessness of the removal of metastatic glandular enlargements in evidently malignant sarcoma, and also the virulence of the disease.

Many growths starting from the antrum may be reached by a flap of the cheek turned out and back, the anterior wall of the antrum being removed; the growth can then

be scooped out thoroughly, and all its attached portions excised. The cavity of the antrum may be packed with gauze tape for twenty-four hours or more, to secure hemostasis, and then the gauze removed.

If the alveolar arch is involved, a portion of it may be excised, as is done in the case of epulis, excepting that the excision should be done much more extensively.

**Significance of Early vs. Late Operations.** The earlier after its appearance a sarcoma is operated upon, the better. Because the time that has elapsed since the appearance of the growth is short, does not necessarily mean that the operation will be successful. A most malignant type of the disease may grow rapidly and be so far advanced that even though it is a relatively and apparently early operation, it is really too late. It is, of course, true that the earlier the diagnosis is made, and the earlier the operation is done, the greater is the likelihood of curing this malignant local growth.

**Ultimate Cures Following Operation for Sarcoma of the Upper Jaw.** Recurrence following operation for sarcoma of the upper jaws certainly is the rule. Permanent cures are rare. No period of time can properly and safely be set as that within which a case may be called cured.

No patient should be considered cured if he has ever had a sarcoma of the jaw. He may be, with propriety, congratulated upon being and continuing to remain well, but the surgeon must, with the evidence before him from the best European and many American clinics, still keep in mind the possibility of an appearance of the disease locally, as a recurrence, or in a distant part, as metastasis.

Gussenbaum, from the Vienna clinic, had one case well

for four years, and during the fourth year a recurrence appeared.

Küster records a case who had a recurrence five and one-half years after operation.

Gussenbaum had 7 apparent cures. He was able to trace all but 1 of the 7 cases thought to be cured. He

Fig. 86.—Sarcoma of the upper jaw. Inoperable, because of the duration of the growth and its extent (Massachusetts General Hospital series).

found that 6 were dead—5 surely from the disease, 1 had had two operations for recurrence, 1 was well for four years and then had a recurrence.

Martens presents an interesting series of cases of sarcoma of the upper jaw after operation. *Total resection* of the jaw for sarcoma was performed 24 times. There were 4 deaths from the operation. Of the 20 cases surviving the opera-

tion, 13 showed recurrence and died. Six cases were apparently cured; 1 case had gone less than three years, so Martens did not consider this a cure. Of these 7 possible cures, 2 were round-cell sarcoma, 1 was a round- and spindle-cell sarcoma, and 4 were giant-cell sarcoma.

These 7 cases have lived now from three to thirteen years free from recurrence. Four of them have lived for

Fig. 87.—Inoperable sarcoma of the upper jaw. Note left eye displaced upward and inward by growing tumor (Massachusetts General Hospital series).

nine years free from recurrence. No glands were removed in any of these "cured" cases.

Martens reports 3 *partial operations* for sarcoma of the upper jaw: 1 of these died from the operation; 2 were cured, "having passed the three-year limit"; 1 case was an endothelioma which was well five years and nine months after operation; the second case was a round-cell sarcoma

which died nine years after operation, free from recurrence.

König thinks that the five-year period is the fair limit of time to have elapsed for a case to be considered cured.

Martens' group of cases is most instructive and should be studied with care. There were 74 operations all told for carcinoma and sarcoma upon the upper jaw.

Fig. 88.—Sarcoma of upper jaw (Massachusetts General Hospital series).

Fig. 89.—Sarcoma of upper jaw (Massachusetts General Hospital series).

Forty-eight cases of carcinoma—19 deaths from operation.

Twenty-four cases of sarcoma—4 deaths from operation.

Seventy-four operations; 33 deaths from recurrence: 20 of these were carcinoma, and 13 were sarcoma.

Of the *total* resections, there were 16 permanent cures—8 carcinoma, 6 sarcoma, 1 osteoma, and 1 myxoma.

Of the 12 *partial* resections, 9 were carcinoma and 3 sarcoma. One of the sarcoma cases died at operation—8.3 per cent. mortality. Six deaths from recurrence—all carcinoma. Two permanent sarcoma cures. Three cases too recent to consider.

Fig. 90.—Sarcoma of the upper jaw. Note characteristic fullness in temporal region.

Küster* reports 14 sarcomata of the upper jaw—9 giant-cell sarcoma; all were permanently cured. Of 5 malignant sarcoma, 2 died from operation, 3 from recurrence.

The fact that cures are recorded following operation for sarcoma in which the lymphatics were not removed and were not thought to be involved means that the glands are involved late in the disease.

In Krönlein's clinic, according to Batzaroff, in 33 cases

*Berlin. klin. Woch., 1888, Nos. 14, 15, pp. 265, 296.

of lower jaw periosteal sarcoma only 3 had involvement of the lymph-glands.

According to Martens, in 27 cases of upper jaw sarcoma in König's clinic, in only 2 cases were there metastases, and these were cases of melanotic sarcoma.

**Cases of Sarcoma from the Massachusetts General Hospital Clinic.**—I have studied with great care the

Fig. 91.—Sarcoma of the upper jaw. Appearances of a secondary recurrence following two operations. This illustrates the very great local malignancy of the growth (Kaposi).

cases of sarcoma of the jaws in the Massachusetts General Hospital clinic.

From 1898 to 1906, 26 cases upon which operations have been done are recorded.

There were 11 sarcomata of the upper jaw and 15 sarcomata of the lower jaw.

Of the 11 upper jaw cases (11 patients), 8 cases have been followed subsequently to the operation sufficiently long to make the records of value.

### Results in Eight Upper Jaw Sarcoma Cases After Operation

1 alive and well eight years after operation—fibrosarcoma.
1 alive and well nine years after operation—spindle-cell sarcoma.
1 alive and well five years after operation—osteosarcoma.
1 alive and well eight years after operation—fibrosarcoma.
1 lived two years and died of recurrence two years after operation—round-cell sarcoma.
1 alive and well ten years after operation; cell not specified—sarcoma.
1 alive two years after first operation and one year after second operation—giant-cell sarcoma. Resection both upper jaws. Had carcinoma uteri. Died of carcinoma of uterus. No recurrence at seat of jaw operation.
1 died after complete excision; round-cell sarcoma—ligation of external carotid—cerebral embolism.

Of the 12 cases of removal of the upper jaw in whole or in part only 1 died, and this one from embolism following ligation of the external carotid. The embolus was detached and followed the internal carotid, as was demonstrated by autopsy.

There were 6 complete excisions of the upper jaw in 5 patients, 1 patient having had each upper jaw removed at different operations one year apart.

### Six Complete Upper Jaw Excisions

1 is alive and well eight years after the first operation, having had several small recurrences.

1 died nine years after operation. Exact cause of death not known.

1 lost sight of.

1 died of embolism after operation.

Fig. 92.—Sarcoma of the upper jaw. Note the great pressure upon the eyeball, the distortion of the nose and mouth, and the very great evident discomfort to the individual by the tremendous pressure (Leipsic clinic).

1 had one jaw removed and then the other jaw one year later—one individual, 2 operations. No local recurrence, but patient had carcinoma uteri and died of cancer.

There were 6 partial operations upon the upper jaw. Among the partial operations there were no deaths.

SIX PARTIAL OPERATIONS

1 was alive eight years after operation—a fibrosarcoma.
1 was alive five years after operation—an osteosarcoma.
1 lived two years after operation and died—a round-cell sarcoma.
1 was alive ten years after operation—sarcoma.

Fig. 93.—Sarcoma of the upper jaw. Note the very great edema of the eyelids, the tumor of the left upper jaw (Leipsic clinic).

1 was known to have a recurrence five months after operation which was inoperable—round-cell sarcoma.
1 nothing has been heard of since operation—perithelioma, spindle-cell sarcoma.

Martens thinks that life is prolonged after operations for sarcoma of the upper jaw. At the Massachusetts General Hospital clinic, in cases of upper jaw sarcoma traced and not living or not known to be living at present—

1 case of spindle-cell sarcoma lived three years following operation, and for two years without any local recurrence.

1 case had a recurrence (round-cell sarcoma) three months following operation.

1 case of round-cell sarcoma lived two years after operation.

1 case of round-cell sarcoma died from embolism, cerebral, post-operative.

1 case of giant-cell is dead, without recurrence, with carcinoma of the uterus.

Fig. 94.—Sarcoma of the upper jaw extending to nose, orbit, cheek, and temporal region. Inoperable (Heidelberg clinic).

**Should Operation be Done in Every Case?** Although the ultimate cures are few, yet it is seen that just in proportion as the work is done thoroughly, the results are best. There is great room for encouragement to the surgeon. Sarcoma behaves as a local disease with few

early metastases and with little early glandular involvement. Metastases from upper jaw tumors are rarer than from new-growths elsewhere. The tendency at the Massachusetts General Hospital clinic, where the teaching of Warren has been personally felt, is to regard sarcoma of the upper jaw as most malignant in its tendency to recur locally at the site of the operation. König, of Göttingen,

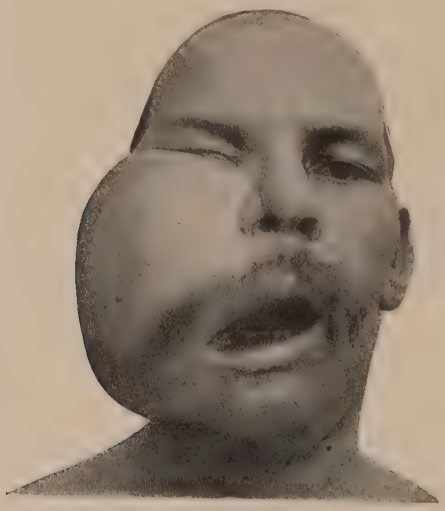

Fig. 95.—Sarcoma of the upper jaw. Total resection was done, but recurrence caused death. A malignant type of growth (Trendelenburg).

evidently feels the same way about this matter. Note the case of Steele at the Massachusetts General Hospital clinic, in which some 12 or more operations have been done for local recurrence. Note the case of Winch from the same clinic, the very rapid recurrence of whose growth is illustrated in Figs. 84 and 85.

**Is the Growth One Which it is Wise to Attempt to Remove?** It may sometimes be impossible to decide,

CASES OF SARCOMA OF THE UPPER AND LOWER JAWS OCCURRING AT THE MASSACHUSETTS GENERAL HOSPITAL CLINIC (1898–1906)

| Name. | Age. | Complete Operation. | Recovery. | Died. | Partial Operation. | Recovery. | Died. | Upper Jaw. | Lower Jaw. | Living. | Type of Cell. | Recurred in. | Lived. | Not Heard From. | Growth Existed Previous to Operation. |
|---|---|---|---|---|---|---|---|---|---|---|---|---|---|---|---|
| Steele | 29 | 1 | 1 | .. | .. | .. | .. | 1 | .. | .. | Spindle | 1 yr. | 9 yrs. | .. | 5 yrs. |
| Simpson | 35 | 1 | 1 | .. | .. | .. | .. | .. | 1 | .. | Spindle | 2 yr. | 3 yrs. | .. | 1 yr. |
| Green | 55 | 1 | 1 | .. | .. | .. | .. | .. | 1 | 6 yrs. | Lymphangioma | .. | .. | .. | Some time |
| Bowles | 10 | 1 | 1 | .. | .. | .. | .. | .. | 1 | 7 yrs. | Osteofibroma | .. | .. | .. | 6 mos. |
| Headstrom | 47 | .. | .. | .. | 1 | 1 | .. | 1 | .. | 5 yrs. | Osteosarcoma | .. | .. | .. | 4 mos. |
| Sexton | 61 | .. | .. | .. | 1 | 1 | .. | 1 | .. | 10 yrs. | Sarcoma | .. | .. | .. | 1 yr. |
| Turner | 45 | 1 | 1 | .. | .. | .. | .. | .. | 1 | .. | Spindle | 7 mos. | 1½ yrs. | .. | 3 mos. |
| Horne | 40 | 1 | 1 | .. | .. | .. | .. | 1 | .. | 8 yrs. | Fibrosarcoma | .. | .. | .. | 7 mos. |
| Campbell | 23 | 1 | 1 | .. | .. | .. | .. | .. | 1 | 7 yrs. | Adamantine epithelioma with sarcoma | .. | .. | .. | 4 mos. |
| Davis | 19 | .. | .. | .. | 1 | 1 | .. | 1 | .. | 8 yrs. | Fibrosarcoma | .. | .. | .. | 1 yr. |
| Coit | 13 | 1 | 1 | .. | .. | .. | .. | .. | 1 | 7 yrs. | Giant-central | .. | .. | .. | 1½ yrs. |
| Loris | 30 | 1 | 1 | .. | .. | .. | .. | .. | 1 | 2 yrs. | Round | 1 yr. | .. | 1 | 8 mos. |
| Sullivan | 29 | .. | .. | .. | 1 | 1 | .. | .. | 1 | .. | Sarcoma | .. | .. | 1 | 2 yrs. |
| Griffin | 51 | 1 | 1 | .. | .. | .. | .. | .. | 1 | .. | Perithelial | .. | .. | .. | 1½ yrs. |
| Donovan | 4 | .. | .. | .. | 1 | 1 | .. | 1 | .. | .. | Round | 3 mos. | .. | (5 mos. after op.) 1 | 3 mos. |
| Brown | 62 | .. | .. | .. | 1 | 1 | .. | .. | 1 | .. | Melanosarcoma | 4 mos. | .. | 1 | 3 mos. |
| Brewer | 35 | 1 | 1 | .. | .. | .. | .. | 1 | .. | .. | Round | .. | .. | 1 | 6 mos. |
| McKerlick | 60 | 1 | 1 | .. | .. | .. | .. | .. | 1 | 4 yrs. | Osteosarcoma | .. | .. | .. | 3 mos. |
| Manchester | 65 | 1 | 1 | .. | .. | .. | .. | .. | 1 | .. | Round | .. | .. | 1 | .. |
| Roy | 16 | .. | .. | .. | 1 | 1 | .. | 1 | .. | .. | Round | .. | 2 yrs. | 1 | 2 yrs. |
| Graham | 56 | .. | .. | .. | 1 | 1 | .. | .. | 1 | .. | Round | .. | 1 yr. | 1 | 3 mos. |
| Frazier | 40 | .. | .. | .. | 1 | 1 | .. | 1 | .. | .. | Perithelial | .. | .. | 1 | 6 mos. |
| White | 2 | 1 | 1 | .. | .. | .. | .. | .. | 1 | .. | Fibrosarcoma | .. | .. | 1 | .. |
| Dalsen | 50 | 1 | .. | 1 | .. | .. | .. | 1 | .. | .. | Round | .. | .. | .. | Embolism in left middle cerebral |
| Barry | 50 | 1 | 1 | .. | .. | .. | .. | .. | 1 | .. | Spindle | .. | .. | 1 | .. |
| Taylor | 47 | 2 | 2 | .. | .. | .. | .. | 2 | .. | .. | Giant | 1 yr. | 2 yrs. | .. | Carcinoma of uterus |
| 26 cases | .. | 18 | 17 | 1 | 9 | 9 | 0 | 12 | 15 | 10 | .. | .. | .. | 11 | .. |

previous to an exploratory incision, whether or not it is worth while attempting the removal of a tumor of the upper jaw. Each case must be decided separately, and the decision, to be a just and safe one, must be based upon a knowledge of all the facts available.

The slowly growing growths which have been present some time are hard and pretty well defined and well localized so far as the jaw is concerned. When the skin and mucous membrane are uninvolved, these growths are very likely to be amenable to surgical treatment. Among these will be found the fibrosarcomata and osteosarcomata.

On the other hand, growths of a few months' duration, which are soft and vascular, rather ill defined, in which the skin is involved, the orbit or temple invaded, with an enlargement of the submaxillary and submental glands, as pointed out by Jackson—such growths are likely to be difficult of removal.

If it is likely that the sarcoma cannot be completely removed, I believe the situation should be stated to the individual and his friends, and operation should be refused. Operation under such circumstances will be of little or no comfort, and is at best distasteful to the individual. Many cases which have been unsuccessfully operated upon are seen by surgeons and internists, and I believe the consensus of opinion is that such patients, taking everything into consideration, would have been fully as comfortable if they had been unoperated upon.

The disease almost always recurs *in situ*, and rather early after operation.

There are a few cases, as pointed out by Butlin, which are benefited by the comparatively long interval between

the removal of the disease and its reappearance. Many operations are doubtless begun and abandoned as hopeless which had much better not have been attempted at all.

**Necessity for Dissection of the Neck in Sarcoma.** If the glands in the neck are palpable, I believe that they should be removed by dissection of the whole side of the neck. In the very malignant operable sarcomata it would

Fig. 96.—Sarcoma of the upper jaw. Note the displacement of the nose, the swelling in front of the ear, the deformity of the mouth (Leipsic clinic).

seem wise to dissect the neck in each case with great care. In none of the sarcoma cases at the Massachusetts General Hospital clinic were the lymphatics of the neck primarily removed. In very few of the sarcomata of the upper maxilla reported from foreign clinics were the neck lymphatics removed. Recurrence takes place locally, and rarely are the glands involved.

**A Case of Inoperable Sarcoma of the Upper Jaw.** T. G., thirty-eight years old. Massachusetts General Hospital record No. 159611. August 5, 1908.

Three years ago the tumor appeared on the right side of the nose. It was removed two years ago. One year ago it had recurred, and has been growing rapidly for the past

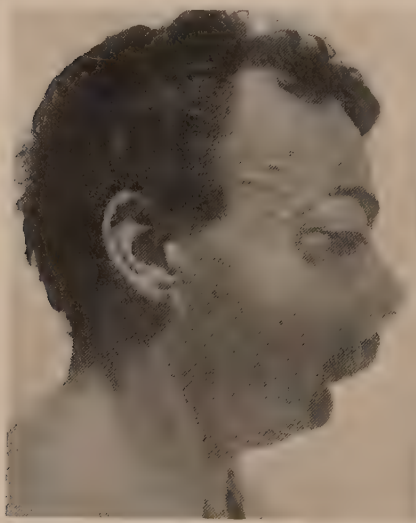

Fig. 97.—Round-cell sarcoma of the upper jaw. Note bulging of cheek and displacement of eyeball. A very vascular and consequently rapidly growing tumor. At this stage of its extension it is inoperable.

Fig. 98.—Round-cell sarcoma of the upper jaw, starting from the antrum and gradually but rapidly invading the nasal cavity, orbit, and cheek. Note growth protruding from right nostril, bulging of cheek, displacement of eyeball, displacement of nose, fullness in inner canthus.

six months. It was treated with Coley toxins without benefit.

Pathologic report: Myxomatous stroma with considerable necrosis and marked overgrowth of blood- and lymph-vessels. Diagnosis: Myxosarcoma.

**When do Recurrences Appear and Where?** –Recurrence appears locally after removal of the sarcoma. Therefore a very radical primary local operation should be done. The recurrence shows itself rather early after operation – that is, within a few weeks, or at most a very few months. This suggests that possibly the trauma of incision is a contributing factor to recurrence.

The lymph-glands were involved three times in Martens' series—once in an alveolar melanotic sarcoma; once in a spindle-cell sarcoma arising in the palate, and once in a round-cell sarcoma.

It may be put down that, as a rule, the lymph-glands are rarely involved in upper jaw sarcomata, whereas in lower jaw sarcomata an enlargement is more common.

*The time of the appearance of the recurrence after operation is of interest.* Stein records four cases of upper jaw sarcoma in which recurrence appeared in two cases one month, in one case one and one-half months, and in one case twelve months, after operation. In two of these four cases death followed six months after operation.

Martens, in his record of König's clinic, finds that 5 patients died one to five months, and three patients six to ten months, after operation on the upper jaw.

Six of the lower jaw cases operated upon died at these different periods after operation—three months, six months, seven months, one year, three and one-quarter years, six years.

In general, it may be said that if recurrence is to take place after an operation for sarcoma of the upper or lower jaws, it will appear within six to twelve months following operation.

**Necessity for Removal of the Eye. Necessity for Removal of the Orbital Plate.**—Butlin thinks that the necessity for the removal of the orbital plate has not yet been fully established. The deformity occasioned by the removal of the orbital plate, together with the more important fact that the eye so deprived of its inferior support is practically thrown out of commission, should lead one to hesitate to remove the orbital plate unless it is absolutely necessary. Of course, if the eye is to be enucleated at the same time in order to get at the disease more readily, then the orbital plate must be removed.



Fig. 99.—Sarcoma of the lower jaw in an elderly person (Massachusetts General Hospital, collection of C. B. Porter).

The tendency of the disease in the antrum, and when extending on to the cheek, is to invade the orbit. When the corner of the orbit next the lacrimal duct is involved, then I believe the eye should be enucleated. I think that it is absolutely impossible to get at the disease and preserve the eye under these conditions.

In Martens' 74 upper jaw operations, 10 times at the primary operation the eye was removed with the growth. Once the eye was removed secondarily for panophthalmitis.

Martens thinks the eye is of less importance than the life of the individual. He believes that the orbital plate is to be removed always with the upper jaw.

OPERATIVE TREATMENT OF UPPER AND LOWER JAW SARCOMATA. RESULTS FROM EUROPEAN CLINICS

| Operator. | Recovered from Operation. | Dead from Recurrence or Living with Recurrence. | Not Found. | After Three Years Free from Recurrence. |
|---|---|---|---|---|
| (*a*) Total Resections | | | | |
| *Upper jaw:* | | | | |
| Billroth, 1871–76 | 9 | 5 | 0 | 4 |
| König, 1875–99 (Martens) | 20 | 13 | 1 | 6 |
| Von Bergmann, 1890–1900 (Stein) | 11 | 4 | 3 | 4 |
| *Lower jaw:* | | | | |
| König, 1875–1902 (Behm) | 8 | 2 | 4 | 2 |
| Total | 48 | 24 | 8 | 16 |
| (*b*) Partial Operations | | | | |
| *Upper jaw:* | | | | |
| König, 1875–99 (Martens) | 2 | 0 | 0 | 2 |
| Von Bergmann, 1890–1900 (Stein) | 5 | 0 | 0 | 5 |
| *Lower jaw:* | | | | |
| König, 1875–1902 (Behm) | 10 | 5 | 2 | 2 |
| Total | 17 | 5 | 2 | 9 |

### (C) SARCOMA OF THE LOWER JAW

The clinical characteristics hitherto mentioned likewise pertain to sarcoma of the lower jaw, excepting for the necessary change in the anatomic relations.

**Kinds of Sarcoma.** –The sarcomata of the lower jaw are usually either subperiosteal or central in origin. The periosteal growths may be of three types of cells –round, spindle, or mixed. The central growths may be of these three types of cells or giant-cells. The giant-cell growths are the most frequent of the sarcomata in the lower jaw.

The progress of the tumors of periosteal origin is usually not by invasion of the bone from without. The bone may be surrounded, but rarely invaded.

**Rate of Growth.**—The sarcoma of the lower jaw is often of very slow growth. The tumor, at first, as in the upper jaw, if palpable there, is smooth on the exposed surface, firm, elastic, and intimately connected with the jaw. Only occasionally is it painful, often painless. It is situated in the body of the jaw, near and in front of the angle. It is of slow growth. The story is one of ulcerated teeth, extraction of certain teeth, a thickening at the place of the extracted teeth, which later becomes the tumor.

Fig. 100.—Sarcoma of upper jaw. Illustrating the very extensive spread of the disease (Massachusetts General Hospital, collection of C. B. Porter).

The mucous membrane, and occasionally the skin over the tumor, will be ulcerated. If the mass becomes very large, it may obstruct swallowing and render breathing difficult by dislocating the tongue.

If the growth be melanotic, and hence very soft and highly vascular, and consequently very malignant, palpation will find a soft, elastic mass, near perhaps to the wisdom-teeth, attached to the jaw, of rapid development. The mass bleeds easily when injured.

So malignant is the malignant sarcoma that a very

early recognition of it is essential to any diminution of the present high percentage of recurrence with death following operation.

**Operative Mortality of Lower Jaw Sarcoma.**—Butlin finds that of 60 cases of lower jaw operations 8 died; Lücke finds that following removal of one-half the lower jaw in 17 cases there were 4 deaths; Heath records 7 cases of Cusack with 1 death; Dupuytren records 20

Fig. 101.—Recurrent sarcoma of the right upper jaw. Note that the recurrence is seen to be local and very extensive (Kaposi, Heidelberg clinic).

cases with 1 death—making a total of 104 cases with 14 deaths, or less than 14 per cent.

St. Bartholomew's Hospital cases from 1887 to 1897 amounted to 10 with 1 death.

In the Massachusetts General Hospital list there have been no deaths due to the operation.

The *common causes of death* in these reported cases were sepsis, hemorrhage, and shock.

Statistics—those of Webber, etc.—derived from the older groups of cases are of value only in a most general way.

**The Ultimate Results of Operation for Sarcoma of the Lower Jaw.**—Butlin has collected 19 cases of subperiosteal sarcoma and 43 cases of central sarcoma. Of the

Fig. 102.—Osteosarcoma of the right half of the lower jaw. Note large size, uniform surface (Duncan Eve).

Fig. 103.—Osteosarcoma of the right half of the lower jaw. After operation by resection (Duncan Eve).

19 cases of subperiosteal sarcoma, there was no death from the operation. Eight were dead or dying of recurrence, and not one was alive twelve months after operation. One died of secondary mediastinal disease four and a half months later. One died of pneumonia after two months. Eight were lost sight of. One was alive and well two and one-half years after operation.

The tumors were nearly all either round- or spindle-cell.

The successful case was that of Mears, of Philadelphia, and was a round-cell sarcoma.

**A Case of Sarcoma of the Lower Jaw, Followed by Carcinoma and Carcinomatous Invasion of the Lymphatic Glands, Occurring in the Massachusetts General Hospital Clinic.**—An unusual and extremely important and instructive case, occurring in the Massachusetts General Hospital clinic, was that of an adult man,

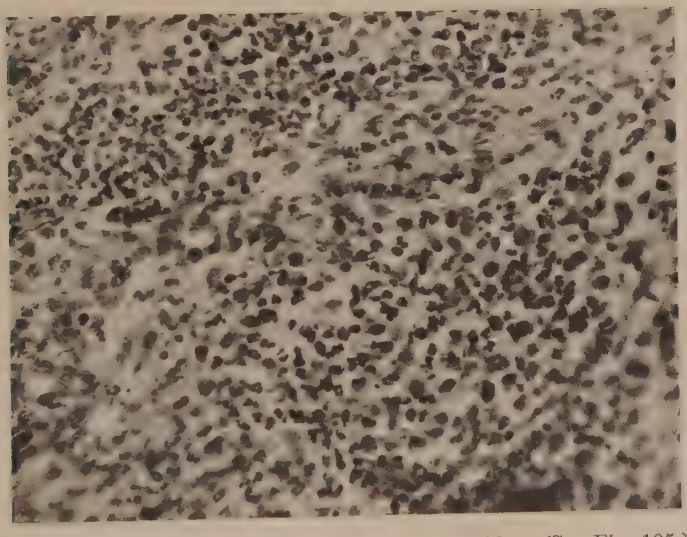

Fig. 104.—Sarcoma of the lower jaw on right side. (See Fig. 105.)

fifty years old. Six years previous to the present observation he had had several lower teeth extracted. Since that time he had a series of gum-boils. Six weeks previous to October, 1905, he first noticed a rapidly growing tumor at the base of the second left lower molar tooth.

Examination of this tumor discovered a mass the size

of a chestnut. There was no glandular enlargement palpable. Microscopic examination of a specimen from this mass proved it to be a *spindle-cell sarcoma.*

In October, 1905, the jaw was operated upon. (See Fig. 104.) A partial excision and curetage was done, together with the removal of the non-palpable submental glands.

In August, 1907, a second operation was done, removing

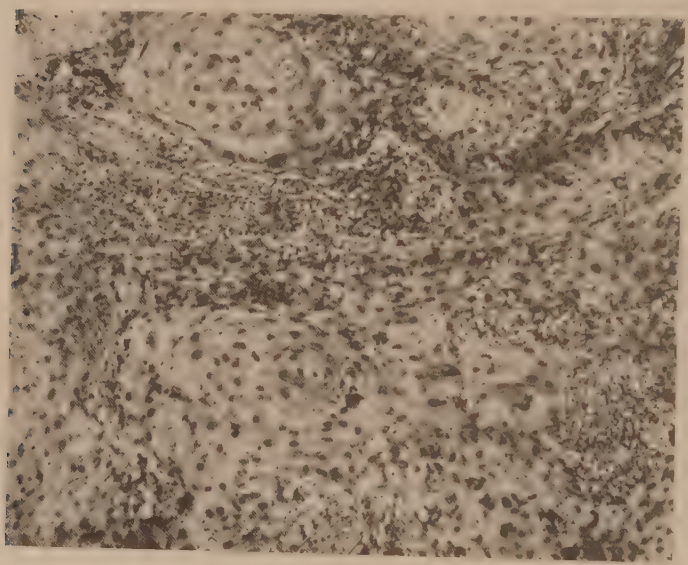

Fig. 105.—Glands of the neck dissected out in case of sarcoma of the jaw shown in previous figure, nearly two years after the jaw operation (Fig. 104). Carcinoma of the glands. These glands naturally were thought clinically to be sarcomatous. They proved to be carcinomatous.

a few enlarged lymphatic glands beneath the jaw. These glands proved to be invaded by *carcinoma.*

In November, 1907, because of an evident recurrence at the site of the October, 1905, operation, a resection of one-half of the lower jaw was done. The neck upon the diseased side was thoroughly dissected, the external carotid being ligated. Seven days later the autopsy disclosed a

septic thrombus of the carotid. The growth from the lower jaw proved to be *carcinoma*.

Summary: An adult with sarcoma of the lower jaw; local excision done. Two years later enlarged glands in the neck and apparently a recurrence at the seat of the original operation. Three months later an excision of one-half of the jaw was done, and the disease found to be

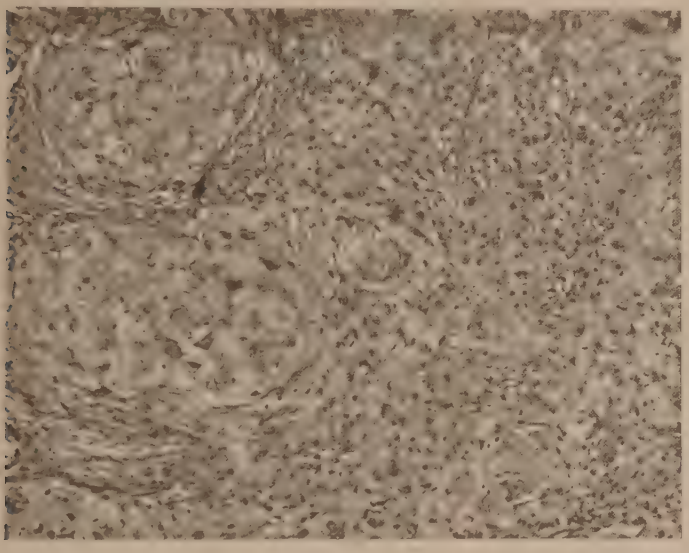

Fig. 106.—Three months after removal of the carcinomatous glands. Reappearance of tumor at site of jaw operation. Proved to be carcinoma. (See Fig. 105.) Patient died of sepsis following jaw operation.

carcinoma. In this case we find illustrated the appearance of two different tumors at the same spot.

A glance at the three microphotographs (Figs. 104, 105, 106) shows the appearance of both the jaw tumor, the glandular recurrence, and the carcinoma ingrafted upon the base of the original sarcoma. These microphotographs were made by Mr. Brown, of the Pathologic Laboratory of the Massachusetts General Hospital, from sec-

tions prepared and reported upon by W. F. Whitney, pathologist to the Massachusetts General Hospital.

Of the 15 lower jaw sarcomata from the Massachusetts General Hospital clinic, the following are the end-results:

1 lived three years; recurrence after two years—spindle-cell.
1 lived six years, then lost sight of—lymphangiosarcoma.
1 lived seven years—osteofibrosarcoma.
1 lived one and one-half years; recurrence in seven months—spindle-cell.
1 living seven years—adamantine epithelioma with sarcoma.
1 living seven years—giant-cell sarcoma.
1 lived two years, recurrence in one year—round-cell.
1 untraced—sarcoma.
1 untraced—perithelioma.
1 recurrence in four months—melanotic sarcoma.
1 living four years—osteosarcoma.
1 untraced—round-cell sarcoma.
1 lived one year, unheard from—round-cell sarcoma.
1 untraced—fibrosarcoma.
1 lived two years, recurrence in one year—died.

None of the 15 died because of operation.

Of these 15 cases of sarcoma of the lower jaw, it has been impossible to find 4 cases. One diagnosis of simply "sarcoma" was made. The predominant variety of cell is not always stated. One was a perithelioma, one was a round-cell sarcoma, and one was a fibrosarcoma.

There have been recurrences in 5 cases:

In 1 case after two years' freedom from disease –a spindle-cell.

In 1 case after seven months—a spindle-cell.

In 1 case after one year—a round-cell.

In 1 case after some months—a spindle-cell.

In 1 case after four months—a melanotic sarcoma.

Fig. 107.—Periosteal osteosarcoma of the lower jaw. Note the uniformly smooth-appearing swelling of the lower left jaw; the swelling extends high, near to the ear, even though the tumor is confined to the body of the left half of the jaw (Bloodgood).

The following six cases have *lived* and *are living* after operation, with no known recurrence:

1 case six years after operation for lymphangiosarcoma.

1 case seven years after operation for osteofibrosarcoma.

1 case seven years after operation for adamantine epithelioma with sarcoma.

1 case seven years after operation for giant-cell sarcoma.
1 case four years after operation for sarcoma.
1 case one year after operation for round-cell sarcoma.

**Duration of the Disease Previous to Operation.**—The disease had existed, so far as could be determined previous to operation in the cases of lower jaw sarcomata from the Massachusetts General Hospital series, one year, some time, six months, three months, four months, one and one-half years, eight months, two years, one and one-half

Fig. 108.—Periosteal osteosarcoma. (See Fig. 107.) Inner view of tumor. A, Bony section of jaw (Bloodgood).

years, three months, three months, three months, respectively.

A spindle-cell sarcoma noticed the growth for one year and lived three years after operation, having a recurrence after two years. A giant-cell noticed the growth one and one-half years previous to operation, and is alive and without recurrence seven years following operation.

Other things being equal, the earlier operation can be done after the growth is discovered, the better is the chance

of cure. But it must be considered that some of the slow growths are most malignant, so that even though a growth be operated upon within a few weeks of its discovery, the result may not be good despite the early operative attack, for it may be a most malignant type. The character of the cell is of more importance than the time of the operation after discovery in suggesting the resulting prognosis.

In the most successful cases the disease had been known to have existed six months, four months, one and one-half years, three months, and three months respectively. The one and one-half year period was in the case of a giant-cell sarcoma.

## Cases of Sarcoma of the Lower Jaw

A detailed account is here presented of certain of the cases studied. Such a narrative makes clearer the clinical picture of the group. Each case described is designated by the name used in the tabulated list.

*Case: Simpson.* A woman, thirty-five years old, had a hard smooth lump of slow growth for over a year upon the right lower jaw. This lump was the size of an English walnut. The gum over the tumor was ulcerated. The tumor was intimately connected with the jaw. Sometimes there was pain in the tumor. A few weeks previous to examination there had been an ulcerated tooth upon the same side of the jaw as the new-growth.

One-half the lower jaw was removed. The growth was a spindle-cell sarcoma surrounding the greater part of the jaw, which was extensively destroyed by it. Two years later a large infiltrating, solid, and painful mass was found at the angle of the jaw, which was thought inoperable. The

patient lived one year after this, or three years from the time of the operation.

*Case: Green.* A man, fifty-five years old, had a tooth extracted from the left lower jaw (bicuspid tooth) nine years previously. He thinks that the jaw was fractured at that time. At any rate, a hard lump appeared in the gum where the tooth had been and grew slowly and pain-

Fig. 109.—Tumor cut open, showing shaft of lower jaw, surrounded by periosteal osteosarcoma (Bloodgood).

lessly. In the mouth and neck (see Figs. 61 and 62) appeared a large mass, ulcerated within the mouth, giving trouble from its weight. Chewing was difficult. The skin over the mass finally ulcerated, allowing blood and serum to discharge.

The tumor was shelled out and half the jaw removed. It proved to a cystic lymphangiosarcoma. It had a soft medullary consistence, with many cysts scattered through it. The man was alive and well six years later.

*Case: Bowles.* A boy, ten years old. Six months ago he was hit with a baseball bat a severe blow upon the lower jaw, knocking him over so that he fell to the ground. Three weeks after the fall there appeared to be a hard, painless swelling upon the lower right jaw, near the angle where the blow had been received. The tumor was 2 inches by ½ inch in size as roughly measured. For three months it grew slowly. The first operation was partial only, as it

Fig. 110.—Sarcoma of the upper jaw in a boy of ten years (foreign clinic).

Fig. 111.—Sarcoma of the upper jaw in a boy of ten years, after operation. Resection of each upper jaw. Note the symmetric cicatrices across both cheeks and slight deformity.

was thought that the swelling was associated with caries; three months afterward one-half the jaw was removed for examination, and the growth found to be an osteosarcoma. This boy was well seven years after the latter operation.

*Case: Turner.* A man forty-five years old had ulcerated teeth for at least three months. The gum of the left lower jaw was greatly swollen. Three weeks ago a tooth

situated within the swollen area was pulled. A hard red ulcerated mass, size of an English walnut, appeared at the socket of the extracted tooth. He had considerable pain in the swelling on the jaw. The pain was severe enough to keep him from his work. The tumor had grown slowly. The glands in the submaxillary region were enlarged.

One half the lower jaw was removed. The growth proved to be a spindle-cell sarcoma. The man lived a year and a half, but recurrence at the seat of the operation appeared seven months thereafter.

*Case: Coit.* A boy, thirteen years old, was kicked hard in the chin while playing football one and one-half years previously. Three weeks after the kick a swelling of the jaw existed, which remained in size pretty constant (a hen's egg). When the boy's chin was examined, there was found (see Figs. 51–56) a mass the size of a hen's egg, extending from the first right molar to the first left bicuspid. A shell of bone covered the growth, which was so soft as almost to give the sense of fluctuation. The mass was purplish in color. Several enlarged superficial veins covered it. The swelling was the same size inside and outside the lower lip.

The lower jaw was cut away, and excised well outside the limits of the growth. The tumor was a giant-cell sarcoma starting from the center of the bone. Seven years after operation the boy is well, with no signs of recurrence.

*Case: Brown.* A man, sixty-two years old, had noticed a swelling of the right lower jaw for about twelve weeks. This swelling had increased rapidly under the use, as then applied, of the Roentgen ray. There appeared about the wisdom tooth a mass which was ulcerated and bled easily. The mass first noted was visible externally at the angle of the jaw, and was intimately attached to the jaw.

The tumor was removed from the lower jaw by a chisel. A few months later a piece of the jaw was removed cor-

responding to the oval mass. This new-growth proved to be a melanotic sarcoma. The case cannot be traced.

### INOPERABLE CASES OF SARCOMA OF THE JAW

The story and progress of the cases of sarcoma of the jaw which the surgeon thinks are inoperable are most interesting.

*Case: Sick.* A young man, thirty-five years old, for ten months had a swelling near to the left tonsil, inside the mouth. This swelling is painless. The left half of the soft palate is thickened and appears gelatinous-like. At one spot on the soft palate over the swollen area there is an ulcer. In the left neck, at the anterior border of the sternocleidomastoid, there is a hard and smooth tumor, 4 inches long, unattached to the skin. The tumor is *deeply adherent.* It is painless. The alveolar border of the lower jaw is enlarged, and this alveolar enlargement is directly continuous with the tumor of the neck.

Microscopic examination of the tumor mass shows it to be a sarcoma; the cells are, for the most part, small.

*Case: McCartney.* A young man, forty-one years old, for six months has had a swelling of the left lower jaw. The tumor is rather hard, non-sensitive, smooth in outline, and extends throughout the entire side of the lower jaw. The swelling of the jaw is continuous with the swelling in the left temporal region. A bit removed from the foul, ulcerating masses projecting from the alveolar border finds the growth to be an angiosarcoma.

The involvement of the temporal region and the well-established general infection precluded the possibility of satisfactory result from operative interference.

*Case: Johnson.* A young man, thirty-three years old, has had for eight years a swelling upon the right side of the

lower jaw. He had his tonsil removed eight months previously. There is a large mass growing from the hard and soft palates, almost occluding the pharyngeal space. A foul, ulcerated surface is present. Talking, chewing, swallowing, and breathing are all difficult. There is an incessant cough.

Tracheotomy was done. A bit of tumor tissue was removed, and a microscopic report by W. F. Whitney finds it to be a round-cell sarcoma. He died about four months after he was seen by a surgeon, who thought the case inoperable.

## CEREBRAL EMBOLISM FOLLOWING LIGATION OF THE EXTERNAL CAROTID ARTERY

**Case of Sarcoma of the Superior Maxilla. Ligation of the External Carotid. Resection of the Superior Maxilla. Death from Cerebral Embolism.**—S. R. D., a woman, fifty years old, married. Hospital No. 143635. Autopsy No. 1441. Massachusetts General Hospital Records.

The patient had been well. The climacteric was established when she was forty years old. For some years she had had a swelling of the soft parts of the face. Five years ago an operation had been done for the removal of this tumor of the left cheek. Two years ago a swelling of the same cheek appeared and had increased gradually in size. She had slight pain in front of the left ear, and at times upon the opposite side of the head. There was a left superior maxillary tumor, hard, firm, and apparently extending from the subcutaneous tissues into the bone. The left antral cavity was dark upon transillumination.

The left external carotid was ligated just below the posterior belly of the digastric before the origin of the facial artery. A complete excision of the upper jaw was then

performed. The operation was done in the sitting posture. On the day following the operation a right-sided hemiplegia became evident. Six days later she died, having been partially unconscious from the day following the operation until her death.

Fig. 112.—Sarcoma of the left upper jaw. Note swelling of the cheek from the tumor within the jaw (see Figs. 113, 114) (Massachusetts General Hospital series).

*Report Upon the Section of the Tumor.*—Microscopic examination showed that the tumor was composed of a solid mass of small round-cells, having very little protoplasm, lying in a fine fibrous stroma. Throughout the section

were large numbers of thin-walled blood-vessels. Diagnosis: Small, round-cell sarcoma. Signed, W. F. Whitney.

*Report of the Autopsy.—Anatomic Diagnosis*: Operation wounds (removal of tumor of the jaw); embolism and thrombosis of the left middle cerebral artery, with infarction involving the basal ganglia; œdema piæ; arteriosclerosis of the aorta; hypertrophy and dilatation of the heart; cholelithiasis; chronic pelvic peritonitis.

Fig. 113.—Under surface of brain.

The body of a woman fifty years of age, 169.5 cm. long, well developed, fat.

Head: On the left side of the face, in the region of the left half of the superior maxilla, there is a wound which extends from the malar bone over toward the nose, then down along the nose to the region of the median line of the upper lip. The wound is closed with sutures.

On section, the pia is infiltrated with a moderate amount of pale fluid. The sinuses are free, and the middle ears are

normal. The brain weighs 1225 gm. On section, the ventricles are free. The internal carotids are free. The vessels leading to the right half of the brain are not remarkable. The vessels leading to the left half of the brain, with the exception of the middle cerebral, are not remarkable. The left middle cerebral, a short distance from its origin, is distinctly occluded by a firm, gray red, thrombus-like mass. (See Fig.

Fig. 114.—Section of brain showing the area of basal ganglia involved.

113.) In some of the first branches of the middle cerebral the thrombus mass is apparently prolonged as a black-red, somewhat softer material. In the situation of the basal ganglia on the left there is a pale, in places grayish-red, disorganized, more or less disintegrated soft mass of brain tissue, which extends from the posterior portion of the left frontal lobe back as far as the posterior portion of the left

thalamus and including a portion of the thalamus laterally and to the left, and involving a good half of the striate body and extending downward into the temporal lobe. (See Fig. 114.) The condition extends into the left temporal lobe over quite an area, and reaches as far as the cortical portion. In this situation the brain tissue is pale, disintegrated, and mushy. The brain tissue elsewhere is not remarkable. There is no evidence of arteriosclerosis in the vessels of Willis.

Bacteriologic report: Cultures in blood-serum. Heart: No growth. Liver: No growth. Spleen: No growth.

(Signed) Oscar Richardson, M.D.,
Pathologic Laboratory,
Massachusetts General Hospital.

The facts of especial interest in this case are that, whereas the preliminary ligation of the external carotid was attended with no difficulty at the time, was quickly accomplished, and perhaps prevented undue hemorrhage while excising the jaw, yet subsequently a clot became dislodged and was carried by the internal carotid into one of the cerebral arteries, causing signs of partial unconsciousness and hemiplegia upon the opposite side, and death.

Figs. 113 and 114 illustrate well the extent and the gross appearances of the lesion. This deplorable outcome is to be considered as possible in the ligation of the external carotid, although it is comparatively rare. Matas has recorded in his wide experience 3 deaths from cerebral embolism following 68 ligations of the external carotid.

**A Case of Fibrosarcoma of the Upper Jaw.**—Massachusetts General Hospital series, vol. cccli, p. 208. A man, forty years old. He had noticed a small swelling

for about seven months in the region of the first and second molar teeth of the upper jaw. This mass had been removed

Fig. 115.—Fibrosarcoma of the right upper jaw. Complete resection of right upper jaw. In A note line of left edge of palate in roof of mouth. In B note deformity, with prosthetic apparatus *in situ*. Note slight sinking in and lowering of the right orbital contents. In C note prosthetic appliance used in this case (Massachusetts General Hospital series).

and had recurred. In 1899, when he presented himself for operation, there appeared in the roof of the mouth, on the right side, a ragged, ulcerating growth extending along the

alveolar process and involving it. A partial operation was done, and the bone beneath the tumor was removed. Later, in 1900, a resection of the upper jaw was done.

Microscopic examination proved the growth to be a fibrosarcoma.

Eight years subsequently to this operation the man is free from local disease and in good health. As is seen by the photograph, he is wearing a prosthetic appliance.

### (D) THE TREATMENT OF SARCOMA OF THE JAWS

A proper consideration of the treatment of sarcoma of the jaws must take into account the kind of cell involved in the growth, the local extent of the diseased process, the exact seat of the disease, and the age of the patient.

The exact surgical procedure will be either a *limited operation* (inappropriately called a "partial operation"), or an *extensive operation.* Obviously, one should avoid mutilation of the patient, and yet operate so extensively as to eradicate the sarcoma; and not only should the sarcoma be eradicated without mutilating the individual, but this should be accomplished with the lowest possible death-rate.

With regard to the kind of cell found in the sarcoma: If the tumor is a *giant-cell sarcoma,* it may occur centrally in the bone or more peripherally. It has been established that the giant-cell sarcoma is one of the least malignant types of sarcoma (König). Consequently a very extensive operation is not necessarily indicated.

If the *giant-cell sarcoma* is seated *in the lower jaw,* it may be possible, if some of the bone still remains intact along the body, to curet and remove all the growth. Blood-good and others have advocated this procedure, and cases are reported which make it seem safe.

If, on the other hand, the bone is so involved that it is impossible to leave a sufficiently strong supporting bony bridge after curetage, it will be wise to resect the maxilla in continuity. In the case of the giant-cell sarcoma, it will be unnecessary to place the lines of resection a long distance from the margin of the growth, because the likelihood of recurrence is slight.

If the *giant-cell sarcoma* involves *the upper jaw*, and, as it sometimes does, fills the antrum and bulges the cheek, it may be possible to remove the disease by a partial operation. I am inclined to think, however, that a complete resection of the upper jaw under these conditions will be safest. The possible extensions of the growth in this situation are so many that a complete removal by curetage alone is almost a physical impossibility. In fact, I believe that any malignant growth, whether sarcoma or carcinoma, involving and filling the antrum, is best treated by excision of the entire upper jaw. The removal of the bony box of the upper jaw uncovers the deeper parts into which the malignant growth may have penetrated.

If the growth is a *periosteal sarcoma* and is a mixed tumor, containing either cartilage, connective tissue, bone, or myxomatous tissue, we have to deal with a relatively benign growth. It must be remembered, however, that the sarcomatous element present suggests the possibility of a recurrence of the growth locally. Moreover, we must not lose sight of the fact that if a local recurrence takes place, the recurrence is liable to be more malignant in its character than was the original tumor.

If the growth consists of *spindle- or round-cells*, we have to deal with one of the most malignant of the sarcomata.

Under these circumstances a most radical and extensive removal of the local growth must be attempted. If the malignant disease occurs *in the antrum,* a complete resection of the upper jaw should be made, the lines of section passing through undoubted sound tissue. All parts adjacent to the diseased area should be scrutinized carefully in order to detect any bits of remaining disease. I believe that the actual cautery should be applied to the line of incision in the deep parts, so as to preclude the possibility of any cells remaining undestroyed.

If the disease is of the *lower jaw,* a complete resection wide of the disease is necessary. Any glandular enlargements present in sarcoma of either the lower or upper jaw should be removed. In the absence of enlarged glands in the least malignant forms of sarcoma a systematic removal of the lymphatics is not necessary. I believe that in the malignant types of sarcoma, especially in the spindle- and round-cell sarcomata, a systematic dissection of the neck usually on both sides is wise.

Perthes is governed as to the degree of operative removal by the position and the extent of the growth, rather than by its histologic characteristics. I believe that both the histologic characteristics and the extent of the disease are to be considered in determining whether a limited operation or an extensive operation is to be done.

If the disease is of the less malignant type and is seated in the nasal cavity, a limited operation through an osteoplastic flap may be possible. If the disease is of the less malignant type and involves the alveolar process, the limited operation may be done, particularly if the disease is in the upper jaw.

In general, one may say, after limited operations, recurrences have occurred in all types of sarcoma. These cases might have avoided a recurrence had a primary extensive operation been done.

König limits a partial operation to the upper jaw. Martens holds that, in dealing with malignant disease of the upper jaw, it is not difficult to cut into sound tissue, and one should do a total resection, except in cases of giant-cell sarcoma, where a partial operation is indicated.

Perthes would do a limited operation if the sarcoma were quite localized upon the alveolar process or were of the hard palate. In all other cases he would do a total resection. Likewise, if limited to the alveolar process of the lower jaw, Perthes would do a limited operation.

There are certain cases of the malignant sarcomata in which the extent of the disease is so great that the very extensiveness of the tumor precludes the possibility of cure. One must recognize that these inoperable cases exist, and not attempt, as too often is done, an extensive removal of what experience has proved to be irremovable. Such unwarranted operations as these throw a shadow upon surgery. I have seen a round-cell sarcoma of the upper jaw which has existed for some time, and which has filled the antrum, the nose, the orbit, ulcerated the cheek and the roof of the mouth I have seen an attempt made to remove such a growth when it was obvious that operative interference was contraindicated. Great harm is done by such meddlesome surgery. There is no justification for such surgery in the statement that the patient requested that the operation should be done.

# CHAPTER III

## BENIGN TUMORS OF THE JAWS

CONTENTS OF CHAPTER: Fibroma: Origin of fibroma.—Age of occurrence.—Varieties of fibroma: Periosteal; Central.—Etiology.—Symptoms.—Diagnosis.—Treatment.—Chondroma of the jaw: General observations.—Treatment.—The Myxoma.—Lipoma.—Osteoma of the jaws: General observations; Osteoma of the upper jaw; Osteoma of the antrum of Highmore; Hyperplasia of superior maxilla: Treatment; Osteoma of the lower jaw; Osteoma of the sinuses and the orbit.

### FIBROMA OF THE JAW

THE fibroma occurs alike in the upper and lower jaw. The **origin of the fibroma** is somewhat doubtful. Virchow thought that the fibroma originated from the marrow or from the bone itself. Nimmier and Blauel think that the fibroma arises from the connective tissue of the periosteum or periodontium or from the connective tissue of the blood-vessels.

Fig. 116.—Fibroma of the upper jaw. Man, twenty years old. Observed first ten years ago. Two operations performed. Remained cured as long as under observation—two years (Senn).

The fibroma is made up of dense, hard fibrous tissue, lobulated and knobbed. On section, there may be seen long and short chains of granular material, in irregular masses, constituting a calcification of the fibroma.

Blauel records a case—the only one on record—of fibroma which in one portion presents wide lymph-channels and resembles a giant-cell tumor.

**Age of Occurrence.**—Clinically, these tumors are benign. They appear in middle life, most commonly during the third decade. They have been seen during the second and fourth decade. (See Fig. 116.) Heath and Piscacek report a case occurring in a new-born child. Perthes has seen a case of symmetric tumor upon both upper jaws, and a case symmetric upon both sides of the lower jaw. Kritz records a case of symmetric fibroma of the upper and lower jaws.



Fig. 117.—Central fibroma of the under jaw (Bauchet, Perthes).

These tumors may attain great size.

**Varieties of Fibroma.**—They may be divided into periosteal and central fibromata. *The periosteal fibroma* arises from the periosteum of the jaw, over the alveolar process, from the periodontium lining the tooth-socket,

and from the periosteal covering of the antrum of Highmore. Those cases arising from the margin of the alveolar



Fig. 118.—Fibroma of the upper jaw in a woman twenty-one years old. Duration of growth, four years. Successful removal by Mr. Liston. Note the appearance of the face before and after the removal of the growth. The tumor might, from its external appearance, be growing from the lower jaw, instead of from the upper jaw (after C. Heath).

process are similar to the fibrous epulis. The fibroma in this situation is a non-vascular epulis.

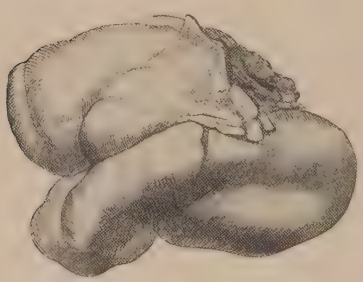

Fig. 119.—Fibroma of the upper jaw removed from patient shown in Fig. 118 (after C. Heath).

The *central fibroma* occurs most often in the lower jaw. Several cases have been reported by Schulz, Küster, and Zuckerkandl in the upper jaw.

In the lower jaw, fibroma occurs most often in the middle of the horizontal ramus. The tumor is surrounded by a shell of bone which is a new

formation of bone entirely independent of the jaw bone itself. The central fibroma may be found free or loose in a fibrous capsule made up of several laminæ. In the lower jaw the tumor bulges upon the outer side.

The central fibroma of the upper jaw appears to start in the antrum of Highmore.



Fig. 120.—Fibroma of the jaw of enormous size, removed successfully by Mr. Liston from a woman forty years old. The tumor had existed for six years before it was removed (after C. Heath).

The **etiology** is unknown. Broca and Blauel think the fibromata arise from displaced tooth-buds. Perthes thinks that the absence of enamel and epithelial elements, which are always characteristic of the odontomata, lends weight to the view that these central fibromata are not derived from the tooth-germ.

Heath suggests that trauma may be an etiologic factor.

Bordenaave believes that irritation of the roots of decayed teeth may contribute to the starting of a fibroma.

They are of very slow growth. Rigaud notes one growing twelve years. Bauchet's case grew fifteen years. Menzel's case grew twenty-five years.

They may reach enormous size. (See Figs. 117 and 120.)

Fig. 121.—Front of the base of the skull of a patient with a large fibroma of the left side of the lower jaw. Note the pressure results upon the upper jaw, and the natural growing molar and zygoma laterally. The patient died from an infection of the growth after setons and incisions had been employed (after C. Heath).

The progress of these tumors may be characterized by periods of slow and then by times of rapid growth.

The **symptoms** are those due to pressure of the growth. In the upper jaw pressure on the infra-orbital nerve may cause pain. The symptoms from a central fibroma of the lower jaw will be those suggesting a benign slow growth, causing a gradual symmetric enlargement of the jaw on its outer side.

These tumors are benign. They never cause metastases. There is no infiltration nor ulceration associated with them.

Heath records a case in which suppuration occurred because of puncture of a fibroma for diagnostic purposes.

The *x*-ray will help in a **diagnosis** from growths likely to be mistaken for it. If the bony shell becomes thinned, then one may obtain a parchment-like crepitus which may be helpful in diagnosis and at times confusing.

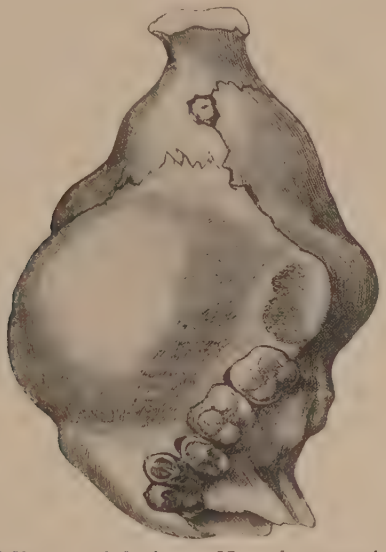

Fig. 122.—A central fibroma of the jaw. Note the expansion of the jaw by the growth (University College Museum, London, after C. Heath).

**Treatment** should be the removal of the growth, with the preservation of all the bony support possible for the jaw. A ridge should be preserved running the whole length of the jaw. Blauel, Heath, and Perthes insist upon keeping intact the inferior maxillary ridge of bone, not only as a basis for the permanent teeth to be fitted later, but for the maintenance of a symmetric chin and face.

Before a radical removal of anatomic structures it will be wise to be positive as to the diagnosis. The removal of a bit of tumor tissue for examination will be helpful.

## CHONDROMA

The chondromata are rather rare growths. Their origin is obscure. Schmidt thinks that they may come from cartilage rests—bits of preformed cartilage.

Fig. 123.—Osteofibrochondroma. A man forty-four years of age. Duration of growth, five years. Weight of tumor, 3½ pounds (Hingston).

Berjor's classification of the chondromata is the best. He arranges them in two groups—the benign and the malignant chondromata.

The benign chondroma is composed of pure hyaline cartilage, sometimes mixed with a little connective tissue—that is, a fibrochondroma.

The malignant chondroma is a mixed tumor containing not only cartilage tissue, but sarcomatous elements, and possible bony elements, *i. e.*, a chondrosarcoma and an osteochondrosarcoma.

These tumors do not infiltrate the surrounding parts—they destroy by pressure atrophy. They are contained within a capsule of either bone or connective tissue.

The chondroma appears in early life, usually under twenty-five years, although it may occur at any age.

Fig. 124.—Osteofibrochondroma. Lateral view of same case as Fig. 123. Removed by operation successfully (Hingston).

The chondromata arise from both the upper and lower jaws. The starting-point of these tumors is most frequently from the alveolar margin; next, from the bones of the face near the orbit, vault, and from the palatine or orbital plates of the superior maxilla.

When arising from the lower jaw, the chondroma begins in the body of the bone centrally or peripherally. It may come from the articular process, the articular cartilage, or the coronoid process.

The growth is slow. Cases have been recorded in which sixteen, twenty-five, and thirty years have been the period of growth.

The tumor grows faster if of the osteoid type or of the mixed type of chondrosarcoma. The size attained by these tumors may be very great.



Fig. 125.—Same case as Figs. 123 and 124. Lateral view after operation for removal of osteofibrochondroma and after plastic operation (Hingston).

A calcification of the chondroma may occur, and Heath has recorded several instances of this change.

The jaw may be involved secondarily from pressure of a growth starting in a part near the jaw, as when it starts from the orbit.

Fig. 126.—Craniofacial enchondroma. Represents the appearance of the patient full face. The patient died during the operation, because of some respiratory difficulty (copied from a photograph by H. G. Wright. Recorded by Moore. Trans. Path. Soc., vol. xix, p. 332).

Fig. 127.—Craniofacial enchondroma. Represents the appearance of the patient profile view. Same case as Fig. 126.

Fig. 128.—Enchondroma of right orbit, recurrent. Shows the appearance of the patient at the time of his admission into the hospital. He died of pyemia six weeks after the operation, done in 1868 (Christopher Heath).

The symptoms are those of pressure. There is rarely ulceration of the soft parts. The lymphatics are not enlarged. The distressing deformity is sometimes terrible. Recurrence of the growth occurs a long time after operative removal in certain cases. The succeeding recurrences become increasingly malignant. Heath records such a case. Lawson operated in one case ten times in eighteen years—the last recurrence was a spindle-cell sarcoma.

**A Case of Chondroma of the Upper Jaw. Age Fifty-one.** (See Fig. 129.) Depressed fracture of the

Fig. 129.—Enchondroma of the upper jaw. Man, fifty-one years old. Removed by successive operations. Recurred (Massachusetts General Hospital series. Patient of C. B. Porter).

nose at four years. At eighteen years severe ulceration of the superior maxillary bones near the insertion of two central incisor teeth, followed by necrosis. Seven years ago he had "congestion of the gums," with swelling of the lips, lasting four years, when a tumor appeared.

First operation: Excision of anterior portion of both superior maxillæ.

Second operation: Six months later. Tracheotomy. Pharynx packed with gauze. The nasal septum with lower wall of left orbit removed.

He died later of a lingering recurrence.

**Treatment.**—Complete operative removal is necessary. Sound tissue must necessarily be sectioned in its removal. The complete removal of the upper jaw will be necessary in almost all cases.



Fig. 130.—Osteochondroma of the upper jaw (Thompson, Army Medica Museum, Washington).

A partial excision will be wise only when there is a distinct localization of the tumor, and particularly if it is in the alveolar process. I agree with Perthes in this particular.

### THE MYXOMA

The pure myxoma is rare. A few cases have been recorded. Myxosarcoma is a more common form than the pure myxoma.

The relatively flatter tumor, of softer consistence and of more rapid growth, is suggestive of the myxoma.

The myxomatous element indicates the necessity for a more radical operation—possibly for a complete rather than a partial operation.

### LIPOMA

There are, according to the note of Perthes, but three cases of lipoma of the jaw recorded.

Fig. 131.—Osteochondroma of the upper jaw (same case as Fig. 130).

### OSTEOMA

Bony tumor may arise from preformed bone, cartilage, connective tissue, or from the periosteum. Cartilage has been found in an exostosis of the lower jaw.

The majority of cases appear in individuals before the twentieth year. A certain number of cases are bilateral, appearing in one jaw (upper or lower) upon each side symmetrically. Symmetry suggests a congenital origin from rests of cartilage.

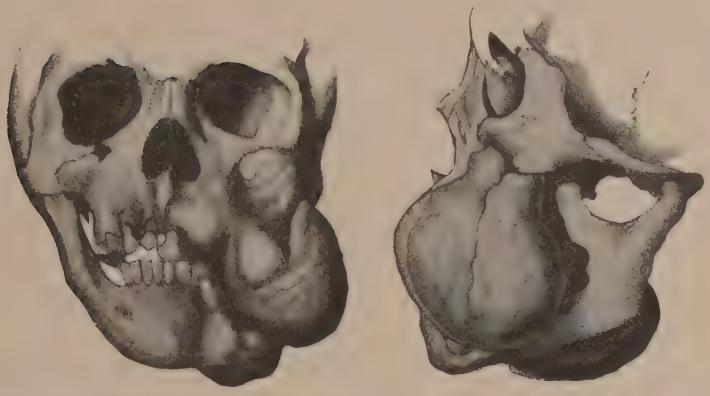

Fig. 132.—Osteoma of the upper jaw. Note seat of origin (Vidal, Heath).

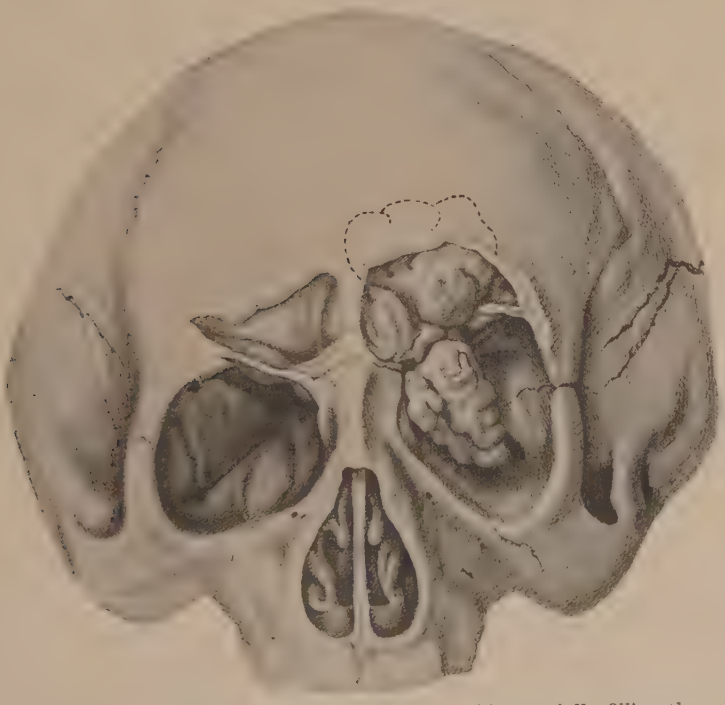

Fig. 133.—Osteoma of the inner side of the orbit, partially filling the orbit and encroaching upon the cranial cavity, as indicated by the dotted lines (Arch. f. klin. Chir., vol. xxvi).

Fig. 134.—Osteoma of the left orbit. Removed successfully. Man twenty-three years of age. Typhoid fever four years previously. Haziness of vision in left eye. No diplopia present. Some pain in the left forehead (Deut. Zeit. f. Chir., Bd. lxxvii).

Fig. 135.—Osteoma of the left orbital space. (See Fig. 134.) *X*-ray shows the solid bony tumor. Arrow points to tumor. *a*, Frontal sinus; *b*, incisor teeth; *c*, sella turcica.

Fig. 136.—Osteofibroma of the left lower jaw (Menzel, Perthes).

Fig. 137.—Osteoma of the lower jaw. A section through the tumor (Heidelberg Pathologic Institute).

The structure is either that of a spongy bone or of a sclerotic, hard bone.

**Osteoma of the Upper Jaw.**—It will be attached by a narrow or a broad base. It often appears in the anterior wall of the antrum, above the canine fossa. The deformity

Fig. 138.—Exostosis osteoma of the articular process of the lower jaw (Eckert, Bruns, Perthes).

and the interference with the mouth and movements of the jaw are the sole signs. (See Fig. 132.)

**Osteoma of the Antrum of Highmore.**—It is a rare tumor. It may be pedunculated or free in the antrum. The tumor may break through to the orbit, antrum, or

Fig. 139.—Osteoma of the lower jaw of an old woman (Volkmann, Perthes).

Fig. 140.—Lower jaw of an adult. A rounded, pedunculated osteoma arising from the body of the jaw, beneath the canine and bicuspid teeth, which are intact (Warren Museum, No. 1461).

cranial cavity. The etiology is uncertain. Infection may occur from the nose.

Cases of localized *hyperplasia of the superior maxilla* have been described and reported by Westmacott and



Fig. 141.—Bony enlargement, osteoma of alveolar process of jaw in a woman thirty-three years old (Warren Museum, No. 4836).

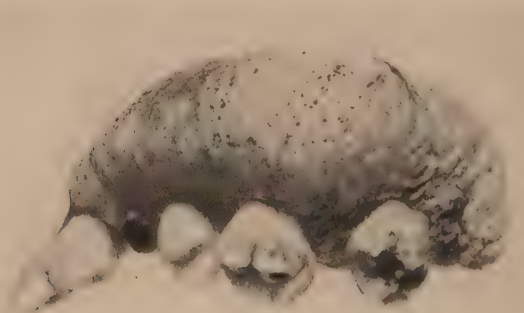

Fig. 142.—Bony enlargement of alveolar process of jaw. Duration, six or seven years. Never any pain. Mucous membrane unbroken (Bigelow, Warren Museum, No. 4836).

Southam, Manchester, England. (See Figs. 143–147 inclusive.)

This hyperplasia of the superior maxilla is very much

like a hyperostosis. It may be associated with carious teeth. It affects both sides of the alveolar arch. It progresses

Fig. 143.—The alveolus of a normal jaw, for comparison with the accompanying plates (see Figs. 144, 145, and 146) (Westmacott).



Fig. 144.—Superior surface of maxilla excised, showing the antral cavity filled with cancellous bone (Westmacott).

Fig. 145.—The alveolar process of an upper jaw of a girl of nineteen years who had received a blow upon the jaw nine years previously. The entire upper jaw excepting the orbital portion was excised for pain and disfigurement. There has been no recurrence (Westmacott).



Fig. 146.—A cast of the alveolar process of the upper jaw of a girl of nineteen years who had had pain in the posterior teeth of this jaw in the region of the tumor indicated in the figure. The tumor tissue was removed, and proved to be vascular bone of rather soft consistence (Westmacott).

toward the outer wall of the superior maxilla. The deformity and the neuralgic pain lead the patient with this disease to consult the dentist or physician.

The *x*-ray will assist in the diagnosis.

A partial operation may be all that is necessary. The removal of the shell of bone over the tumor, with its enucleation, may be the best procedure.

**Osteoma of the Lower Jaw.**—Almost any part of the lower jaw may be the seat of an osteoma.

**Osteoma of the Sinuses and the Orbit.**—The ivory-like osteomata sometimes originate in the sinuses of the

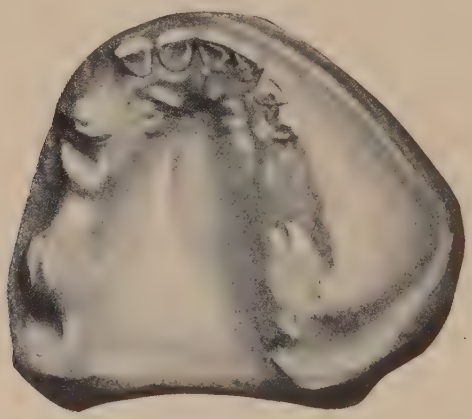

Fig. 147.—A cast of the alveolus of an upper jaw of a woman of thirty years. The enlargement progressed for four years. Carious teeth existed, and occasional pain was felt (Westmacott).

nose and frontal and sphenoid cells, or in the orbit itself. (See Figs. 133 and 134.) These orbital or sinus osteomata progress slowly. They cause symptoms because of their slow but irresistible progress.

Borhaupt has described the collected cases of orbital osteomata—some 57 altogether.

These tumors probably arise from the wall of the orbit or from some sinus of the nose, and are most often circum-

scribed, surrounded by a fibrous or bony capsule, although they may be without encapsulation.

There are about 49 cases of encapsulated orbital osteomata recorded:

23 cases originated from the frontal sinus.

11 cases originated from the ethmoid cells.

10 cases originated from the antrum of Highmore.

5 cases originated from the sphenoid cells.

# CHAPTER IV

## THE ODONTOMATA

CONTENTS OF CHAPTER: Definition.—Classification.—Normal development of the teeth.—The development of the hair—analogy.—Normal adult tooth. —Epithelial cord.—The papilla.—The enamel organ.—The follicle.—The jaw and the tooth.—Epithelial rests.—Paradental epithelial débris.—Adamantine epithelioma: Origin; Clinical course; Synonyms; Age of appearance; Sex relationship; Jaw involved; Progress of the growth; Size; Rate of growth; Relation to the jaw itself; Character of mucous membrane; Lymphatic glands; Tabulated characteristics of the adamantine epithelial tumor; Relation to dentigerous cyst; Differentiation from an epulis; Differentiation from a dentigerous cyst; Differentiation from a carcinoma; Differentiation from a sarcoma; Pathology of adamantine epithelial tumor; Gross pathology; Microscopic pathology; Treatment; Prognosis.—Cysts of the jaw: Dentigerous cysts; Origin; Growth; Upper jaw; Etiology; Pathology; Walls of cyst; Contents of cyst; Multilocular cysts: Diagnosis; Treatment; Compound follicular odontomata; Dental cysts; Root-cysts; Symptoms; Differential diagnosis; Treatment; The hard odontoma.

### THE DEVELOPMENT OF THE TEETH

**Definition.**—An odontoma is a tumor of the jaw arising from a portion of a tooth's follicle. The particular histologic characteristics of the tumor are determined by the stage of development of those cells of the follicle from which the tumor originates. The follicle is the whole tooth-germ.

Many **classifications** of the odontomata have been made. The most satisfactory is that of Bland-Sutton, on an embryologic basis. All the varieties there included are too numerous for the convenience of the surgeon. Several of the tumors in Bland-Sutton's list occur so infrequently that, for practical purposes, they may be omitted.

The following varieties of odontomata are of surgical importance:

1. The dental root-cyst.
2. The follicular or dentigerous cyst.
3. The compound or composite follicular cyst.
4. The adamantine epithelioma.
5. The hard odontoma.

## THE NORMAL DEVELOPMENT OF THE TEETH

In order to have an understanding of the nature of the odontomata it is necessary to have a very accurate knowledge of the normal development of the teeth.

Fig. 148.—Section of jaw of rabbit embryo, showing dental ridge cut across: *ec*, Oral epithelium; *e*, epithelial outgrowth corresponding to future enamel organ; *m*, mesoblastic tissue (Marshall's "Operative Dentistry").

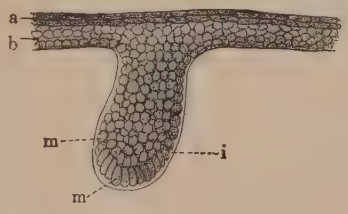


Fig. 149.—First rudiments of a hair from the human embryo of sixteen weeks: a, b, layers of cuticle; m, m, cells of the rudimentary hair; i, hyaline envelop (Marshall's "Operative Dentistry").

In the development of the teeth there is an analogy to the development of the hair. The first signs of both hair and teeth are seen in the changes occurring in the lower or malpighian epithelial layer. The deeper cells of the malpighian layer grow into the tissue beneath. In the case of the teeth the malpighian cells crossing the rudimentary alveolar processes dip into the mesoderm. The part of the malpighian layer dipping into the mesoderm is called the epithelial cord or bud. (See Figs. 148, 149, and 150.)

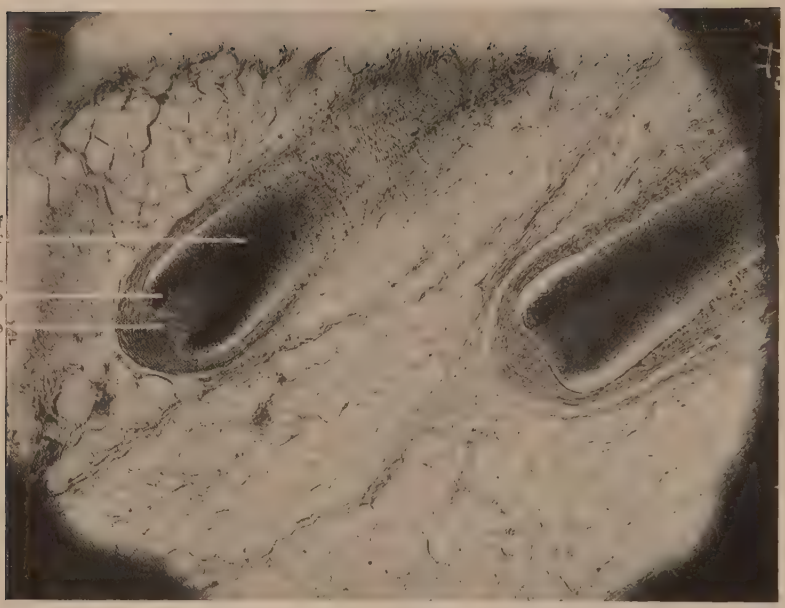


Fig. 150.—Vertical section of the skin, showing bulbous ends of two hairs (× 55) (Marshall's "Operative Dentistry").

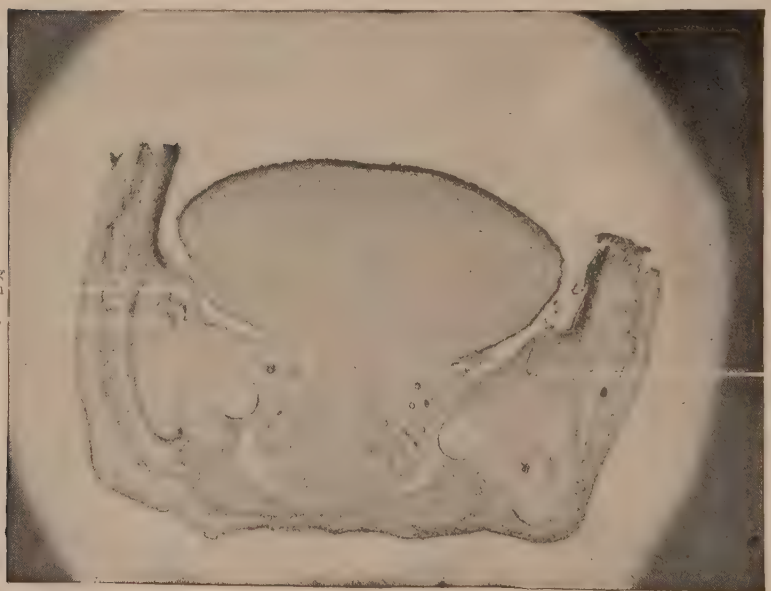


Fig. 151.—Lower jaw of human embryo, ninth to tenth week (× 80) (Marshall's "Operative Dentistry").

The *likeness in the development of the tooth and hair* may be still further seen in the formation of the papilla and the invagination, by the growing into it of the flask-shaped epithelial malpighian cord. (See Fig. 150.)

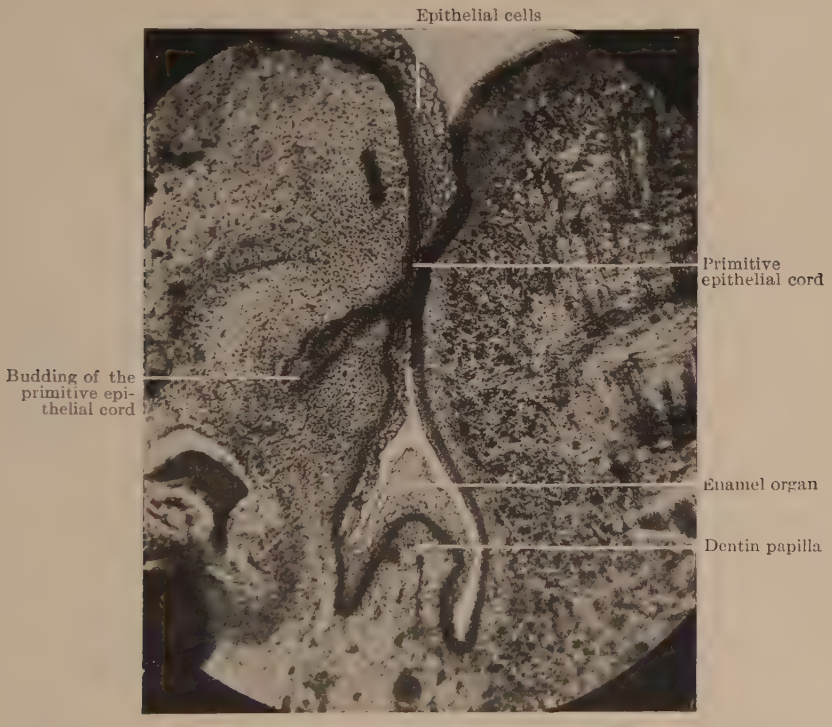


Fig. 152.—Vertical section of cuspid of human fetus, showing the budding of the primitive epithelial cord (× 70) (Marshall's "Operative Dentistry").

The *epithelial cord* (see Figs. 152 and 153) sends off a bud or process called the epithelial lamina. The epithelial lamina occupies a horizontal position to the epithelial cord in the lingual side of the jaw. It is from this lamina or lateral process that the *permanent* teeth are derived.

A section of the *normal adult tooth* (see Fig. 154) shows well the various completed portions of the tooth structure.

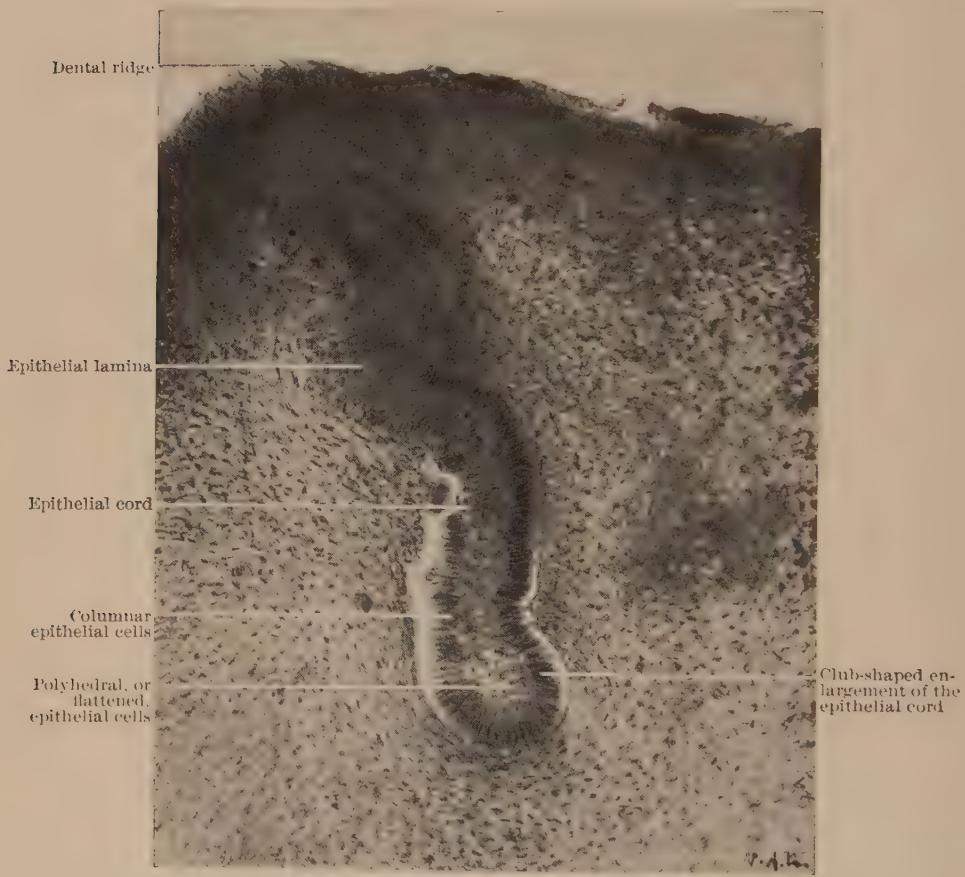


Fig. 153.—Vertical section of epithelial cord, or primitive enamel organ (× 300) (Marshall's "Operative Dentistry").

It is important to be mindful of the enamel, the dentin, the pulp chamber, and the cement.

The *epithelial cord* in its growth dips deeper and deeper into the cells of the rudimentary jaw, and forms the primi-

tive enamel organ (see Fig. 155) of the tooth. The enamel organ enlarges and becomes more club-shaped.

The *papilla* grows into and invaginates the enamel organ opposite it by the increase of its mesoblastic cells. (See Fig. 155.)

There is an *enamel organ* for each tooth. There is a papilla opposite to and corresponding to each enamel organ.

Fig. 154.—Showing structures of a tooth: 1, Enamel; 2, cementum; 3, dentin; 4, pulp-chamber (Marshall's "Operative Dentistry").

The enamel organ, derived from the ectoderm, epithelial in character, determines the form of the future tooth. (See Fig. 156.) The papilla, derived from the mesoderm, connective tissue in character, fills out the form of the tooth determined by the enamel organ. The papilla produces the future dentin, cement, and tooth-pulp. (See Figs. 155 and 156.)

The sac of the tooth forms from the connective-tissue cells about, and completely surrounds, the papilla and the enamel organ. (See Figs. 155, 156 and 157.) The enamel

Fig. 155.—Evolution of dental follicle at about the ninth week, showing invagination of enamel organ (× 70) (Marshall's "Operative Dentistry").

organ, the dentin papilla, and the sac altogether form the *tooth-follicle.*

The enamel organ, proceeding downward over the upward growing papilla, soon completely surrounds the papilla

as if by a hood. The hood of the enamel organ has a double wall.

Fig. 156 shows beautifully the follicle completed, the epithelial cord separated, and the two sets of teeth, temporary and permanent, in the jaw.

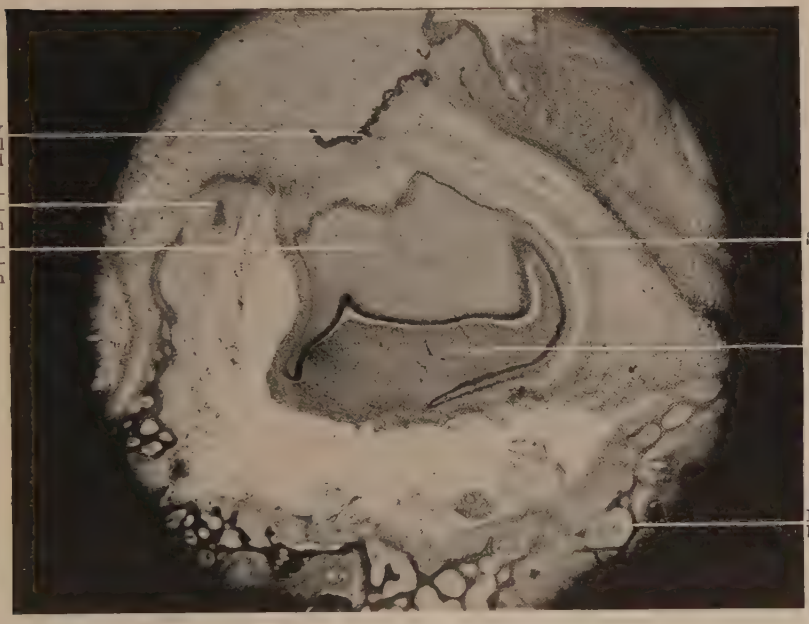


Fig. 156.—Section of human developing tooth, showing the follicle closed and the primary epithelial cord severed from its enamel organ (Marshall's "Operative Dentistry").

This hood or double-wall enamel membrane has, therefore, an inner and an outer layer. The inner enamel-cells are tall and cylindric (ameloblastic layer); the outer enamel-cells are flat and cubical. (See Figs. 160 and 161.)

The space between the two membranes or walls of the enamel hood is filled with a meshy, cellular enamel pulp or stellate reticulum. (See Figs. 160 and 161.)

Just beyond the ameloblastic cylindric cells is an intermediate layer—the stratum intermedium. (See Fig. 159.)

Fig. 158 shows beautifully in the higher power the cells of the several layers of the developing follicle.

**The Jaw and the Tooth.**—There is often a haze of misapprehension concerning the exact structure of a part

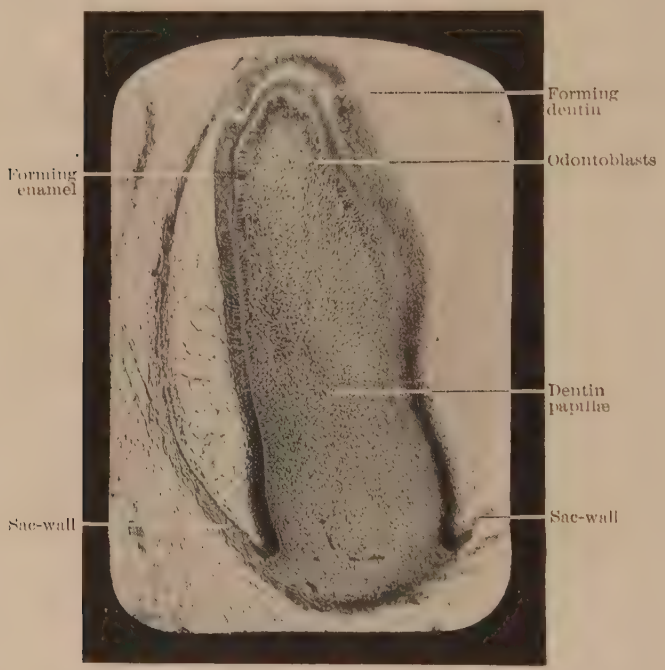


Fig. 157.—Developing human cuspid (Marshall's "Operative Dentistry").

where two somewhat different tissues unite. The tooth-socket and the alveolar border are two such regions. Fig. 163 shows well the normal relation between the bony wall of the tooth-socket and the contained tooth-root. The alveolar border and its relations to the gum and the tooth are well shown in Fig. 162.

The alveolo-dental periosteum is a fibrous, connective-tissue structure which covers the root of the tooth and the walls of the alveoli or tooth-sockets, and is continuous with the periosteum of the alveolar border. (See Fig. 162.) It is from this tissue that the ordinary form of epulis arises. (See Chapter I.)

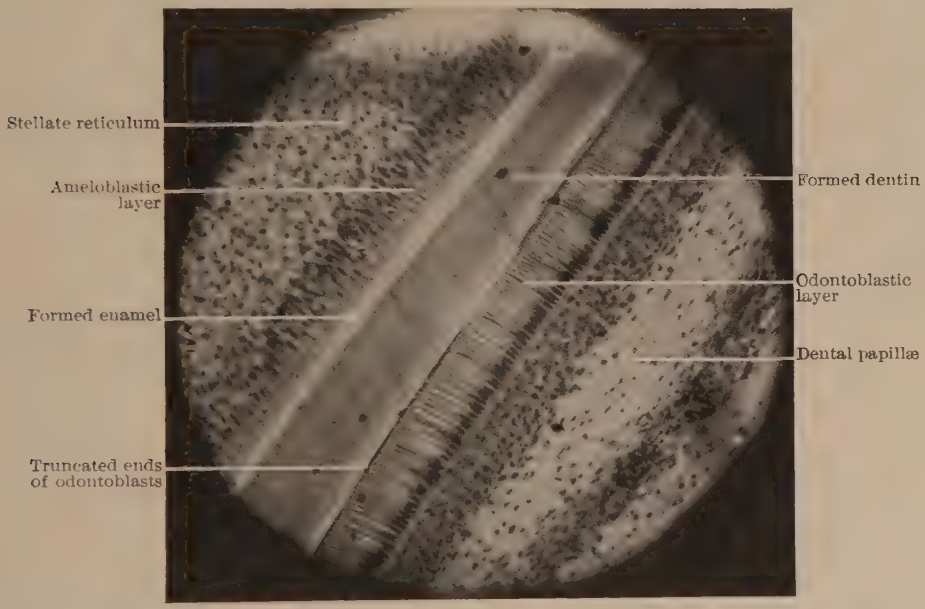


Fig. 158.—Section of tooth-follicle (human), showing the nuclei of the odontoblasts and of the ameloblasts, and the truncated ends of these cells (V. C. Latham) (× 325) (Marshall's "Operative Dentistry").

As the tooth grows its root, which is made up of four layers of cells, viz., the inner enamel epithelium, an intermediary layer, the enamel pulp, an outer enamel epithelium (see Fig. 163), tapers off into the part containing it and disappears. The enamel-cells down in the root cease to form enamel. Certain groups of these epithelial cells may remain

in the embryonic jaw, and are known as cell-rests or epithelial rests.

Malassez first directed attention to the significance of these tooth *epithelial rests*. He called them the *paradental epithelial débris*. He thought that their origin was from

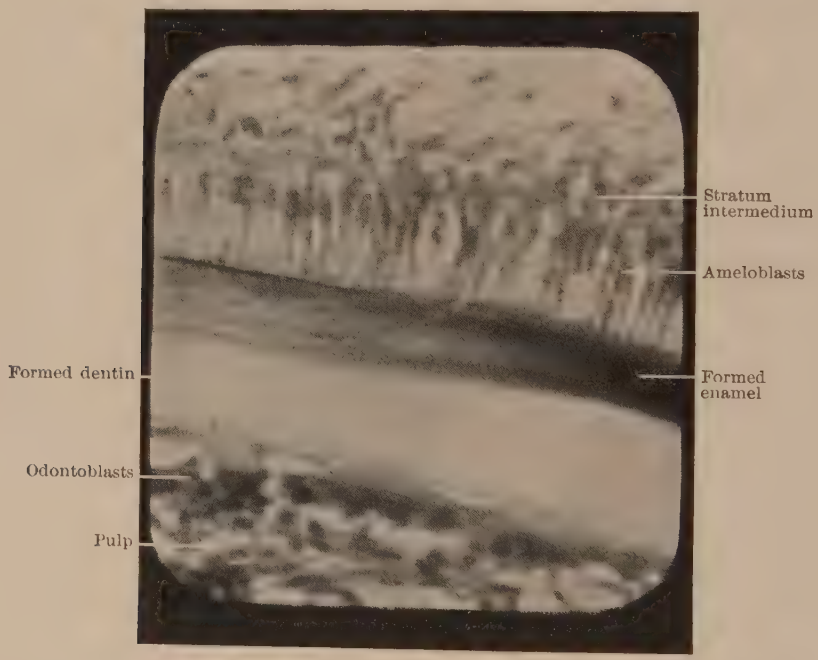


Fig. 159.—Section of developing human tooth, showing ameloblasts highly magnified (Zeiss one-twelfth oil-immersion) (Marshall's "Operative Dentistry").

one of three sources in fetal life: (1) From the mucous membrane of the fetal jaw; (2) from the epithelial cord or lamina between the mucous membrane and the enamel organ; or (3) from the outer epithelial membrane of the enamel organ itself about the tooth-root already mentioned.

Malassez is evidently correct in his interpretation of the importance of these epithelial rests.

### ADAMANTINE EPITHELIOMA

**Origin.**—The adamantine epitheliomata arise from the epithelial rests or paradental epithelial débris (Malassez).

Fig. 160.—Transverse section of dental follicle, showing first layer of ameloblasts (V. A. Latham) (× 325) (Marshall's "Operative Dentistry").

Certain cells of the enamel organ (see Figs. 156, 157, and 158) develop erratically, forming later, by their development, this tumor or new-growth.

There is very great likelihood that the cells of the primary epithelial cord (see Fig. 156), having served their usefulness, are detached from the original enamel organ cells, and may be the cells which, persisting, form the tumor under consideration.

This now generally accepted theory of the origin of these tumors explains the appearance of tumors of this

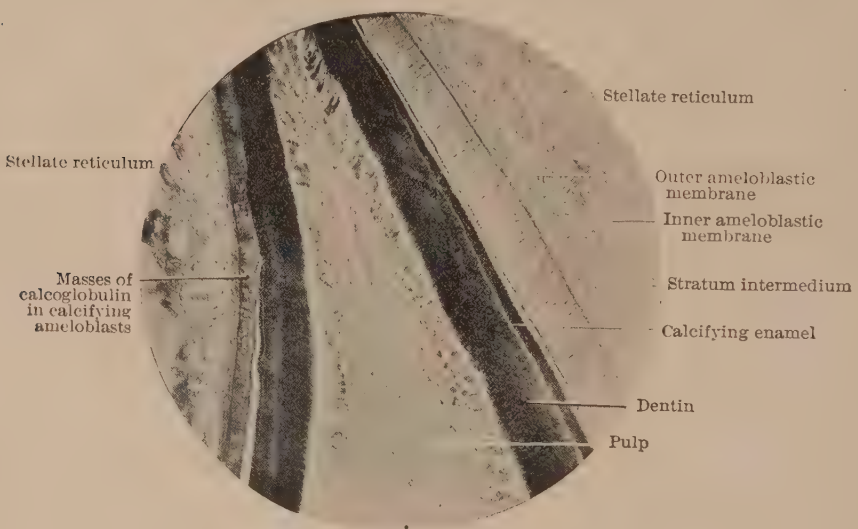


Fig. 161.—Developing tooth of embryo lamb (after Andrews) (× 105) (Marshall's "Operative Dentistry").

character within the body of the jaw, away from the surface epithelium, the cells, as rests, being included in the marrow-spaces of the bone.

This theory also explains the occurrence of tumors of this type more or less independent of the teeth. Inflammatory processes in the jaws and traumatisms are of very uncertain etiologic importance as primary conditions. They are only of secondary importance.

Synonyms.—Epithelial odontoma; adamantine epithelial tumor; adamantinoma; cystic carcinoma; adenosar-

Fig. 162.—Longitudinal section of root of tooth *in situ*, showing relation of the tissues and Sharpey's fibers in the alveolar process (F. B. Noyes): *D*, Dentin; *N*, Nasmyth's membrane; *C*, *C*, cementum; *F*, fibers supporting gingivus; $F^1$, fibers joining the outer layer of periosteum over the alveolar process (Sharpey's fibers); $F^2$, fibers running from cementum to bone; *B*, bone or alveolar process (Marshall's "Operative Dentistry").

coma; adenocarcinoma; multilocular dentigerous cyst; cystadenoma of the jaw.

**Clinical Course.** -The adamantine epithelioma is one of the forms of the odontomata. It is not an uncommon growth. It is seen almost as often as is the benign dentigerous cyst.

It takes its origin from embryologic epithelial remains

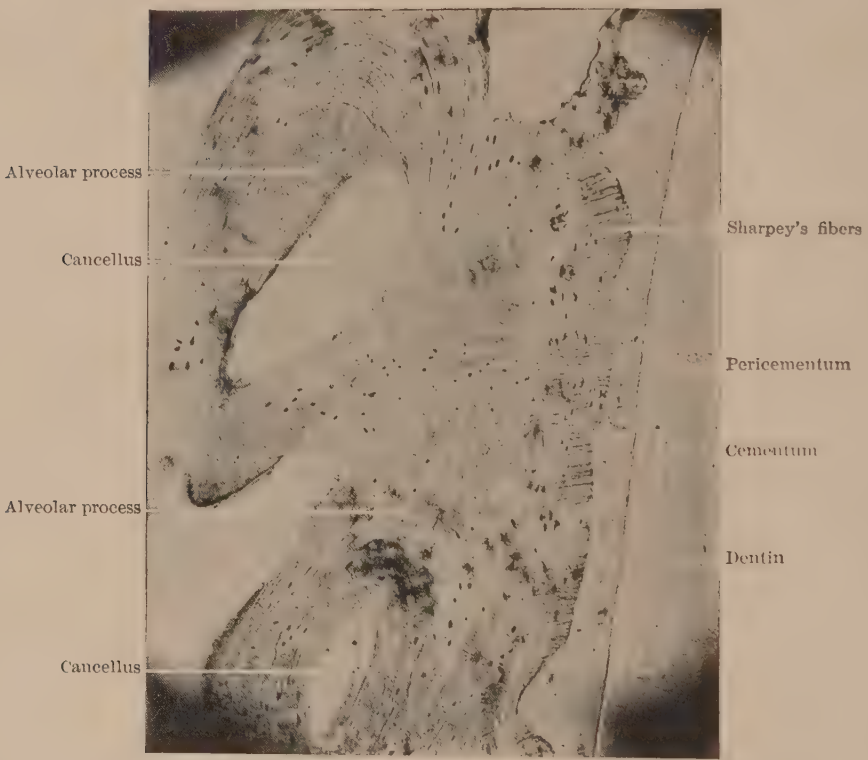


Fig. 163.—Vertical section of human alveolar process and cuspid tooth *in situ* (V. A. Latham) (×100) (Marshall's "Operative Dentistry").

of the tooth-germ,—from the enamel organ,—hence its name, adamantine epithelioma. (See Figs. 153, 155, and 158.)

It is the most benign form of an epithelial tumor of the jaw. This tumor *appears in young adults,* that is, between the ages of twenty and forty. It is rarely seen during the

age of the milk-teeth, nor does it often develop in old age. The age of the youngest case recognized and recorded is eight years. The age of the oldest case reported is sixty-one years. It may start after the pulling of a tooth as a swelling in the gum. The pulling of a tooth may be attended with the escape of a thin, brown, odorless fluid, the contents of a cystic cavity.

Fig. 164.—Case of adamantine epithelial tumor of the lower jaw (author's case). (See Fig. 165.)

*Sex Relationship.*—The adamantine epithelioma occurs with about twice as great frequency in females as in males. Sex is of little importance as an etiologic factor.

*Situation.*—It occupies most frequently the lower jaw, near the angle—the region of the molar teeth. A very few cases are recorded in the upper jaw. Albarran and Bloodgood each mention one case.

It is situated not only in the lower jaw, but usually on one side of the lower jaw. In its growth, starting from the alveolar border, it may project from that border as a distinct tumor. It may start within the body of the jaw, and enlarge upward toward the temporomaxillary articulation,

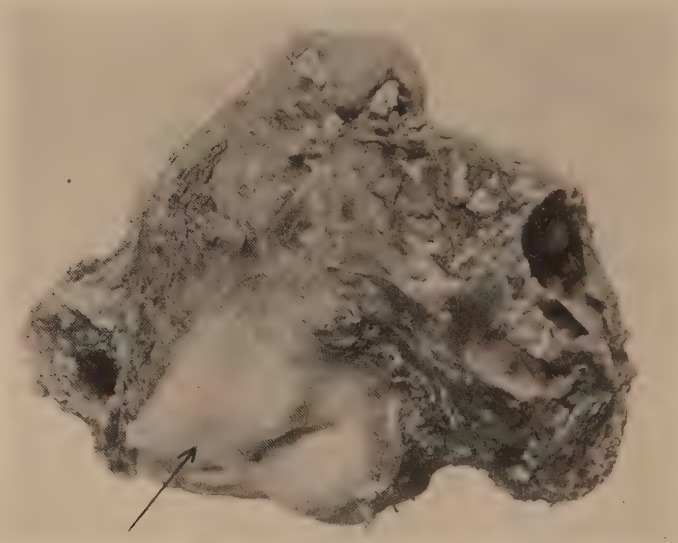

Fig. 165.—Case of adamantine epithelioma and dentigerous cyst of the lower jaw. Gross specimen. Arrow points to the mucous membrane covering the alveolar process over the tumor of the lower jaw. Recovery. No recurrence (author's case) (W. F. Whitney, pathologist).

and forward toward the symphysis of the jaw, expanding the jaw as it grows, creating a tumor with thin bony walls.

If the growth begins in the upper jaw, it will be very likely to expand into the antrum until the antrum is filled by the growth. No tumor will appear until the antrum is filled. The eyeball under these circumstances is not much displaced.

Fig. 166.—Adamantine epithelioma and dentigerous cyst of the lower jaw. Section of the tumor. Note the cystic character and notice the solid portion of the tumor—the adamantine cells were found in this portion. Recovery. No recurrence (author's case) (W. F. Whitney, pathologist).

Fig. 167.—Case of adamantine epithelial tumor after operation. Note the median lip and chin portion of the incision. (See Figs. 165 and 166.)

Fig. 168.—Case of adamantine epithelial tumor after operation. Note the posterior portion of the line of the incision.

*Size.*—The adamantine epithelial tumor varies in size. It may be recognized when as small as a walnut. It may grow to the size of a grape-fruit or an orange. It may attain a very great size. (See Figs. 174, 175.)

*Rate of Growth.*—Although these tumors are usually of slow growth, they may increase in size with considerable

Fig. 169. Fig. 170.

Figs. 169 and 170.—Case of adamantine epithelioma of the lower jaw (Massachusetts General Hospital series).

rapidity. The tumor growth may, therefore, be said to be variable. A sudden increase in size may be without apparent reason. Pain will be dependent upon the rapidity of the growth or the presence of an infection. A very rapidly growing tumor will cause pain by direct pressure upon nerve-trunks.

*Relation to Jaw.*—The adamantine epithelial tumor is

fixed and intimately connected with the jaw immovable. The tumor may extend from the angle of the jaw quite to the symphysis. The surface of the tumor is slightly irregular. This irregularity of the surface is due to the cystic

Fig. 171.—*X*-ray of tumor previous to operation. Clinical appearance seen in Figs. 169 and 170.

and solid character of the growth. The growth may be wholly solid or cystic or both solid and cystic.

*Character of Mucous Membrane.*—The mucous membrane covering the tumor is usually normal in appearance, without signs of ulceration. If an infection of the growth occurs, fistulæ may result, communicating with the cystic interior of the tumor and with the mouth. The *lymphatic glands*

*are not enlarged.* In the presence of an infection of the growth the lymphatic glands of the neck will appear enlarged.

**Case of Adamantine Tumor of Jaw.**—A. G. C. Female, twenty-three years old. Married. Massachusetts General Hospital Record, vol. ccclxxxii, p. 28. (See Figs. 169, 170.)

Fig. 172.—Section of Fig. 171. Dentigerous cyst. Adamantine epithelioma. Sarcoma (J. C. Warren).

Four years ago was troubled by an ulcerated tooth. Many teeth of the lower jaw were removed. Four months ago a lump appeared upon the inside of the jaw. It opened and discharged. Since that time there has been a gradual increase in the size of the lump. Two years ago the swelling of the lower jaw appeared, as seen in the accompanying illustrations (Figs. 169 and 170). An operation was done at this time for the removal of the tumor and excision of the left half of the lower jaw. The glands of the neck were removed.

Pathologic report (see Figs. 172, 173): A mass the size of an infant's fist growing in the jaw, which was distended over it. The mass was covered in places with a thick shell of bone; in other places by a thin, parchment-like covering of bone. The cavity in the bone was lined with a distinct sac, and between the sac and the tumor was a cavity containing a little serous fluid. Upon section the surface appears

Fig. 173.—Dentigerous cyst. Adamantine epithelioma. Sarcoma. (See Figs. 169, 170.)

gray, opaque, and homogeneous, with extensive areas of fatty degeneration throughout.

Microscopic examination showed a fibrous tissue stroma in places, with large meshes, filled, apparently, with a serous fluid; in other places the basic substance was more uniform, and there were present large round-cells in great numbers. Blood-vessels were present in the growth, some with well-marked walls and others with sinus-like openings. Scat-

tered throughout the basic substance was a solid mass of cells of a character resembling epithelium. These, in places, had a central opening, or lumen, giving the impression of a more or less irregular, tubular, glandular growth in the midst of the basic tissue. Diagnosis: Sarcomatous-like dentigerous cyst and adamantine epithelioma tissue (W. F. Whitney, pathologist).

At the end of two years the patient was in good condition, and there has been no recurrence of the disease.

If the tumor, or any part of it, ruptures into the mouth, the growth of the tumor often ceases. Pressure upon the surface of the tumor may elicit from the thin bony covering a parchment-like, crackling sound.

The following are the *characteristics of an adamantine epithelioma:* A tumor of slow growth, in a young adult; affects the lower jaw; starts from the periphery, sometimes from the center of the jaw; no ulceration over its surface; of considerable size; variable growth; no glandular enlargements; occupies one side of the jaw, rarely in the midline; solid and cystic; of rather irregular outline, with a surface which crackles upon palpation; teeth near the tumor more or less irregular and often loose.

*Relation to the Dentigerous Cyst.*—The slow growth of the adamantine epithelial tumor differentiates it from the malignant tumors of the jaw. It may grow for many years (twenty) before operative relief is sought. So commonly is the dentigerous cyst found in combination with the adamantine epithelioma that it may be difficult to distinguish between a simple dentigerous cyst and a combination growth until the cross-section of the tumor is made. (See

Fig. 172.) In those instances where no cyst is found it is quite possible that the epithelial element in the growth has completely filled all the dentigerous cystic cavities.

These tumors, at their beginning, cannot easily be mistaken for an *epulis*, for the mucous membrane covering

Fig. 174.—Adamantine epithelioma of the upper jaw. Woman aged fifty years. Duration, ten years. Operation. Death (Halsted and Bloodgood).

them remains intact, whereas the surface covering a large epulis is usually ulcerated.

When the adamantine epithelial tumor starts in the center of the bone and expands the bone, it is difficult to distinguish it from a *dentigerous cyst*. After section of the

Fig. 175.—Adamantine epithelioma and dentigerous cyst. Woman aged thirty-seven years. Duration of growth, twenty years. Removal. Well after five years (Bloodgood).

tumor the white, finely granular tumor tissue and multiple small and large cysts are discovered.

*Carcinoma* usually appears connected with the upper jaw, and in later life than the adamantine tumor. Carcinoma ulcerates rather early if it is starting in the mouth. The ulceration of the adamantine tumor is much later, and is almost always associated with an infection.

Fig. 176.—Dentigerous cyst. Adamantine epithelial tumor. Removed. Recovered (W. B. Rogers).

A *sarcoma* may be difficult to distinguish from a solid adamantine tumor. If all the teeth are present; if the tumor is of the upper jaw or near the angle of the lower jaw, it may be a sarcoma.

**Gross Pathology.**—A section of the tumor finds a thin, bony wall inclosing the tumor proper, which is usually partly solid and partly cystic. The cysts are filled with clear, yellowish or reddish, slightly viscid fluid, often con-

Fig. 177.—Adamantine epithelioma and dentigerous cyst. Man fifty-four years of age. Duration of tumor, twenty years. Operation advised and refused (Halsted and Bloodgood).

taining cholesterin crystals. Bony and fibrous trabeculæ are seen to separate the various portions of the tumor.

Fig. 178.—Dentigerous cyst. Adamantine epithelioma. Man aged forty-two years. Duration, eight years. Fistula into the mouth and externally. Operation. Recovery (Halsted and Bloodgood).

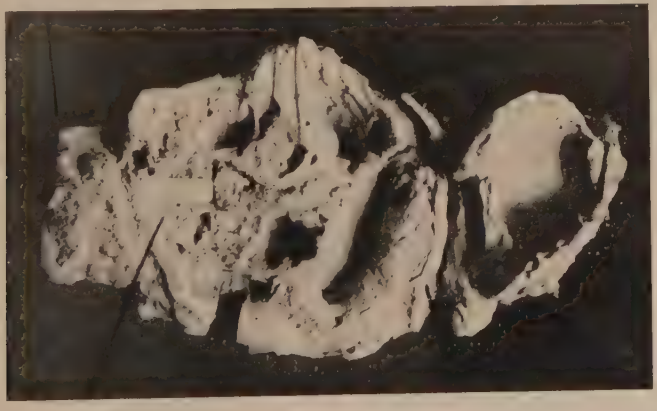

Fig. 179.—Dentigerous cyst. Adamantine epithelioma. Man aged forty-two years. Duration, eight years. Fistula into the mouth and externally. Operation. Recovery (Halsted and Bloodgood).

The cystic parts of the tumor appear similar to the benign dentigerous cyst.

The solid portions have a characteristic appearance. The cut surface of the tumor is white in color, and of a finely granular consistence.

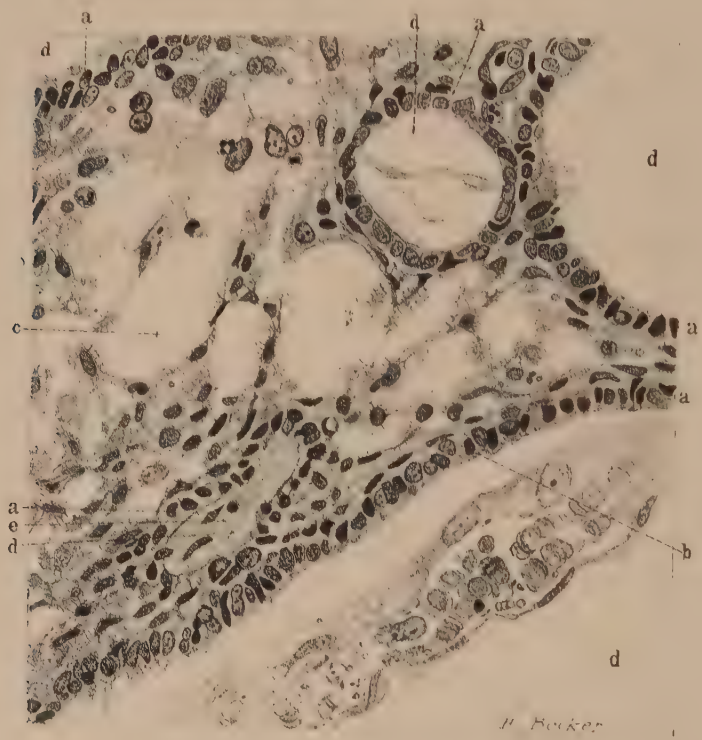


Fig. 180.—Adamantine epithelioma, showing part of an alveolus: a, External layer of cubic and cylindric cells, which is in places invaginated and, therefore, appears to be within the alveolus; b, layer of cells corresponding to stratum intermedium (see Fig. 159); c, tissue formed by anastomosing stellate cells, corresponding to stratum mucosum; d, invaginated stroma; e, blood-vessels in invaginated stroma (Steensland, in Journal of Experimental Medicine).

Definite alveoli can be made out, and the granular material may be scraped away with the knife.

In gross, the solid portion of the tumor has the appearance of a squamous-cell carcinoma.

**Microscopic Pathology.**—The appearances in more detail are as follows (I have followed closely Steensland's study of these cases):

The tumor itself consists of a connective-tissue stroma, in which there are alveoli formed by epithelial cells.

The epithelial elements represent the enamel organ, and are largely in the stage corresponding to the greatest development of the stratum mucosum (Fig. 180). One or two areas, somewhat removed from the periphery, represent the stage immediately preceding the development of the stratum intermedium (see Fig. 159) and the stratum mucosum (Fig. 181, c). No definite karyokinetic figures are seen here, but some nuclei stain more deeply than others, and have a slightly ragged surface. This is represented at d, Fig. 181, where, apparently, the stratum intermedium is beginning to develop. Intercellular bridges, perhaps corresponding to those of the epithelium of the mucous membrane of the mouth, are seen. The appearance here suggests carcinoma. In many places the stratum mucosum is largely replaced by cysts containing a finely granular material staining with eosin. Anastomosis of the alveoli suggests that the epithelial constituents form a solid framework similar to that which has been shown to exist in carcinoma by means of reconstructed serial sections.

In the large alveoli is seen an external layer of cells, which in some places are cylindric; in other places, cubic (Fig. 180, a). The layer is occasionally invaginated, and therefore appears in the section to be situated inside of the alveolus. The cylindric cells perhaps correspond to the inner epithelial layer of the enamel organ; the cubic cells, to the outer epithelial layer. (See Fig. 161 in development

of the tooth.) Often, but not regularly, within the external layer are one or more layers of flattened cells, which tend little by little to assume the stellate form and correspond to the stratum intermedium (Fig. 180, b).

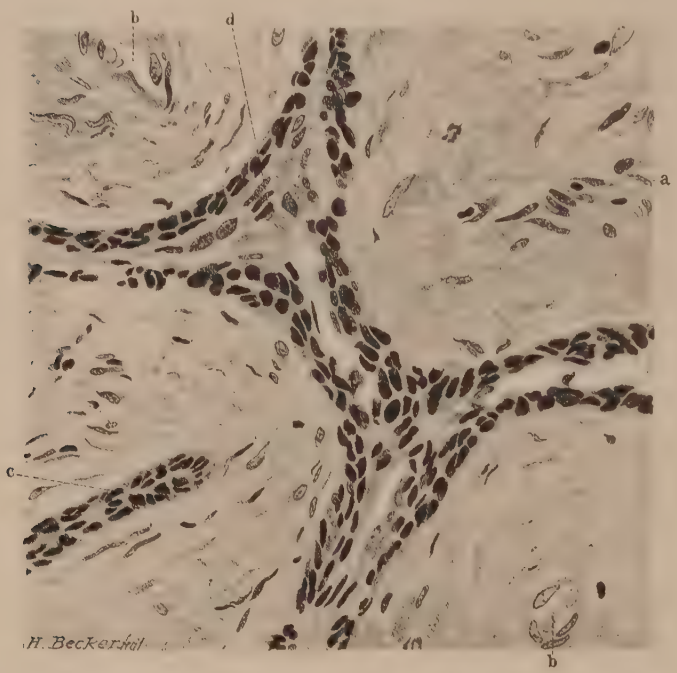


Fig. 181.—Epithelioma adamantinum: a, Stroma; b, b, blood-vessels in stroma; c, cells representing that stage which precedes the formation of the stratum intermedium and stratum mucosum; d, cells representing the early development of the stratum intermedium. Nuclei are deeply stained and have a ragged surface, suggesting karyokinesis (Steensland, in Journal of Experimental Medicine).

Occupying most of the interior of the solid alveoli is the most characteristic feature of the tumor, the stratum mucosum, or enamel pulp, consisting of anastomosing stellate cells (Fig. 180, c). When seen under a lower

power, it might be mistaken for mucoid tissue, and, especially when present in large areas, might lead to a diagnosis of myxoma.

There are invaginations of the external layer of cells which, with the adjacent stroma, simulate the "Anlagen" of teeth in their early stages (Fig. 180, a). This gives to the alveoli the appearance of gland tubules in a stroma of mucoid tissue (Fig. 180), especially in places where the invaginated stroma has largely lost its fibrillar character and appears homogeneous (Fig. 180, d). Evidences of karyokinesis are seen in the external layer, and to a less extent in the stratum intermedium.

Various stages in the development of cysts are well seen. They are due evidently to a hyaline and granular degeneration of the stellate cells, and to an accumulation of fluid between these cells. The formation of the stratum mucosum enamel pulp is apparently associated with an accumulation of fluid between the cells, the formation of long processes of the cellular protoplasm, and the gradual disappearance of the intercellular bridges (Fig. 180). No evidence of enamel, dentin, or cement is seen. Chibret has described the formation both of enamel and of cementodental tissue in a similar tumor. The stroma (Fig. 181, a) consists of dense connective tissue in which only a few blood-vessels (Fig. 181, b, b) are apparent.

*Kruse's Description.*—Of the microscopic appearance of these tumors a clear description is that given by Kruse. He reports three cases representing different stages in the development of the enamel organ. In the individual cases, also, different stages are represented. In the first case the epithelial constituents consist of dendritically

branching twigs, composed of epithelial cells, and forming solid masses, situated in a poorly vascularized stroma.

The form and arrangement of the cells are similar to the form and arrangement of the cells of the dental ridge in an early stage of development. The tumor, therefore, corresponds in its structure to an early stage of the "anlage" of the tooth.

Kruse's second case has in part the same structure as the first, but there is more tendency toward the formation of a peripheral layer of cylindric cells. In some places small cysts are present, and there is one macroscopic cyst, 2 cm. in diameter. Comparison with a somewhat later stage of the dental "anlage," where outer and inner enamel epithelium, stratum intermedium, and stratum mucosum are present, show, according to the description, that the epithelial twigs of the tumor are in all details like the dental "Anlage," and that the relation of the cells to each other is the same.

The third tumor is conspicuously cystic. Some cysts are microscopic in size, while the largest is the size of a hen's egg. But the solid parts are microscopically like the first two tumors, presenting solid twigs of polygonal epithelial cells, some with a peripheral layer of cylindric cells, some with beginning cyst-formation. The tumor consists largely of well-developed cysts. The size and the structure of the cysts vary, but in general a definite size corresponds to a definite arrangement of the cells. In the smaller cysts the wall is lined with low cylindric epithelium, while the lumen contains a granular hyaline material. The larger cysts are lined by a more or less cubic epithelium and three or four layers of squamous cells.

There is then, according to Kruse, a continuous series representing varying degrees of differentiation, each of which has certain individual characters and, in addition, presents transitional stages to the others.

Chîbret's work is especially valuable. He describes a case in which there is a pronounced tendency toward the formation of the various tissues of the teeth. The case presents all the stages in the formation of the tooth up to the development of enamel and of cementodental tissue. These substances are found at the borders of the most highly differentiated alveoli. The cementodental tissue resembles cement, since it contains large osteoblasts and dentin, and since branching canaliculi are present and vessels are wanting. In very few of the cases described in the literature does there appear to have been represented the epithelial sheath of Hertwig. Perhaps this explains the absence of roots and of characteristic cement and dentin.

A remarkable specimen is described by Hildebrand. He observed, in the case of a boy nine years old, an excessive development of masses of teeth in the interior of the upper and lower jaw bones on both sides. Not only conglomerations of teeth, but also more or less completely isolated teeth, were present. The eruption of the teeth appeared to have been entirely irregular. Perhaps the entire epithelial "anlage" of the teeth had assumed an abnormal function.

**Treatment of the Adamantine Epithelioma.**—The operative treatment will be either partial or complete. If the tumor has not destroyed the whole thickness of the bone on both sides, it may be possible to remove all the new-growth and to leave a bony wall to support the jaw

and to preserve the contour of the face. If, on the contrary, the whole thickness of the jaw is destroyed or the bone is so thinned as to appear an inefficient support if left, then it will be wise to resect the jaw bone, including all of the growth.

It is of the very greatest importance to decide, upon incising the tumor, whether or not the growth is probably benign through its whole extent. If there is little or no doubt of its benignancy, then the partial operation may be done.

Many of the adamantine tumors hitherto have been treated by a too radical procedure. Recent surgery has demonstrated conclusively that the partial operation is safe. The complete resection under these conditions is unnecessarily mutilating.

There is usually no glandular involvement in these cases. Dissection of the cervical lymph-nodes is not called for. However, if a complete resection is done, it will be wise to remove the lymphatic glands in close proximity, *i. e.*, those of the submaxillary and submental regions.

There are no cases recorded in which recurrences have occurred after a thorough operation. If a bit of the cyst-wall is inadvertently left *in situ*, as was done in one of my own cases, a new cyst may form at the old operation site and necessitate a second operation.

The **prognosis** in these cases of adamantine epithelioma is good, *i. e.*, there is no local recurrence following complete removal. The adamantine tumor is not dangerous to life.

### SELECTED BIBLIOGRAPHY OF ODONTOMA

Steensland: Jour. Exp. Med., 1904.
Hildebrand: Deut. Zeit. f. Chir., 1890–91, vol. xxxi, p. 282; 1893, vol. xxxv.

Kruse: Virchow's Arch., 1891, vol. cxxiv, p. 137.
Chîbret: Arch. de méd. expér., 1894, vol. vi, p. 278.
Becker: Arch. f. klin. Chir., 1894, vol. xlvii, p. 52.
Malassez: Arch. des physiol. norm. et path., 1885, vol. v, p. 129; *ibid.*, 1885, vol. v, p. 309.
Krause: Virchow's Arch., 1891, vol. cxxiv, p. 137.
Pincus, Walther: Arch. f. klin. Chir., vol. lxxii, pp. 995–1021.
Oliver, J. C.: Trans. Amer. Surg. Assoc., Philadelphia, 1902, vol. xx, pp. 383–395.
Barrie, Geo.: Annals of Surg., September, 1905.
Sirantoine, Leon Alfred: Étude Critique sur la Pathogenie des Kystes Paradentaires Uniloculaires, I. D. Nancy, 1903.
Borst, Max: Die Lehre von den Geschwülsten, 1902, vol. ii, p. 605.
Kuhlo, Friedrich: I. D. Leipzig, 1903 (Trendelenburg's clinic).
Martens: Charité Ann., Berlin, 1903, vol. xxvii, pp. 288–295.
Bloodgood: Buck's American Practice of Surgery.

## CYSTS OF THE JAW

There are two kinds of cysts of the jaw, the follicular or dentigerous, and the periosteal or root-cysts.

The follicular or dentigerous cysts start previous to completed dentition. They are unassociated with injury or disease. The periosteal or root-cysts may arise at any time, and are associated with normally placed adult teeth, often carious.

### Dentigerous Cyst (Follicular Odontoma)

This is not an uncommon form of benign odontoma. It occurs in the lower jaw a little more frequently than in the upper jaw. In the lower jaw it is often seen as a small swelling under the gum, the size of an olive, upon the outer side of the alveolus. Upon the tongue side of the jaw the cyst of this size does not encroach. Palpated upon the outer side, the cyst-wall will feel thin and parchment-like, and may cause a crackling sensation upon deep pressure as the thin covering is indented by the finger.

The cyst appears in the jaws near to the row of teeth. A tooth may be congenitally misplaced. A cyst developing in the paradental rest of a misplaced tooth is spoken of as a heterotopic cyst. Thus, both Dupuytren and Paget record cases occurring in the hard palate.

The cyst rarely appears during the first dentition. It

Fig. 182.—Dentigerous cyst of upper jaw. Colored girl, aged nineteen; swelling, thirteen years; parchment crepitation; teeth normal. Complete excision of upper jaw on diagnosis of sarcoma. Death from pulmonary abscess (from original, loaned by Joseph C. Bloodgood).

appears in adolescence and young adult life, *i. e.*, during or after the second dentition, rarely after forty.

There is sometimes a tooth missing from the jaw, unerupted, after a dentigerous cyst has developed. When the cyst develops after the second dentition, it usually arises

from the wisdom-teeth. Magitot records nine cases between the years of twenty and thirty, all of which started from the "anlage" of a wisdom-tooth.

The *growth* of the cyst is slow, causing, if in the center of the bone, a gradual expansion of the bony walls of the jaw.

Unlike other cysts associated with new-growths, the development of the cyst advances along with a new-growth

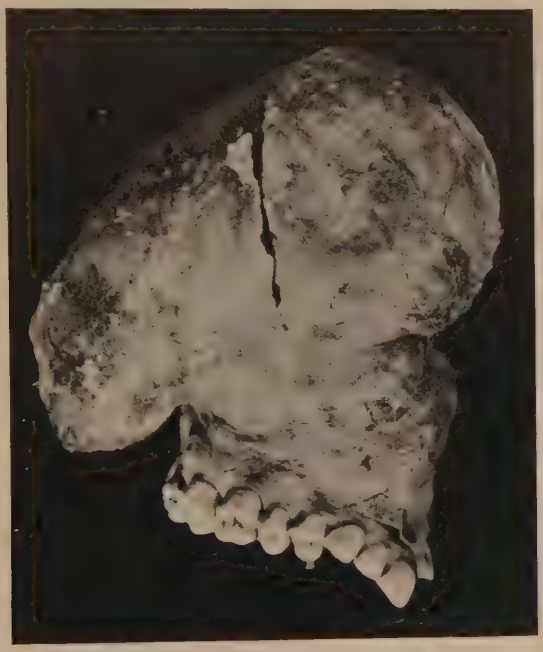

Fig. 183.—Benign dentigerous cyst of the upper jaw. Girl, nineteen years old. Duration, thirteen years (Bloodgood).

of bone in its wall, so that the bony wall is not a mere expansion of a previously existing bony capsule, with subsequent pressure atrophy and thinning of the wall, but the shell of bone is formed over the advancing and expanding tumor.

Fig. 184.—Dentigerous cyst of the lower jaw. Woman, aged twenty-one. Good recovery (Army Medical Museum, No. 1258. See Fig. 185).

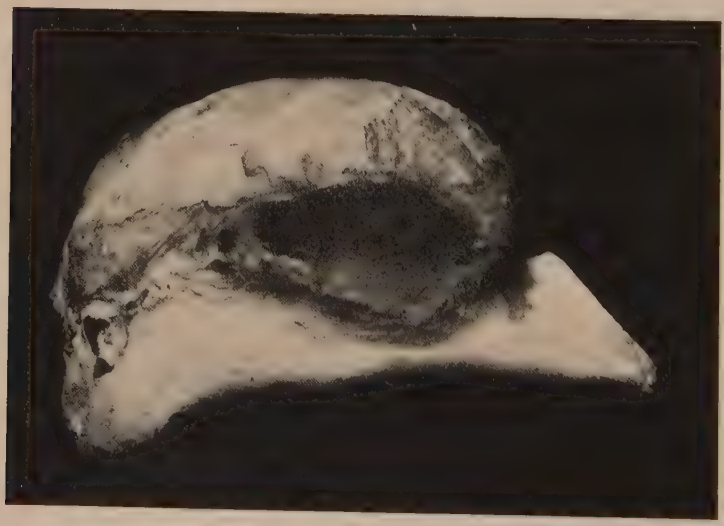

Fig. 185.—Same case as Fig. 184. Dentigerous cyst of the left lower jaw in a woman aged twenty-one.

When seated in the *upper jaw*, these cysts may reach



Fig. 186.—Benign dentigerous cyst of the lower jaw (J. C. Warren collection).



Fig. 187.—Lower jaw. Multilocular dentigerous cyst, benign, in a woman twenty-nine years old. Duration of the tumor, a little over a year (Warren Museum, No. 4324).

enormous size. There is little pain ordinarily associated with their growth. If the cyst-wall should include the

inferior dental nerve, pain might be caused in the distribution of this nerve.

The mucous membrane covering this tumor is not found ulcerated. Fistula is uncommon.

The molar or canine teeth are the ones most often missing in connection with the development of these cysts, so

Fig. 188.—Same as Fig. 187. Benign dentigerous cyst of lower jaw cut in section. Note many cysts. Nothing malignant in growth (Warren Museum, No. 4324).

that the common seat is unilateral. Barrie's case was exceptionally placed at the symphysis of the lower jaw. There is really no reason why these cysts should not develop anywhere in the body of the jaw.

In the case of Rogers (see Figs. 201, 202) the mouth was occupied almost wholly by the bulging tumor, so that

the tongue was depressed backward and its tip could not be placed within a long distance of the lips.

The lower teeth are so displaced and loosened that they cannot be opposed to those of the upper jaw. Food requiring mastication cannot be taken. Liquid and soft solid nourishment has to be taken. Articulation is most difficult. Such is the picture of a benign dentigerous cyst which has progressed far. Examination of the mucous

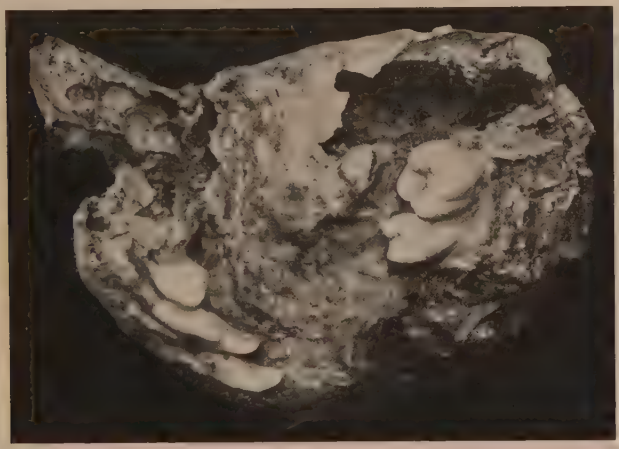

Fig. 189.—Dentigerous cyst of the lower jaw from a woman aged sixteen. Recovery. Tooth seen in the cavity of the cyst (Army Medical Museum, No. 7439).

membranes will find in such cases no ulceration, and very likely no cervical lymphatics will be enlarged.

**Etiology.**—Dentigerous cysts arise from the overgrowth of some part of the follicle of a non-erupted tooth. According to the stage of the development of the tooth in connection with which the cyst forms, there will be found, at operation or upon examination after operation, the whole or part of a tooth-like object, in appearance sometimes

resembling the crown or even the whole tooth. The crown of the tooth is usually looking toward the interior of the cyst, and the root looks outward. The cyst lies over the crown of the tooth, which lies at the base or bottom of the cyst. (See Fig. 189.)

The tooth-like bodies seen in these follicular cysts consist usually of the crowns of teeth; the root is the least

Fig. 190.—Dentigerous cyst of each half of the lower jaw. In one specimen a rudimentary tooth may be seen (Army Medical Museum, No. 5285).

well-developed part. There may be a number of these tooth-like bodies in the cyst. There may be as many as 25 to 100 or more pieces of partly developed teeth. (See Figs. 213, 214.)

**Case of Cystic Odontoma.**—A. C., thirty-two years old. General health has always been good. Both the upper and lower wisdom-teeth have been removed. The present

difficulty began four summers ago, with pain in the region of the right lower jaw. The pain was accompanied by a swelling in this region.

Examination finds a tumor occupying the region of the right lower jaw, involving the whole thickness of the angle of the jaw, and about the size of a small flat orange.

Fig. 191.—Excision of right half of lower jaw for a dentigerous cyst. Note line of incision and patient's side face after operation (author's case).

Fig. 192.—Drawing of tumor in case Fig. 191. Note relation of tumor to jaw.

Operation: One-half of the lower jaw was excised, the bone being removed from the temporal maxillary joint to just behind the right canine tooth.

Pathologic report: Warren Museum, Specimen No. 9263. The specimen consists of the ramus and about 5 cm. of the body of the right side of the lower jaw. The greater part of this is occupied by a new-growth projecting chiefly on the inner surface, replacing the bone, leaving only a thin shell externally. The tumor is partly cystic and

partly solid; the greater part is a cyst about 4 cm. in diameter, lying mostly in the ramus, and extending from the tip of the coronoid process toward the angle. Several very much smaller cysts lie about it, and in the body is the more solid part of the tumor, which has a finely spongy section surface. Lying directly upon this is a molar tooth, apparently pressed out of its socket by the invasion of the growth, which is here sharply defined from the bone.

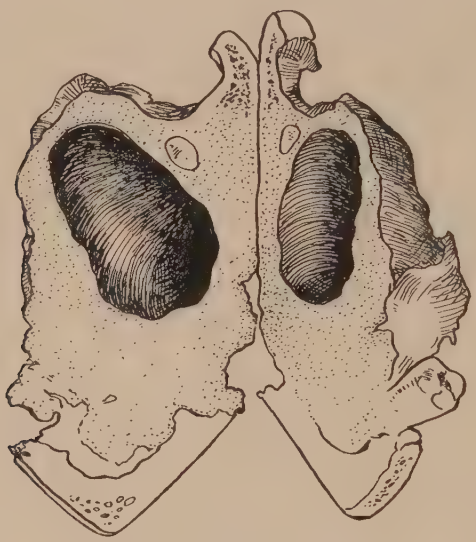

Fig. 193.—Same specimen as Fig. 192. Note relation of cyst to jaw.

Microscopic examination showed a fibrous tissue ground and framework, in place of which were solid masses of long narrow cells, in general aspect recalling those of a tooth follicle. These permeated the tissue in different directions as irregularly branching columns. Often the center of these columns was occupied by a series of anastomosing star-shaped cells with fine connecting prolongations, recalling a myxomatous tissue. In others there was a cavity in the center filled with a clear fluid, and where numbers of these

small cysts were contiguous, the connective tissue between them was reduced to a thin partition, and the whole had a finely honey-combed appearance. From these to the larger (macroscopic) cysts all stages were to be found.

The growth can be classed as a cystic follicular odontoma.

*Subsequent History.*—General health has been excellent. Three years after the operation a swelling appeared at the middle of the old incision. This swelling was accompanied by a little pain. Swelling became the size of an English walnut, and then a second operation was done, about three years after the first operation. The tumor was removed, and was found to have been a small cyst, starting probably from a bit of the membrane of the original cyst.

Present condition—three years after the last operation, six years after the first operation: General health is perfect, and there has been no local recurrence of the growth.

The tooth will occupy different positions in the cyst. It may be concealed in the wall of the cyst, and be covered by living membrane; it may lie free in the cavity; it may be upright in a natural position, or lie crooked and in an unusual position. The tooth may not be seen at the operation; indeed, if the cyst has begun to form at an early period in the development of the tooth-follicle, it is perfectly conceivable that no tooth will be grown at all in that particular cyst. Just because a tooth is absent from a cyst does not mean that the tumor is not a true dentigerous cyst. Malassez's theory of the origin of dentigerous cysts is the most reasonable of all theories.

*Malassez explains the origin of the dentigerous cyst* as he explains the origin of other odontomata, viz., by the develop-

ment of the epithelial paradental rests. Barrie has reported a case of dentigerous cyst of the lower jaw. This case is one of very considerable value. The histologic examination (Bloodgood) discovers that the wall of the cyst is lined with distinct adamantine epithelium. Consequently, this dentigerous cyst has the same origin as the adamantine

Fig. 194.—Girl, twelve years old. Dentigerous cyst of right lower jaw, said to have been noticed eight months previously (F. W. Dudley, Manila, P. I.).

Fig. 195.—Girl, twelve years old. Dentigerous cyst of right lower jaw, said to have been noticed eight months previously (F. W. Dudley, Manila, P. I.).

epithelium, viz., from the "epithelial paradental rests." This case of Barrie's establishes, upon a pretty firm basis, the etiology of the dentigerous cysts according to Malassez's theory.

This observation is in line with the well-recognized fact that the adamantine epithelioma and the dentigerous

cyst are often found together. A more careful microscopic examination of the fresh dentigerous cysts operated upon will doubtless confirm the very valuable observation of Bloodgood in the case of Barrie.

Whether the cyst forms because of a disturbance in the development of the normally placed tooth-follicle (Broca),

Fig. 196.—Benign dentigerous cyst of lower jaw. Woman, thirty-seven years old (F. W. Dudley, Manila, P. I.).

or whether it is due to a misplaced paradental rest developing, it is difficult to decide. Both views are possible.

W. F. H. Massachusetts General Hospital series, No. 142,209. A man, twenty-two years old, who first noticed a swelling of his chin three months previously. He had no pain or tenderness in connection with this swelling. The swelling appeared within the mouth, the outer side of the jaw, and to the left of the median line. Palpation of the

swelling within the lip disclosed a soft area. There was a missing canine tooth upon this same side, and a slight puriform discharge from the tooth-socket. The tumor was incised through the mucous membrane of the mouth, the cavity cureted, and a counteropening made and the cavity

Fig. 197.—Case of dentigerous cyst. Note the swelling of the cheek over the tumor.

Fig. 198.—Same case as Fig. 197. Note the tumor of the alveolar border of the jaw, its size, its situation, its position on the outer side of the jaw.

packed with gauze. The cavity healed in about five months. Practically well at the end of this time. (See Figs. 197 and 198.)

**Pathology.**—The cyst is often single. (See Figs. 183, 190.) Occasionally the tumor is composed of multiple cysts. (See Figs. 187, 188.)

The *walls of these cysts* are more or less irregular, and on the inner surface are lined by a layer of fibrous, tissue-like membrane, sometimes an epithelial layer, often only by granulation tissue. Barrie's case has already been referred to, which was lined by adamantine epithelium.

The *contents of these cysts*, besides a fully formed or partially developed tooth, consist of a sanguinolent material

Fig. 199.—*X*-ray of same case as Fig. 198. Note the tumor and absence of a tooth in that location.

or a clear or bloody or gelatinous fluid, which may contain cholesterin crystals. Calcification may take place in the wall of a dentigerous cyst. The contents may resemble sebaceous material, which will be found to be made up of fatty degenerated epithelial cells and cholesterin crystals. This type of cyst does not become much larger than a butternut. Its inner wall is lined with cuboid and stratified

epithelium. All the teeth are usually found present in the jaw. (See Fig. 197.) These dermoid-like cysts probably arise from the paradental rests.

Follicular cysts then may have within them, or lying in the wall of the cyst, an almost perfectly developed tooth,



Fig. 200.—Same case as Figs. 198 and 199, showing the wall of the cyst lining the cavity. Note the epithelial lining, the fibrous tissue, and the spaces filled with cholesterin crystals (photograph by Brown, Massachusetts General Hospital laboratory).

a partially developed tooth, a very rudimentary tooth, a piece of bone-like or dentin-like material, or nothing to suggest teeth at all.

The toothless follicular cyst of the lower jaw Mikuliez has called a dermoid of the jaw.

As in Barrie's case, the surface of the lining membrane

Fig. 201.—Multilocular dentigerous cyst (See Fig. 202.) (W. B. Rogers).

Fig. 202.—Multilocular dentigerous cyst of three years' duration (W. B. Rogers).

Fig. 203.—Appearance after removal of the multilocular dentigerous cyst seen in Fig. 202 (W. B. Rogers).



Fig. 204.—Benign dentigerous cyst of lower jaw. Woman, thirty-seven years old (F. W. Dudley, Manila, P. I.).

may not be perfectly smooth, but elevated in spots, these elevations projecting into the interior in a pedunculated fashion. This capsule may contain cells which resemble and suggest the stellate cells of the stellate reticulum.

The *multilocular cysts* which occur occasionally in the lower jaw and attain considerable size in young adults are probably multilocular dentigerous cysts. The most plausible theory for their origin is that of Malassez—from the

Fig. 205. Fig. 206.

Figs. 205 and 206.—Benign dentigerous cyst following blow upon cheek. Girl aged nineteen years. Duration, thirteen years (Halsted and Bloodgood).

débris epitheliaux paradentaires. Clinically and pathologically, they resemble the dentigerous cyst. In the absence of sarcomatous or carcinomatous tissue in their walls they should receive treatment similar to that given the dentigerous cyst. If the bone of the jaw is completely destroyed and no possible bony bridge can be secured for support, even if no sign of malignancy is present, the tumor should be resected.

**A Case of Papillary Cystadenoma Arising From the Tooth-follicle.**—W. H. W. Thirty-six years old. Massachusetts General Hospital series. September, 1904.

Five or six years ago he had an ulceration of a right molar tooth. Following this there appeared a hard swelling at the site of the present tumor. The growth of the swelling was slow, but continuous. It had grown more rapidly during the past year. It was painless. It had been

Fig. 207.—Benign dentigerous cyst. Girl aged nineteen years. Duration, thirteen years. Same case as Figs. 205 and 206 (Halsted and Bloodgood).

incised for pus, but none was ever found. The first and second teeth were normal in number and position. The teeth in the region of the tumor were extracted two years ago. There are only two incisors left in the right mandible, and these are deformed.

The *x*-ray shows a cystic tumor. There is a fluctuating area over the tumor which extends from the symphysis to the angle of the jaw. (See Figs. 208, 209.) There is no ulceration. The swelling is chiefly outward, that is, away from the mouth cavity.

Fig. 208.—Papillary cystadenoma or follicular odontoma. Tumor of right lower jaw.



Fig. 209.—Note tumor of alveolar border corresponding to the external tumor.

Fig. 210.—Appearance in front view after operation.

Fig. 211.—Appearance in lateral view after operation.

Operation: An incision was made from the angle of the mouth diagonally backward and downward. There was found a thin, crackly shell of a multilocular cyst, the size of a peach, containing a clear, glairy fluid of an amber hue. The bony cyst-wall was absent over a part of the tumor, and

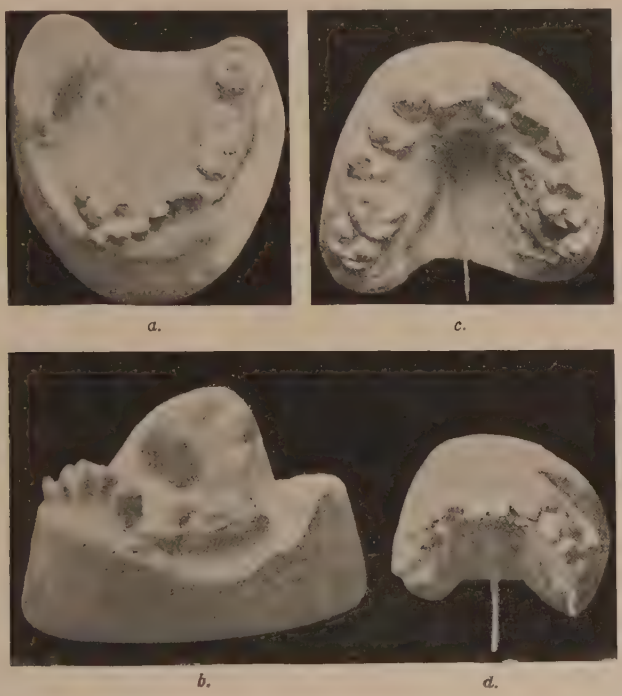


Fig. 212.—Follicular odontoma: *a*, *b*, Models of lower jaw indicating the original position of the tumor; *c*, *d*, models of upper jaw, exhibiting the displacement of the teeth (Cousins). (See Fig. 215.)

was replaced by a soft, homogeneous tissue, strongly suggestive of malignancy. A preliminary report by the pathologist was made of malignancy, and, therefore, one-half of the jaw was removed.

At present, seven years after the operation, there is an absence of all trouble with the jaw. (See Figs. 210, 211.)

Pathologic report (49–71), September, 1904: Fragments of a cystic tumor of the jaw, composed of thin, scale-like pieces of bone partly lined with a thin, mucous-like membrane, and partly with thick, soft, rather papillary tissue. Microscopic examination of the more solid portion showed a branching, tubular, gland-like arrangement of the epithe-

Fig. 213.—Tooth-like masses removed from the interior of a follicular odontoma of the jaw (Warren Museum specimen).

lial cells, the basement membrane of which seemed everywhere intact. Papillary cystadenoma, probably from a tooth-follicle.

(Signed) W. F. Whitney.

**Diagnosis.**—The dentigerous cyst usually develops in the lower jaw. It is situated near the angle of the jaw, in

the region of the molar teeth. The crackle to palpation suggests a cyst. A puncture of what is probably a cystic tumor, if the puncture is made within the mouth, is wise for diagnosis. An absent permanent tooth is suggestive that a slowly growing tumor in a young adult is a dentigerous cyst.



Fig. 214.—Tooth-like masses removed from a follicular odontoma of the jaw (Warren Museum).

A dentigerous cyst may be mistaken for a solid tumor, particularly if it is of the upper jaw. If the cyst grows in the center of the lower jaw, it may simulate a solid growth.

It is always to be borne in mind that an adamantine epithelioma may be associated with the simple dentigerous cyst; in fact, it is a not infrequent accompaniment of this cyst. A sarcoma may develop in the wall of the cyst.

(See Figs. 172 and 173.) The *x*-ray will prove of much assistance in diagnosis.

**Treatment.**—Having made, by exploratory puncture and by discovering a tooth or tooth remains, a diagnosis of a dentigerous cyst, the treatment consists in the removal of one wall of the cyst, thorough curetage of the interior of the cyst, and the packing of the space thus made with iodoform gauze (Partsch).

Fig. 215.—Follicular odontoma (Cousins). (See Fig. 212.) Many tooth-like bodies removed from tumor. Appearance of patient in 1896.

If the situation of the cyst permits, it is wise to so fashion the bone about the cystic cavity that a minimum amount of deformity will result after healing has taken place, and at the same time the maximum strength will be secured for the remaining bony jaw. It may be possible to secure a flap of normal mucous membrane to cover the defect, and then healing will be hastened. Almost all operative procedures upon these cysts, even the larger ones, can be con-

ducted through the mouth. It will be rarely necessary to divide the cheek.

Fig. 216.—Appearance of patient in 1899 (Cousins).

Fig. 217.—Appearance of patient in 1907 (Cousins).

If, because of the location of the tumor, it is thought wise to approach it by a skin incision to avoid mouth infec-

tion, just under the body of the jaw, the incision should be made so as to be concealed; then the mucous membrane should be reflected off and over the tumor through the skin incision. The surgeon should consider the presence or absence of an infection already existing within the cyst, for if, upon carefully approaching the cyst from the outside, infection is already present, the object of the procedure would be defeated.

Fig. 218.—A follicular cyst of the lower jaw in a man thirty-four years old. Duration of growth, nine years. Bony wall partially removed. Necrosis of bone limited in extent. A bicuspid tooth displaced at bottom of cyst removed; complete recovery (Heath).

It must be remembered that dentigerous cysts which have existed in such intimate relation to the mouth cavity often become infected from the mouth through minute communication with their interiors around the roots of the teeth. Heath has suggested the pressing of the two walls of the cyst firmly together in order to preserve as much bony support as possible.

Albarran always does a complete extirpation, to be absolutely sure of no recurrence. This is unnecessary in most cases.

### Compound Follicular and Composite Odontomata

These are varieties of odontoma originating from certain portions of the tooth-follicle. They are composed of varying combinations of the several tissues of the tooth-follicle. They may contain fibrous tissue, cysts, bits of enamel, dentin, and cement. Often queerly shaped masses resem-



Fig. 219.—An *x*-ray of a follicular cyst in the lower jaw of a nine-year-old girl. A displaced molar tooth seen (Perthes).

bling, in some instances, teeth are found loosely attached or free within the cyst-wall. These masses may be very numerous. (See Figs. 213, 214.) These tumors may grow to be of large size.

*Dental cysts* occur usually in the upper jaw in connection with the permanent teeth. They rarely attain large size; usually they are as large as an olive before treatment is

sought. Dental cysts are associated with the canine or incisor teeth and never contain rudimentary teeth or tooth remains. They are thus distinguished from small dentigerous cysts in that the latter are situated in the lower jaw, and usually in connection with the molar teeth.

Dental cysts give rise to slight swelling of the lip and cheek. They are of slow growth, and usually painless unless they grow to great size. (See Fig. 220.)

Fig. 220.—Dental cyst. Note the partial obliteration of the right nasolabial sulcus over the tumor. Note the absence of teeth from the upper jaw. No recurrence after operation.

If the bony wall is thin enough, it will yield to pressure of the palpating finger and cause a crackling sensation. A puncture of the swelling will settle the diagnosis of a cyst. Puncture yields a thin, glairy fluid, clear and rarely bloody, occasionally purulent.

The situation of these cysts is illustrated in Figs. 224 and 225, about the roots of the upper jaw. Such cysts, if allowed to grow, may depress the roof of the mouth or fill the antrum. (See Fig. 227.)

If the permanent teeth are normally erupted and a cyst is present, it is more than probable that it is a simple dental cyst associated with the root of a tooth.

The walls of these dental cysts are usually lined by granulation tissue, occasionally by epithelial cells.

These cysts should be completely removed if recurrence is to be avoided. The whole wall should be destroyed. It is usually sufficient to remove the anterior wall of the cyst completely, then, exposing the interior of the cyst, the lining (granulation tissue—epithelial tissue) should be thoroughly removed or completely destroyed by applica-

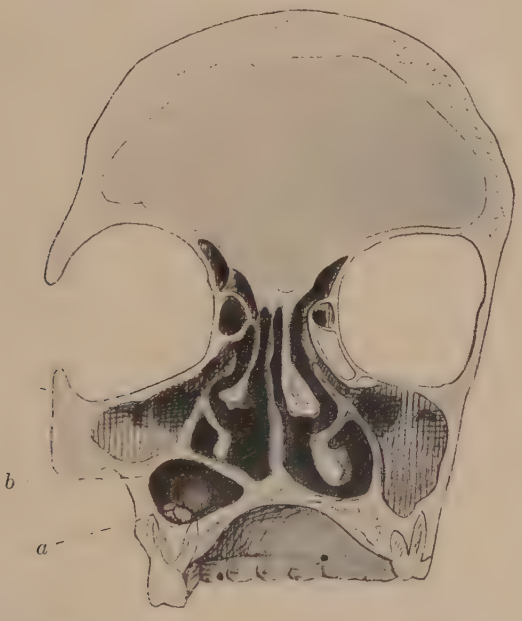


Fig. 221.—Dental cyst. Section, frontal, showing nasal fossa and relation of root-cyst to antrum and inferior meatus. *a*, Tooth in bottom of cyst; *b*, top of cyst next to antrum.

tion, upon small swabs, of strong carbolic acid. Recurrence has occurred when less thorough methods have been followed.

The cavity remaining after this destruction of the cyst should be packed with some antiseptic gauze. If the situation of the cyst is such, it may be possible to reflect the mucous membrane from off the cyst, and so to preserve

it that, after the cyst-wall is destroyed, the mucous membrane may be laid as a plastic flap over the cavity, and thus healing be hastened and facilitated.

### The Root-cysts

These are the most frequent forms of cysts. Of course, they are of comparatively little general surgical importance. They are mentioned here so that the subject may be understood in its proper relations.

Fig. 222.—A root-cyst of the upper jaw in connection with the first molar tooth. Note the very rounded surface of the tumor (Perthes).

Partsch, in two years, saw 200 cases of root-cyst and only 6 follicular cysts.

Root-cysts are almost never seen in connection with the milk-teeth. Root-cysts occur in the upper jaw more frequently than in the lower jaw.

They lie in connection with the incisor and bicuspid

teeth. They rest in a smooth bony cavity of the tooth alveolus. The wall of the cyst is made up of connective tissue lined with epithelial cells, like the cells of the enamel pulp.

The contents of the cyst are clear yellow fluid containing cholesterin crystals and cast-off epithelial cells.

There is frequently a secondary infection of the cyst

Fig. 223.—Root-cyst of left lower jaw in a nine-year-old girl (Perthes).

contents, due to the proximity of a carious tooth. The contents may be foul smelling if infected.

The root sometimes projects into the cyst cavity. (See Figs. 221, 224.) The cyst-wall may be calcified.

The origin of these root-cysts is from the root granulomata. The root granuloma is a small mass of granulation tissue attached intimately to the tooth-root. The periphery of the mass of granulation tissue is firmer than the center,

which contains many more cells than the periphery. Some of the central cells are giant-cells. There are at times found epithelial, cylindric and stellate cells, which are the analogue of the enamel organ. Malassez regards them as remains of the epithelial sheath of the enamel organ.

Fig. 224.—Note relation of cyst to antral floor and root of tooth (from Onodi): *sm*, Antrum; *c*, cyst; *m*, first molar tooth.

The root-cysts begin in the center of these granulomata. The normal epithelial cells in the center of these granulomata soften, break down, undergo fatty degeneration, and hence form the starting-point for the cyst. The primary occasion of the granuloma is a periodontitis. The sequence, then, of the pathology of the root-cysts is as follows: Some irritant causing a periodontitis; as a result of the peri-

odontitis a granuloma forms; this granuloma softens in the center, and the cyst results.

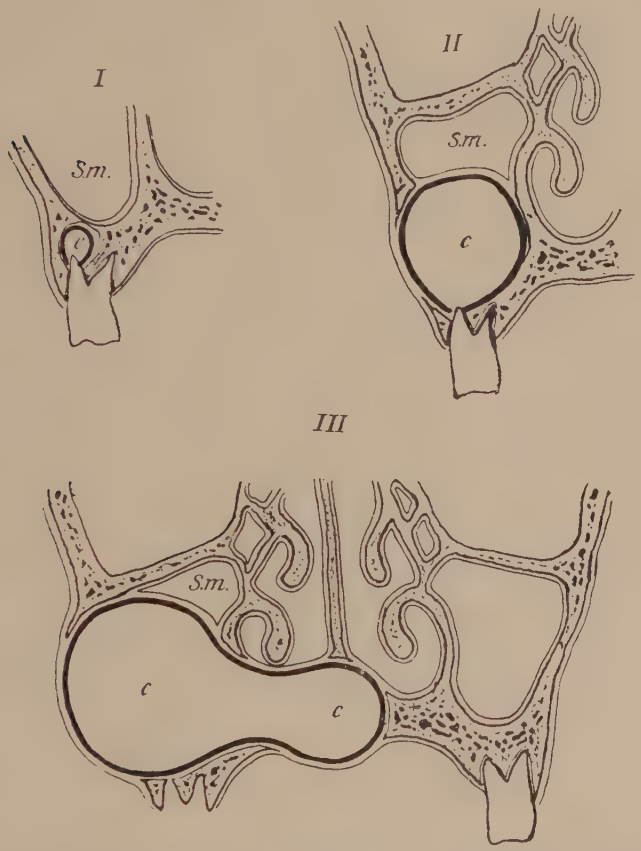


Fig. 225.—Diagram of three stages in the development of the root-cyst. Note the intimate relation in *I* of the root-cyst with the tooth-root; in *II*, the encroachment of the root-cyst upon the inferior wall of the antrum; in *III*, still greater encroachment of the root-cyst upon the antrum and also upon the hard palate and the nasal cavity. *S.m.*, Antrum; *c*, cyst (Perthes).

These root-cysts may grow in various directions. If they are in the lower jaw, they present in its outer side, under the mucous membrane. If they appear in the upper

jaw, growing in the direction of least resistance, they may appear in any of the cavities of the jaw or cavities of the face, growing into the antrum, mouth, or nose. When the cyst enlarges into the antrum, it is sometimes mistaken for hydrops of the antrum. (See Fig. 225.)

These cysts may grow to an enormous size. The ordinary size is that of a walnut.

Fig. 226.—Note the situation of a cyst at the tip of the root of a molar tooth: *sm*, Antrum; *c*, cyst; *pm*, root of tooth (from Onodi).

A root-cyst may discharge spontaneously into the nasal cavity. If the tooth at whose root it is situated be pulled, its contents willl be thus evacuated. If there is a periostitis of the jaw near by, it may become secondarily infected.

**Symptoms.**—Early, a root-cyst is symptomless. Later, when it attains some size, it may make its presence known

through bulging of the antral wall or a swelling of the alveolar process surrounding it or a bulging of the hard palate. The surface is smooth and bony. As the cyst increases in size its wall may, in being thinned, yield a parchment-like crackle to palpation. Fluctuation may be

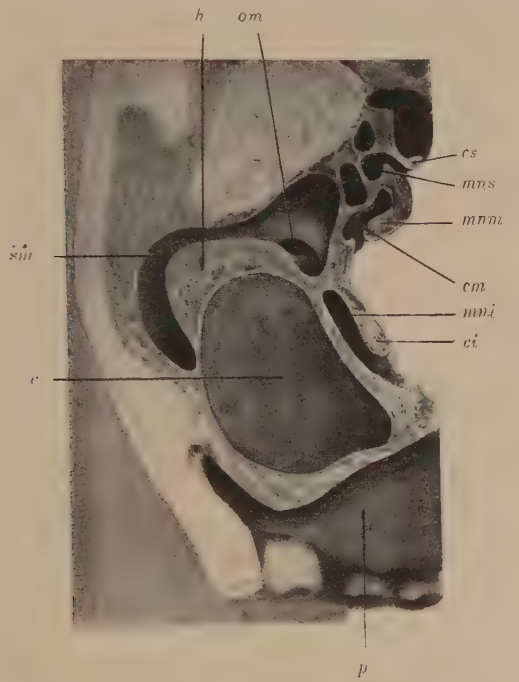


Fig. 227.—Note the cyst (*c*) depressing somewhat the roof of the mouth (*p*) and displacing upward the floor of the antrum (*h*). *ci*, Inferior turbinate; *mni*, inferior meatus; *cm*, middle meatus; *mnm*, middle turbinate; *sm*, antrum; *om*, opening to nasal cavity (from Onodi).

obtained from the hard palate to the outer wall of the tumor.

If the teeth are displaced to one side, one should have in mind the possibility of a root-cyst. An exploratory puncture may be wise. An *x*-ray, taken, as suggested by Perthes,

with a cork between the teeth, will be of much diagnostic assistance.

In **diagnosis** it will not be necessary to distinguish the root-cyst from a follicular or dentigerous cyst.

Central jaw tumors will be hard to differentiate.

An infected root-cyst will be difficult to distinguish

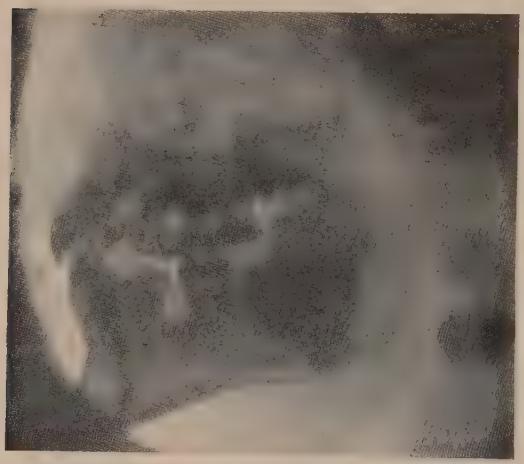

Fig. 228.—*X*-ray of a hard odontoma of the under jaw in a girl eleven years old, with an underlying molar tooth (Perthes).

Fig. 229.—*X*-ray of the tumor seen in Fig. 228 after it was removed, showing the dense tissue and the molar tooth (Perthes).

from a localized periostitis and osteitis of the alveolar border of the jaw.

In the upper jaw one will have to distinguish between a collection of fluid in the antrum and a tooth-cyst which has grown into the antrum; also between an empyema of the antrum and a suppurating tooth-cyst with perforation into the antrum. The floor of the nose is sometimes raised in cases of cyst, whereas in a simple empyema it is not raised.

**Treatment.**—Puncture of a root-cyst rarely effects a cure The Partsch operation of removal of a wall of the cyst so as

to lay the cavity of the cyst open into the mouth is most effective. The wall of the cyst that projects should be removed so as to make the part left level with the oral cavity.

If the cyst-wall is completely removed, there will be no recurrence. Recurrences occur when the cyst-wall is not entirely removed.

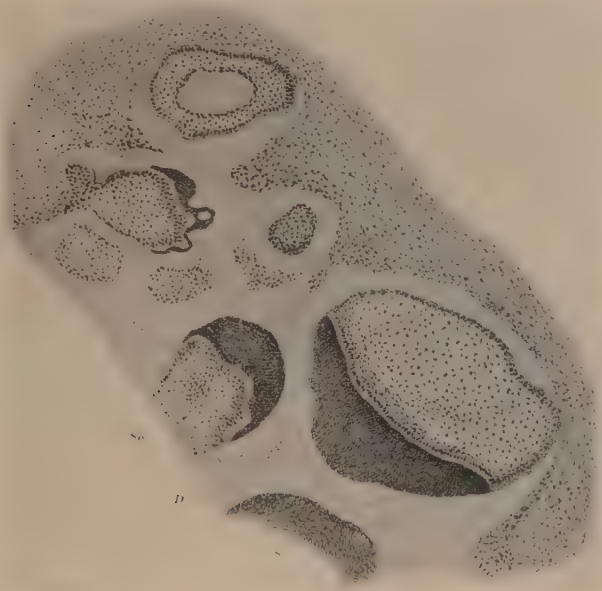

Fig. 230.—Section through the odontoma, of which the *x*-ray is seen in Figs. 228 and 229: *S*, Enamel; *D*, dentin; *Sp*, enamel pulp (Perthes).

Occasionally, it may be possible to reflect the mucous membrane from off the cyst, incise it, remove the wall and the lining, replace the reflected mucous membrane, and thus secure rapid healing. This result is impossible if the cyst is simply opened and packed with iodoform or other gauze.

Witzel's trial of paraffin filling for these cysts, and

Mosetig-Moorhof's plumbum of wax, have been found unsatisfactory.

### The Hard Odontomata

A tumor composed of tissue resembling in part a solid hard tooth occasionally occurs. It is an odontoma. If it contains more of one part of the tooth than another, it very properly might take the name of that tissue predominating, as a "cementoma."

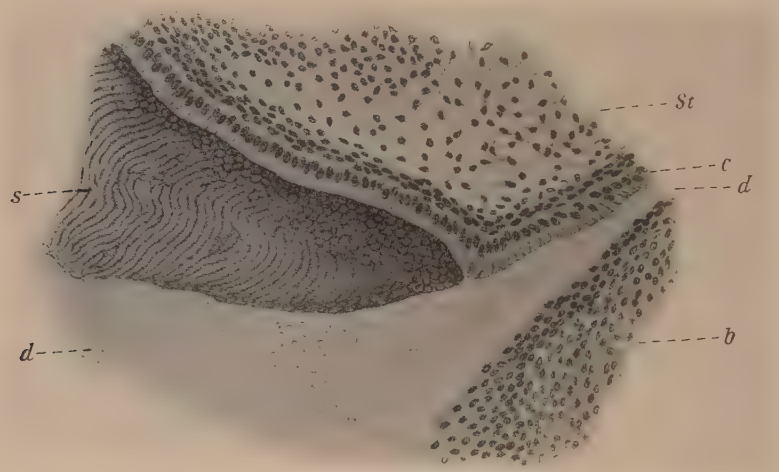


Fig. 231.—An enlarged view of Fig. 230: *s*, Enamel; *d*, *d*, dentin; *st*, stellate cells; *c*, cylindric cells of the enamel pulp; *b*, connective tissue (Perthes).

Thus the classification of these hard odontomata according to Bland-Sutton is literally correct, but it is difficult, without microscopic study, to arrive at a diagnosis. Practically, such refinement in diagnosis is of little value. One must remember simply that the small hard tumors similar to that shown in Fig. 228 are odontomata, and that they are most benign and are best treated by enucleation and complete removal.

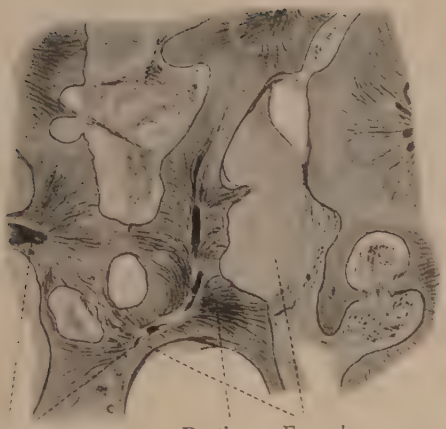



Section through one-half the tumor.

Opposite half of tumor.
Surface view.

Fig. 232.—Hard odontoma of the lower jaw with a displaced molar tooth. Showing the gross microscopic and *x*-ray appearances (Martens, König's Clinic, Berlin).

Fig. 233.—Hard odontoma. Note swelling of left cheek. Arrow points to tumor (A. T. Cabot, Massachusetts General Hospital series).

Fig. 234.—Hard odontoma. Note fullness of left cheek over tumor. Arrow points to tumor (A. T. Cabot, Massachusetts General Hospital series).

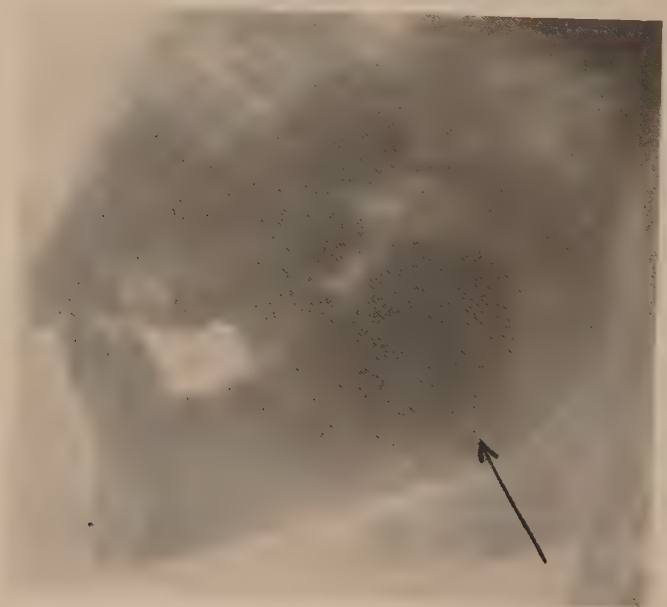

Fig. 235.—An *x*-ray of a hard odontoma. Note the odontoma at the point of the arrow. (See Figs. 233, 234.) (*X*-ray by Dodd.)

Instances of exostosis of the jaw may clinically be mistaken for the hard odontomata. Suppuration may occur around these adventitious masses of hard tissue, and clinically they may be mistaken for osteomyelitis of the jaw.

Fig. 236.—Microphotograph (Brown, Massachusetts General Hospital). An odontoma. (See Fig. 237 for appearances of area within circle.)

In the removal of this supposedly carious focus it will always be important to investigate with great care lest some hard odontoma be overlooked, and thus the source of the irritation not discovered.

**Case of Hard Odontoma.**—A. M. A young girl about eleven years old. Massachusetts General Hospital clinic.

General health always fair, although never robust

One month previous to operation she noticed a swelling of the left side of the lower jaw, as seen in the photograph (Fig. 233). This swelling was slightly tender. Three weeks previously a tooth was pulled upon this side, in the region of the swelling. Two weeks ago the swelling was lanced, and only blood was obtained. There has been no pain



Fig. 237.—Microphotograph of tumor, showing structure resembling tooth within circle in Fig. 236. An odontoma (Brown, Massachusetts General Hospital).

in the swelling, only tenderness to pressure. The tumor is as hard as bone; at one point it is slightly tender. The alveolar process is enlarged.

Operation through the gum and the mouth. Chiseling down to the tumor, a hard, ivory-like mass popped out from the jaw. The cavity from which this came was packed with gauze.

A year later a tooth appeared in front of, and at about the seat of, the tumor; these, being carious, were removed. The general health has been only fair.

The *x*-ray shows the situation and the size of the tumor. The microscopic section finds the tumor to be an odontoma, the tumor resembling in structure a tooth.

For some months after the operation in 1901 there was a swelling or thickening noticeable to palpation at the original seat of the tumor. This gradually disappeared. In July, 1907, six years after the operation, there is no trouble with the jaw, and excepting for carious teeth in both jaws, the girl, now seventeen years old, seems well.

## BIBLIOGRAPHY OF CYSTS IN CONNECTION WITH THE TEETH

Christopher Heath: Diseases of Jaws.
W. P. Bolles: Boston Med. and Surg. Jour., September 7, 1841.
Sir John Tomes: A System of Dental Surgery, 1887.
Heisler: Embryology.
Eve: Brit. Med. Jour., January 6, 1883.
Broca: Traite des Tumeurs, vol. ii, p. 35.
J. Bland Sutton: Correct Embryologic Classification, 1893.

# CHAPTER V

## CARCINOMA OF THE JAWS

CONTENTS OF CHAPTER: Frequency of carcinoma in the jaws.—Sex.—Decade.—Material for study.—Origin of carcinoma of the jaws.—Etiology.—Relation of nasal polypi.—Symptoms.—Metastases.—Diagnosis.—Course.—Treatment.—Results.

A summary of cured cases from certain groups of carcinomata of the upper jaw.—Twelve cases of carcinoma of the upper jaw operated upon at the Massachusetts General Hospital clinic.—Two cases of carcinoma of the upper jaw operated upon at the Massachusetts General Hospital clinic: Well today.—Certain inoperable carcinomata of the upper and lower jaws at the Massachusetts General Hospital clinic.—Cases of carcinoma of the lower jaw operated upon at the Massachusetts General Hospital clinic; Mortality of operation; Percentage of cures.—Carcinoma of the lower jaw at the Massachusetts General Hospital clinic; Cases dead soon after operation.—Certain cases of carcinoma of the lower jaw from the Massachusetts General Hospital clinic. Died from recurrence.—Carcinoma of the lower jaw operated upon at the Massachusetts General Hospital clinic. Six cases alive today.—The statistics of carcinomata of the upper and lower jaws from the Boston City Hospital clinic.—Meller's report of cases of carcinoma of the lower jaw.—The prognosis of carcinoma of the jaws.—Table of percentage mortality following total and partial resection of the jaws from various clinics.

**Frequency.**—Carcinoma is more frequent in the upper and lower jaws than sarcoma. About three cases of carcinoma occur to two of sarcoma. Taking the cases recorded from the clinics at Vienna, Göttingen, Prague, Berlin, Zürich, Würzburg, Erlangen, and Berlin recorded by Stein, there were of *upper* jaw carcinomata, 330 cases: sarcomata, 225 cases; of *lower* jaw carcinomata, 204 cases: sarcomata, 122 cases.

In the Massachusetts General Hospital clinic there were: Of *upper* jaw carcinoma, 16 cases; sarcoma, 15 cases; of *lower* jaw carcinoma, 27 cases; sarcoma, 16 cases.

**Sex.**—Carcinoma of the jaws occurs more frequently

among men than among women. In four general surgical clinics where accurate records were kept 204 men were affected and 78 women. Of the 40 cases of cancer of the lower jaw studied by Warren, Greenough, etc., from the

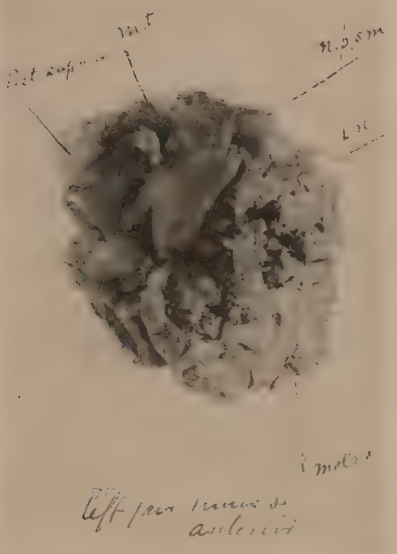

Fig. 238.—Carcinoma of upper jaw. Middle and superior turbinates not involved. Origin from antrum. The roof of the mouth was involved. *m.t.*, Middle turbinate; *n.p.s.m.*, nasal process of superior maxilla; *i.n.*, infra-orbital nerve (Warren Museum, No. 9736).



Fig. 239.—Carcinoma of upper jaw. Buccal mucosa uninvolved. Origin in the antrum: *n.p.s.m.*, Nasal process superior maxilla; *i.n.*, infra-orbital nerve; *i.ridge*, infra-orbital ridge (Warren Museum, No. 9736).

Massachusetts General Hospital clinic, 32 were males and 8 females—a ratio of 4 to 1.

**Decade.**—Carcinoma occurs definitely at a later period of life than either sarcoma or epulis. The cases occurring at different ages (decades) have been charted. The chart

is most striking. Carcinoma of the jaw is most commonly seen in the two decades between fifty and seventy.




Fig. 240.—Carcinoma of upper jaw starting in the antrum.




Fig. 241.—Same case as seen in Fig. 240.

Cases recorded by Birnbaum, Balzaroff, Martens, Stein, Behm, and Schmidt are here charted.

At the Massachusetts General Hospital clinic there were 44 cases of carcinoma of the jaws. It is this material which forms the basis of this chapter.

There were 16 cases of upper jaw carcinoma and 28 cases of lower jaw carcinoma. Of these 44 cases, 33 were males and 11 were females—a ratio of 3 to 1. Men are more liable to carcinoma of the jaw than women.

A TABLE BASED UPON 176 CASES OF CARCINOMA, 148 CASES OF SARCOMA, AND 167 CASES OF EPULIS OF THE JAWS

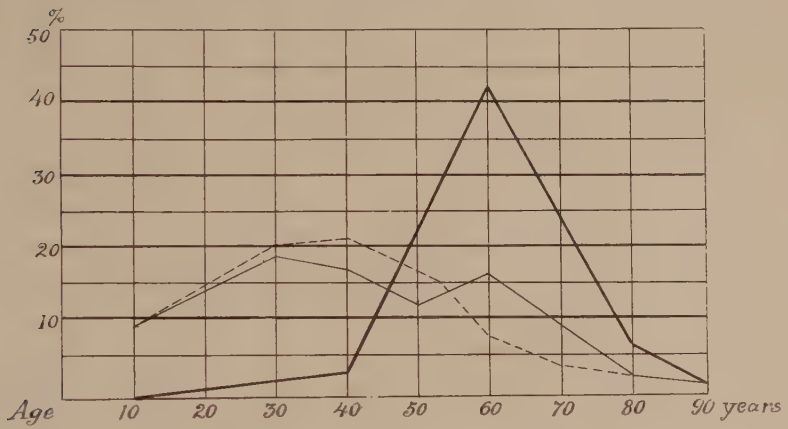


Fig. 242.—Heavy line, frequency of carcinoma at the different decades of life. Light line, frequency of sarcoma at the different decades of life. Dotted line, frequency of epulis at the different decades of life.

As the accompanying charts graphically show, the time of the maximum appearance of carcinoma is at a strikingly different decade from that at which sarcoma appears to grow. This curve, derived from the Massachusetts General Hospital clinic, is quite similar to that from other combined clinics. It demonstrates that the sarcoma time of growth is at an earlier age than the carcinoma time of growth. Carcinoma flourishes between forty and sixty

years,—in the middle and later period of life,—while sarcoma selects youth and middle life—from ten to fifty years—in which to develop.

CURVES SHOWING RELATIVE FREQUENCY OF CARCINOMA AND SARCOMA AT VARIOUS DECADES IN THE MASSACHUSETTS GENERAL HOSPITAL SERIES

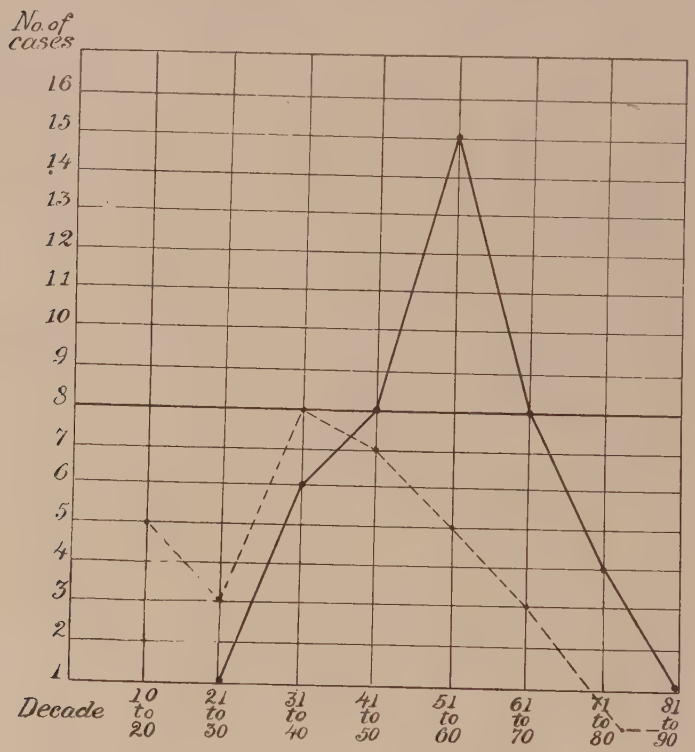


Fig. 243.—Dotted line, sarcomata of the jaws (upper and lower). Solid line, carcinomata of the jaws (upper and lower).

**Origin of Carcinoma of the Jaws.**—If we consider for clinical purposes the gums and the mucous membrane over the upper and lower jaw, alveolar surfaces, and palate as a

part of the jaw itself, then carcinoma may be said properly to be primary when it starts from these sources.

There is, of course, no carcinoma primary in the bone itself. All carcinomata of the jaw start in tissues outside the bone and invade the jaw secondarily.

The central carcinoma of the upper jaw starts usually in the mucous membrane of the antrum of Highmore. The

Fig. 244.—Carcinoma of the lower jaw. Note the involvement of the bone in the growth. Note the fracture of the jaw at the center of the growth (Warren Museum).

type of central carcinoma is usually the cylindric-cell form. Martens thinks that squamous-cell cancer may arise from the antrum. Killian suggests that the origin of carcinoma from the tooth-root alveoli is explicable on the basis of its starting from paradental epithelial rests, which are known to exist there.

The central carcinoma of the lower jaw, without in-

volvement of mucous membrane of the gum, is unknown. Carcinoma of the lower jaw always starts from the ulceration of the mucous membrane or contiguous parts, that is, of the cheek, salivary glands, face, neck, lip, or tongue.

The cancer of the upper jaw which is most common

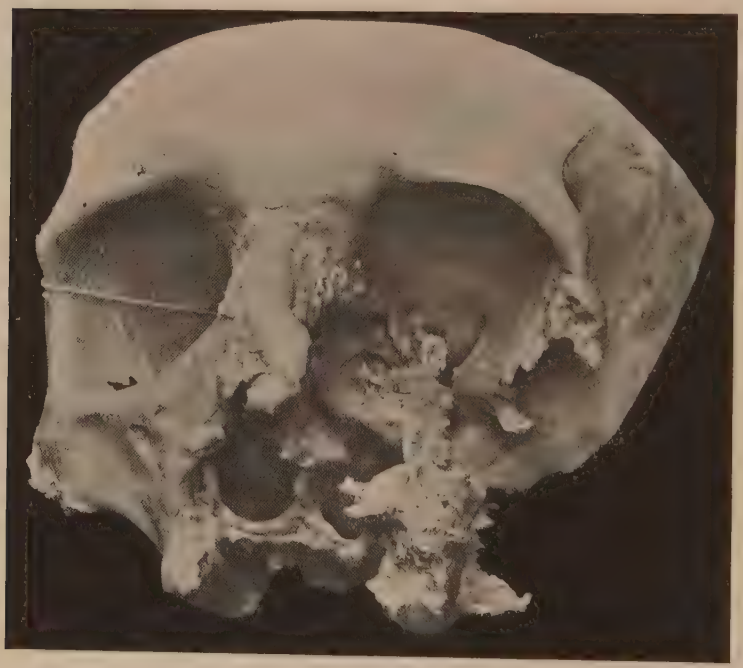

Fig. 245.—Man, sixty years old. Bones of face involved in the destructive advance of carcinoma (Army Medical Museum, Washington, D. C., No. 9780).

starts not centrally, but from the mucous membrane of the cheek and nose.

It is very unusual to find metastatic carcinoma in the jaws. Batzaroff, from the Zürich clinic, reports two cases in which, following carcinoma of the breast, carcinoma developed in the upper jaw in one case and in the lower jaw in

PLATE V

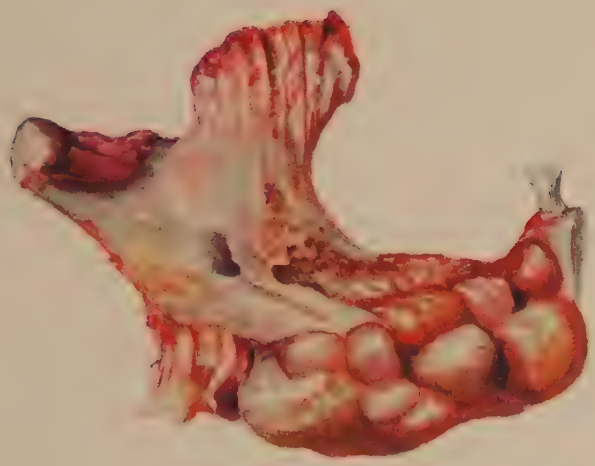

Lower jaw involved in the ulceration of carcinoma. Note the worm-eaten appearances of the bone. (Painting by Florence Byrnes.)

the other case. These metastases occurred one and three-quarter years after the breast was removed. There had been no recurrence in the breast.

Fig. 246.—Sarcoma of lower jaw, ossifying type. Woman, aged twenty-one years. Patient died two and one-half months after the appearance of the disease (Army Medical Museum, Washington, D. C., No. 5255).

Riedel records a case of metastasis of carcinoma of the thyroid to the lower jaw. This is a unique experience.

**Etiology.**—Little or nothing is known of the etiology of

carcinoma. Carcinoma of the jaws is often associated with some form of chronic irritation. That carcinoma in many parts of the body is antedated by some form of chronic irritation is coming to be more and more generally accepted as one fact of importance in the etiology. In many cases the smoking of a pipe for years is thought to have been the reason for the carcinoma appearing in an ulcer of the gum of the

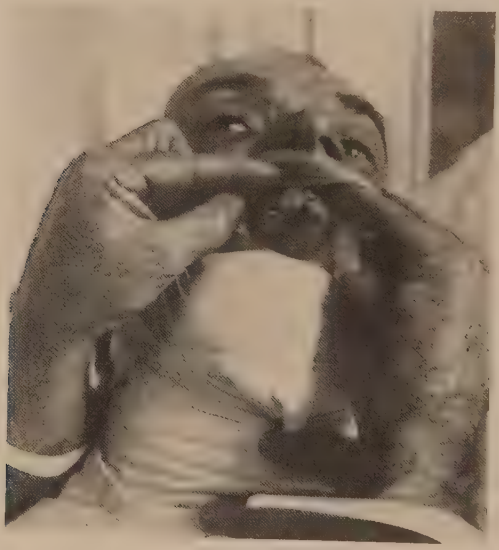

Fig. 247.—Case E. T., fifty-seven years old. Carcinoma of alveolar margin of upper maxilla. Partial resection after one year's duration (F. B. Harrington).

alveolar margin. The danger of local irritation continued over a long period of time is very greatly minimized popularly, and even among physicians.

Again, carcinoma sometimes follows in the sinus or edges of old fistulous tracts about the jaws. The base of a syphilitic ulcer may become cancerous.

At the Leipsic clinic a case was seen that was thought to be due to an implantation of cancer from a tongue to the jaw, from contact—a decubitus ulcer.

Cancer of the lower jaw is oftentimes secondary to cancer of the floor of the mouth, of the tongue, of the lip, of the parotid, and of the submaxillary region.

**Relation of Nasal Polypi to Carcinoma.**—It is not unusual to find a history of nasal polypi having been re-

Fig. 248.—Carcinoma of left upper jaw. Man, thirty-nine years old. Extensive ulcerations in nose (F. W. Dudley, Manila, P. I.).

moved, possibly several times removed, and that subsequently malignant disease of the nose and jaw appeared. The question of the relation of nasal polypi to malignant disease is yet undetermined. A nasal polypus ordinarily is an edematous tab of mucous membrane which is associated with some subacute inflammatory process. Theoretically, it would seem most likely that the malignant process is

primary, and the polypi are simply secondary to the malignancy.

Simultaneous involvement of both superior maxillæ with cancer is possible, but is rarely met.

In 1903 Darnell collected from the literature 79 primary carcinomata of the nasal fossæ and accessory cavities.

Trautman says, according to Maljutin, that the antrum is the commonest seat of beginning malignant growths,

Fig. 249.—Carcinoma of the alveolar arch and hard palate (after Perthés).

while von Donogany asserts that the middle turbinate must be awarded the first place as origin.

Neoplasms arising in the antrum may give rise to symptoms of empyema of the antrum. There is no distinctive symptom until the growth breaks through the bony wall, which, according to Schwenn, is proof of malignancy.

Carcinoma of the orbit arises from the lacrimal gland or the conjunctiva.

**Symptoms of Carcinoma of the Jaws.** –The anatomic position of the growth determines somewhat the character of the early symptoms, for, as a rule, these symptoms are manifestations of pressure. Therefore, if the new-growth extends without causing pressure, there may be no symptoms whatever until the involvement of the jaw has become

Fig. 250.—Carcinoma of the alveolar processes of the upper jaw. Note the ulceration on the left side (from Mikulicz's Atlas, 1892).

very extensive. Pain, deep seated and dull, or neuralgic in character, or like a toothache, usually in the bicuspid or molar tooth, may be considered as one of the earliest and most common symptoms of malignant disease of the maxilla starting in the alveolar process. Not infrequently this pain leads to the extraction of the painful tooth, of course without relief. Examination at the time of extraction may disclose

a pathologic condition of the alveolar process. Adjacent teeth are found loosened, and are usually subsequently extracted. If nothing positive is discovered, there may follow a daily discharge of a few drops of clear or sero-purulent fluid from the tooth-socket, and a little later a new-growth will be noticed invading the alveolar process from the tooth-socket.

Fig. 251.—Carcinoma of the right upper jaw (Trendelenburg).

The pain, from the nature of the pressure, may be located either in the ear, from obstruction of the Eustachian tube, or in the temporomaxillary articulation. The pulling of the teeth may attract attention to that particular part, and a mass or tumor be noticed exactly at the time the teeth are extracted.

Almost as early and common a symptom as pain is the bulging of the antral wall. If it is borne in mind that the antrum is a three-sided pyramid, bounded by the orbital,

zygomatic, and facial surfaces of the superior maxillary bone, with the outer wall of the nasal cavity as a base, it will readily be seen where this deformity, due to the bulging or breaking down of the walls, will be manifested.

That is, if the growth extends *anteriorly*, there will be noticed a bulging of the cheek; that side of the face is

Fig. 252.—Carcinoma of antrum, secondary to nasal polypi. White male, aged forty-one years. Nasal polypus; symptoms for seven months. Photograph taken one year after disease was detected. The patient died six months later (from original, loaned by Joseph C. Bloodgood).

broadened, and the nose is pushed toward the opposite side, or, in case of a rapid extension of the growth anteriorly, an ulcer of the cheek may appear, not associated with great pain, which, from its painless character, has been confused with syphilis and with a necrosis of bone due to an infection. (See Figs. 253, 255, 257.)

Extension *upward* may cause a disturbance of vision, due to such intra-orbital pressure as to cause an increased intra-ocular tension, or an actual extrusion of the eyeball may result. (See Fig. 251.) Fullness may also be noticed in the temporomaxillary fossa, and at times there is difficulty in mastication.

Fig. 253.—Carcinoma of the upper jaw; man, forty-one years old, thought to be necrosis of the bone of the superior maxilla because of a sinus in the cheek discharging bits of bone. Note the pallor, swelling of right cheek, obliteration of the right superior nasolabial fold.

Extension toward the base of the pyramid will cause obstruction of the nasal cavity, and this plugging of the nares is perhaps even a more frequent symptom than either pain or evident bulging of the antral walls outward. One-sided nasal obstruction, associated with the discharge of

Fig. 254.—Man, seventy years old. Rodent ulcer which had existed seven years, destroying nearly one-half of the face (Kaposi).

Fig. 255.—Ulcerating carcinoma of the upper jaw (Schlatter).

bloody fluid and combined with pain of a neuralgic character or a feeling of fullness in the antrum, is a most suggestive combination of symptoms. A growth may protrude from the nostril, and if not from the nostril, from some accessory sinus, into the inferior or middle meatus. Repeated slight hemorrhages from the nose occur.

Fig. 256.—Mrs. A. Carcinoma of the upper jaw.

Obstruction of the tear-duct and edema of the lower lid are additional signs which often result from this involvement of the wall of the antrum.

In times past the involvement or non-involvement of the adjacent lymphatics was often emphasized, and considered in the differential diagnosis between benign and malignant growths of the upper jaw. The more recent observations,

particularly those of Martens, which have been corroborated by Butlin, show that lymphatic involvement with malignant disease in this location is a very late rather than an early manifestation.

Ulcerations within the mouth, while they may commonly be benign in nature or associated with a specific infection,

Fig. 257.—Mrs. A. Carcinoma of the upper jaw. Note the ulcerating mass.

are to be considered as danger-signals and examined at the earliest possible moment. Ulcers of the gum which involve the bone subsequently are in the early stages amenable to treatment by complete local excision with a wide margin of sound bony tissue.

Many times carcinoma of the jaw, particularly of the

upper jaw, begins as a superficial ulcer of the skin of the face. An ulcer with this origin increases gradually, but it increases, nevertheless. Such an ulcer may be mistaken for necrosis of the jaw. There is usually little pain associated with this growth, as it invades the bone from the cheek.

**Metastases.**—Cancer of the lower jaw forms metastases more often and earlier than cancer of the upper jaw. The

Fig. 258.—Mrs. A. Carcinoma of the upper jaw, starting in the antrum of Highmore. Note that the inferior turbinate bone is uninvolved in the disease. Complete excision of the upper jaw was done, together with removal of the contents of the orbit. Recurrence. Death. (See Fig. 256.)

submaxillary and deep cervical glands may be invaded by growths in either upper or lower jaws. The parotid lymphatic glands are usually invaded from the upper-jaw growths. The submental glands are invaded by lower-jaw growths. Cancer of the upper jaw gives glandular metastases late.

**Diagnosis.**—Inflammatory disturbances in the antrum of Highmore may be associated with carcinoma of that part.

The ulcerations upon the gums or alveolar borders which may be mistaken for carcinoma are the ulcerations of tuberculosis, actinomycosis, and tertiary syphilis.

**Course.**—The course of carcinoma of the jaws is a rapid one. As cases present themselves to the surgeon they often are inoperable, even from a palliative standpoint. Death usually ensues within two years after the appearance of the disease.

Fig. 259.—Carcinoma at symphysis of the lower jaw. Woman, forty-five years old (F. W. Dudley, Manila, P. I.).

**Treatment.**—If the disease is well advanced, a total excision of the upper jaw, together with a thorough search through the various sinuses accessory to the nasal cavity, is indicated. Partial excision may be more safely tried for localized carcinoma of the upper jaw than of the lower jaw.

There is greater risk of recurrence in doing a partial operation upon the lower jaw than there is from partial operation upon the upper jaw. In a very early carcinoma of the alveolar process of the upper jaw a partial operation may be wise.

A partial operation on the lower jaw is attended with great risk of incomplete removal. An exarticulation or resection in continuity of the lower jaw is the wisest procedure if the carcinoma is well developed.

**Results.**—The results of treatment of the upper jaw carcinomata in general are disappointing. The returns are made, in the cases collected by Martens, upon the basis of a three-year immunity.

*Martens* collects 49 cases from the literature (recorded by Ohlemann, Küster, Birnbaum, Braun, von Winiwarter, Batzaroff, and von Petzold), of which only 2 are well. Both of these cases were from the Zürich clinic, and had been

Fig. 260.—Carcinoma of symphysis. Extensive ulceration in floor of mouth. Foul odor. Woman, forty-five years old (see Fig. 259) (F. W. Dudley, Manila, P. I.).

operated upon by von Krönlein. One died five years eight months, the other died seven years two months, following operation, without recurrence.

In the statistics of *von Stein*, recording the cases of the Berlin clinic for the years 1890 to 1900, there were 13 cases followed. No one of these cases was alive. Ten died of recurrence in from three to nine months following operation.

*Fuchs* reports from the Breslau clinic 23 cases of carcinoma of the upper jaw during the years 1891 to 1901. None was free from recurrence three years after operation.

Martens reports *König's* experience at the Göttingen clinic: of 48 total upper jaw resections, 29 survived the operation. There were 19 operative deaths—39 per cent. Eight cases were found free from recurrence after three years had passed since the operation.



Fig. 261.—Carcinoma of left lower jaw. Ulcerating mass in mouth. Woman, forty-four years old (F. W. Dudley, Manila, P. I.).

Nine partial operations were done. Six died of recurrence. Three cases were very recently operated upon. These 8 cured cases of cancer of the upper jaw remained cured respectively five years two months, seven years six months, nine years nine months, twelve years one month, ten years three and one-half months, and eighteen years three months, after operation. A later report of these 8 cases shows that 2 have died of some other ailment, leaving 6 now living. Taking both the upper and lower jaw, there were 21 deaths from recurrence of the disease.

Martens records one case of partial resection of the upper jaw for carcinoma well five years and nine months following operation.

The *Gussenbauer* clinic records the following: 32 cases of carcinoma of the upper jaw: 29 cases have been followed

subsequent to operation; 3 have had 1 recurrent operation; 2 have had 2 recurrent operations; 8 died of recurrence from four to eleven and one-half months after the primary operation; 16 died of recurrence from two and one-half to thirty-six months after the primary operation; 3 died without recurrence, of some other disease, three years four and one-half

Fig. 262.—Carcinoma of the lower jaw. Early recurrence in cicatrix after attempted removal.

Fig. 263.—Carcinoma of the lower jaw. Illustrating a badly placed incision from the angle of the jaw.

months to three years six months after operation; 2 are well and living since operation —one five years, and the other over one and one-half years since operation. The average time of death after operation was fourteen months.

Unoperated cases of cancer, that is, inoperable carcinomata, live, after being seen by the surgeon, about ten months.

## A Summary of Cases From Certain Groups of Carcinomata of the Upper Jaw

*Occurrence at the Massachusetts General Hospital Clinic.*—Twelve cases were operated upon: 2 cases are well, each seven years after operation.

*Occurrence at the Zürich Clinic* (*Krönlein*).—Two cases well, 1 died five years eight months after operation, and 1 died seven years two months after operation.

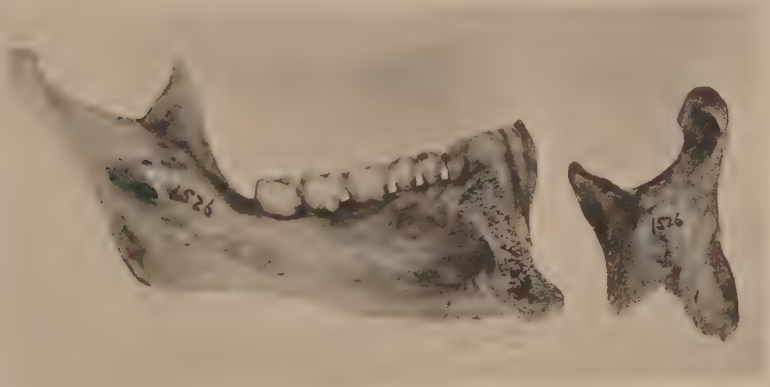


Fig. 264.—The remains of the lower jaw undestroyed by primary cancer of the lower lip. The lip was removed. Recurrence in lower jaw; bone destroyed; fatal hemorrhage (specimen from Warren Museum, No. 1526).

*Reported by von Stein*, 1890–1900 (*Berlin*).—Thirteen cases: all are dead.

*Reported by Fuchs* (*Breslau*), 1891–1901.—Twenty-three cases: none are without recurrence after a three-year period.

*Reported by König* (*Göttingen*).—Forty-eight cases: 8 cases are well after three years, *i. e.*, 17 per cent. of the cases were "cured."

The time which has elapsed since operation in the 8 cases operated upon by König is as follows:

1. 5 yrs. 2 mos.
2. 7 yrs. 6 mos.
3. 9 yrs. 7 mos.
4. 9 yrs. 7 mos.
5. 9 yrs. 9 mos.
6. 12 yrs. 1 mo.
7. 10 yrs. 3½ mos.
8. 18 yrs. 3 mos.

A microscopic examination was made in each of these cases of König, and the reports are as follows:

1. Alveolar adenocarcinoma.
2. Squamous-cell carcinoma.
3. Squamous-cell carcinoma.
4. Epithelial tumor with alveolar structure.
5. Adenocarcinoma with alveolar structure.
6. Adenocarcinoma with alveolar structure.
7. Squamous-cell carcinoma.
8. Squamous-cell carcinoma.

*Reported by Gussenbauer.*—Thirty-two cases have been followed to date: 2 are well—1 five years after operation and 1 one and one-half years after operation.

This makes a total from these different clinics of 177 cases of carcinoma of the upper jaws operated upon. Thirteen of these cases remained well for three years and over following operation. This is equivalent to 7.5 per cent. of "cures."

Twelve cases of carcinoma of the *upper* jaw were operated upon at the Massachusetts General Hospital clinic: 1 case was not traced; 9 cases have been traced and all have died. There were no deaths from operation in this series. Two cases are well today.

TIME OF DEATH FOLLOWING OPERATION FOR CARCINOMA OF THE UPPER JAW AT THE MASSACHUSETTS GENERAL HOSPITAL CLINIC

12. R. E. Died one year and three months after operation.

19. M. H. Complete excision. Died one year two and one-half months after operation.

22. L. P. Complete excision with enucleation of eye. Died four years and six months after operation.

24. H. W. Complete operation. Died six and one-half months after operation.

Fig. 265.—Inoperable carcinoma of the jaw. Note the extensive ulceration of the soft parts and bone (Massachusetts General Hospital, out-patient clinic).

26. W. P. Died three months after operation.

27. M. B. Complete operation. Died five months after operation.

39. S. H. Complete upper jaw resection and partial lower jaw resection. Died one year and three months after operation.

43. M. S. Complete operation. Died six and one-half months after operation.

44. O. E. Complete operation. Died ten and one-half months after operation.

## Two Cases of Carcinoma of the Upper Jaw Operated Upon at the Massachusetts General Hospital Clinic: Well Today

25. W. M. Forty-one years old. Thirteen years previously a small growth appeared below the left eye. Two years ago this growth rapidly increased in size. It was

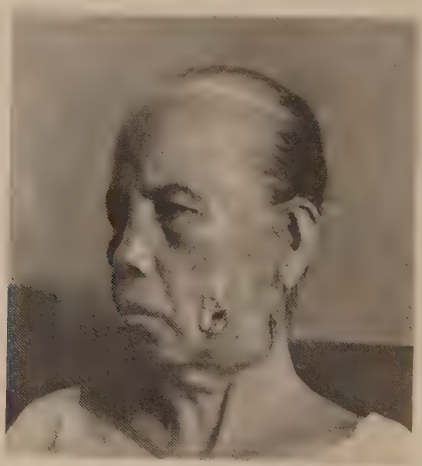

Fig. 266.—Carcinoma of left lower jaw. Woman, fifty-five years old. Late ulcerations (F. W. Dudley, Manila, P. I.).

cureted. It was thought to be associated with a necrosis of the jaw. When the man presented himself for operation there was a hard mass, the size of a silver dollar, beneath the left eye, pushing up the lower lid. The eye was half closed. This mass was ulcerated. Operation by S. J. Mixter. An excision of the mass, together with a portion of the malar bone and the floor of the orbit. Microscopic examination showed an infiltrating carcinoma. This man was alive and well seven years after operation.

28. R. J. B. Sixty-six years old. Eight weeks ago he complained of pain in the left ear, eye, and the side of the head. Six weeks ago a tumor began to form in the region of the left cheek. Four weeks ago this tumor appeared in the roof of the mouth and kept him awake on account of pain. Examination discloses a firm, elastic tumor on the left cheek, pushing the nose to the right, projecting into the mouth, extending into the left nostril, pushing the septum to the right. Operation was done by Dr. J. W. Elliot. Complete removal of the upper jaw. The antrum, the left nostril, and the ethmoid cells were involved in the growth. Microscopic examination was an alveolar carcinoma. Seven years after operation this patient was alive and well.

## Certain Inoperable Carcinomata of the Upper and Lower Jaws at the Massachusetts General Hospital Clinic

1. J. M. Sixty-eight years old. Male. Left lower alveolar border, bicuspid to molar, ulcerating, stinking mass. Submaxillary glands enlarged. Duration, three months. Lived two years seven months after operation was refused.

2. M. G. Sixty-three years old. Female. Left lower alveolar border, second bicuspid to the ascending ramus, involving left tonsil and side of the tongue. Duration, six months. Lived four months after operation was refused.

3. C. W. Fifty years old. Male. Right cheek, mucous membrane, superior and inferior alveolar borders, hard and soft palates involved. No distinct glands felt in the neck. Duration, ten and one-half months. Lived six months after operation was refused.

4. E. K. Forty-three years old. Female. Upper right alveolar process ulceration of gum and anterior pillar involved. Enlarged cervical glands. Duration, twelve months. Lived eleven months after operation was refused.

5. P. H. Seventy-five years old. Female. Left nasal

cavity. Nostril blocked. Polypi removed. Bleeding. Neuralgia in ear and head. Duration, several years. Lived four and one-half months after operation was refused.

6. S. D. Thirty-nine years old. Male. Ulcerated tooth, loosened, was extracted. Right upper molar and bicuspids involved, across hard palate to incisors. Duration, seven months. Lived a few months after operation was refused.



Fig. 267.—Carcinoma of the lower jaw on the left side. Note external swelling. Note mass, just faintly visible, appearing in mouth between lips. Note edema and infiltration of the cheek; also fullness in submaxillary region. Not operated upon (Massachusetts General Hospital, out-patient clinic).

7. G. N. Forty years old. Male. Lower lip and submaxillary tumor, right side, size of an orange. Painless. Duration, five and one-half months. Partial resection done of lower jaw. Six months later recurrence involving pharynx, considered inoperable. Lived six months after operation was refused.

8. E. L. Eighty-seven years old. Female. Tumor size of an orange bulging palate and involving the fauces.

Duration, two months. Lived three and three-quarter months after operation was refused.

9. J. M. Sixty years old. Male. For eight months had had an ulcer in the left cheek under the eye. Six months ago the upper jaw became involved. Glands existed behind the ramus of the jaw, and the cervical glands were enlarged

Fig. 268.—Same as Fig. 267. Note mouth opened, exposing to view characteristic carcinoma of the lower alveolar border. Cauliflower-like appearance seen.

in the left side. Operation was refused. He died two months later.

10. K. N. Forty-two years old. Female. Large tumor size of orange in cheek, involving nose and palate. Duration, four months. Lived eleven months after operation was refused.

11. A. G. Fifty-three years old. Female. Swelling under right eye involving inner canthus, nose, and malar

region; ulcerated; palate and nose invaded. Duration, two months. Lived nine months after operation was refused.

The *average duration of life* of these cases of inoperable carcinoma of the jaws after being seen by the surgeon is ten months.

Fig. 269.—P. M. Man, sixty years old. Tumor, ten months old. Tumor involves the inside of cheek, parotid, and beginning to involve the jaw. Inoperable carcinoma.



Fig. 270.—P. M. Man, sixty years old. (See Fig. 269.) Inoperable carcinoma.

### Carcinoma of the Jaw Operated on at the Clinic of the Massachusetts General Hospital

Of the 38 cases of carcinoma of the jaws operated upon, there were 12 cases of the upper jaw, 26 cases of the lower jaw. One case of this group had the disease in both upper

and lower jaws, and 1 of the lower jaw cases was a case with recurrence.

Of these 38 cases of carcinoma of the jaws, 4 were not heard from after careful search. The following is a report of these 4 cases:

1 (No. 23): Local disease was removed from alveolar border and cheek. Epidermoid carcinoma. Most likely to have recurred. Operation in 1896 (upper jaw).



Fig. 271.—H. W. Carcinoma of the right lower jaw.

2 (No. 34): Partial operation, excision of the disease. Neck not dissected. Had existed four months. Epidermoid carcinoma (lower jaw).

3 (No. 35): Complete left half lower jaw removed. Common carotid ligated. Internal jugular removed to

jugular foramen. Neck dissected. Epidermoid carcinoma (lower jaw).

4 (No. 36): Resection of one-half the lower jaw. Dissection of the neck. In bad condition. Probably recurred (lower jaw).

Fig. 272.—H. W. Carcinoma of the lower jaw. Long duration. Note the involvement of the lower jaw, as indicated by irregular outline.

### Carcinoma of the Lower Jaw. Operated Cases. Massachusetts General Hospital Clinic. Percentage of Cures

Twenty-six cases of carcinoma of the lower jaw were operated upon at the Massachusetts General Hospital clinic: 3 cases were not traced. There were 4 deaths from

operation—a mortality of 15 per cent. There are 5 cases well today, or 19.2 per cent. of all operated cases. If the percentage of cures is reckoned out from the traced cases, it amounts to 21.7 per cent. Twenty-three cases were traced and found to have died at varying intervals after operation.

### Carcinoma of the Lower Jaw. Cases Dead Soon After the Operation

Four deaths occurred because of the operation for carcinoma of the lower jaw:

Fig. 273.—After removal of one-half of the lower jaw for carcinoma. Patient lived five months after operation.



Fig. 274.—After removal of one-half of the lower jaw for carcinoma.

1. A woman, seventy-one years old. A complete removal of one-half of the lower jaw. Died of shock a few hours after operation.

2. A man, thirty-eight years old. An alcoholic. Died

of shock after removal of one-half of the lower jaw three days following operation.

13. A man, fifty-nine years old. Following an excision of the greater part of half of the lower jaw and dissection of the glands of the neck, died of exhaustion eight days after the operation.

37. A man, fifty-eight years old, having a large ulcerating mass in the midline of the neck and attached to the left lower jaw. Died after an excision of one-half of the lower jaw a few days after operation, evidently of shock and exhaustion.

### Certain Cases of Carcinoma of the Lower Jaw Dead From Recurrence

Ten of the 23 traced cases of carcinoma of the lower jaw operated upon have died with recurrence of the disease. The following facts in this series of cases are of very great interest. Note the duration of life after operation in these cases.

3. J. A. Forty years old. Removal of one-half of lower jaw, together with the zygoma and the parotid. The external carotid was ligated, also the jugular vein. Second operation two years following first, for recurrence. One year and eight months following the second operation an inoperable recurrence was present. Death from carcinoma four years following first operation.

5. M. D. Sixty-three years old. Duration of disease previous to operation, sixteen months. An ulcerating mass involving floor of mouth and the lower jaw. Removal of the symphysis and the floor of the mouth. Death one year and five months after operation.

8. C. D. Twenty-six years old. Six years ago had an ulcer of the lower lip. Five years ago the old-time V-excision of the ulcer of the lip was done. Two years later a recurrence in the lower lip occurred. The whole lip was

then removed. For the past six months there has been a recurrence in the lip and lower jaw. The present mouth will admit only one finger. The symphysis was removed; the disease was too extensive in the floor of the mouth for complete excision. The patient died five months after this last operation.

Fig. 275.—Carcinoma of lower jaw.

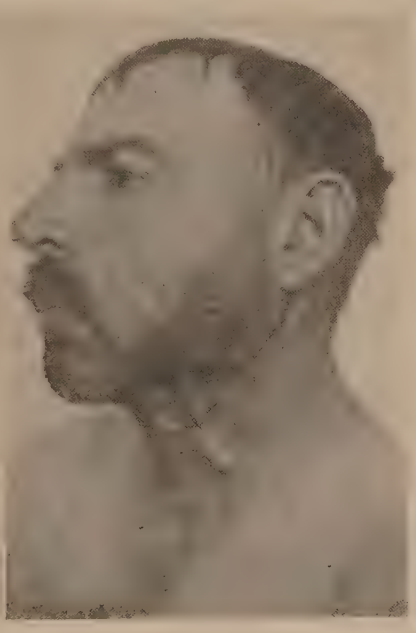

Fig. 276.—After removal of carcinoma of lower jaw.

11. J. M. Fifty-eight years old. For four months following an abscess about a tooth-root there has been an ulcerating mass in the mouth, involving the floor of the mouth and the lower jaw. One-half the lower jaw was removed. The neck was not dissected. Death occurred a few months after this operation.

13. D. W. R. Fifty-nine years old. For five months there has been a mass involving one-half the lower jaw.

Excision of one-half the lower jaw was done. The neck was dissected. Death occurred one year following this operation.

14. P. D. Sixty years old. Following trouble with two teeth, an abscess and involvement of the bone occurred, with what was thought to be a necrosis of bone. One year previous to operation an incomplete removal of one-half of the lower jaw was done. Death followed one year after this operation.

Fig. 277.—Carcinoma of lower jaw. Partial operation, excision of growth. Alive seven years after operation. Photograph taken seven years after operation (Case No. 10, Massachusetts General Hospital series, Richardson).

15. J. R. Seventy-five years old. Several years ago had an operation for necrosis of the jaw. Evidently a part of the jaw was removed. Some two months previous to operation a tumor appeared near the symphysis. This tumor was removed. Patient died seven months later.

16. J. T. Fifty-two years old. A tumor of the lower jaw extending to the neck had existed for a few months pre-

vious to operation. One-half of the lower jaw was excised. Death followed three and a half months after operation.

17. P. B. Fifty-three years old. Two months previously, after the extraction of a tooth from the lower jaw, a large swelling appeared, extending into the neck. Many enlarged glands of the neck were present. Removal of the lower jaw, ligation of the common carotid and the jugular vein, and thorough dissection of the neck done. Death followed a few months later.

37. W. H. F. Fifty-eight years old.[2] A few weeks previous to operation there was an ulcerating tumor within the mouth. Excised one-half of lower jaw. Died some days after operation.

The recurrence in these cases has often been a local one.

### Carcinoma of the Lower Jaw Operated Upon at the Massachusetts General Hospital Clinic. Cases Alive Today

Of 6 cases of carcinoma of the lower jaw operated upon, all recovered from the operation, and 5 of them are alive today; 1 case lived five years six months and died of angina pectoris.

10. E. G. Forty-five years old. Three months previous to operation an ulcer appeared in the gum of the lower jaw on the left side. This ulcer presented indurated edges. The ulcer, together with the underlying bone, was removed by M. H. Richardson. The microscopic diagnosis was an epidermoid cancer. This woman was alive and well seven years after the operation. (See Fig. 277.)

31. M. P. Forty-five years old. For sixteen years this woman has worn plates of false teeth. The gum over the lower jaw has been irritated. She has been thought at times to have had, in connection with the roots of carious teeth, caries of the bone. On the right side of the lower jaw

is a hard mass, which has been present about ten months, attached to the jaw and extending below it. Inside the mouth there is a small ulcer. Operation; mass resected by R. B. Greenough. Glands in the neck dissected. Microscopic examination proved this to be an epidermoid cancer. This woman is alive and well seven years after operation.

32. W. H. D. Forty years old. For four and a half months previous to operation patient has had a dull ache and a soreness in the right lower jaw, resembling a grumbling toothache. Two months previous to operation an ulcer of

Fig. 278.—Carcinoma of right lower jaw. Photograph taken four years following operation of removal of lower jaw, tonsil, and glands of the right neck (No. 32, Massachusetts General Hospital series, author's case).

the mucous membrane appeared over the alveolar process of the lower jaw. The glands in the neck were enlarged. For a month and a half previous to operation he was unable to chew solid food. He has lost 20 pounds in weight in four months. Upon the right side of the jaw there is a mass behind the molar teeth, which has ulcerated into the mouth and which involves the soft palate, pillars, and the tonsil. One-half of the lower jaw was resected, together with the tonsil on the right side, the soft palate, and glands of the neck, by C. L. Scudder. Microscopic examination

showed the growth to be a squamous-cell epithelioma. The lymphatic glands showed nothing unusual. This man was alive and well five years following operation. (See Fig. 278.)

38. W. H. F. Seventy-six years old. Three months previous to operation he had his teeth pulled. A mass appeared

Fig. 279.—Complete resection of left half of the lower jaw for carcinoma. No recurrence after five years. Photograph taken four years after operation (No. 38, Massachusetts General Hospital series, Conant).

on the left side of the lower jaw, in the region occupied by the extracted teeth. An operation of resection of one-half of the lower jaw was done by W. M. Conant. Microscopic examination showed an epithelioma infiltrating the alveolus. This man is alive and well today, over five years and a half following operation. (See Fig. 279.)

48. L. Fifty-nine years old. Six months previous to operation there existed an ulceration of the left cheek and lower jaw into the mouth. Excision of one-half of the lower jaw, with dissection of the neck, by C. L. Scudder. Pathologic report was a squamous-cell carcinoma. This man returned with a persistent sinus in the scar. This sinus was



Fig. 280.—Carcinoma of lower jaw (squamous cell). Photograph taken over two years following the operation (No. 48, Massachusetts General Hospital series, author's case).

excised about a month after the previous operation, and the pathologic report was a fibroma. The wound broke down a second time and was cureted and then closed. The wound broke down a third time, and the patient refused further treatment. The patient is today alive and well, two and a half years after the first operation. (See Fig. 280.)

49. C. V. An adult. A tumor of the lower jaw. At operation a partial excision of the jaw was done, without dissection of the neck, by M. H. Richardson. Microscopic report was a papillary epidermoid carcinoma. This man was alive and well five years and six months after operation. He then died of angina pectoris.

Of these recoveries from operation, 3 had had dissection of the glands of the neck, and 3 had no glandular dissection.

The **Boston City Hospital statistics,** studied by Lothrop and Scannell, are as follows for—

*Carcinoma* of the *lower jaw,* a total of 13 cases. The duration of the symptoms before consulting a surgeon varied, but averaged seven and a half months.

Two cases were living—one, five years after operation, one one and a half years after operation.

There were 6 complete excisions. The average duration of life after operation was sixteen and a half months.

There were 7 partial excisions. The average duration of life after operation was seven months.

The operated cases lived four times as long as the non-operated cases. Those having a complete excision lived longer than those with partial excision.

There were 9 cases of *upper-jaw* excision. All had died. Complete excision, 5 cases. Partial excision, 3 cases. Complete excision cases lived twelve months (average); the partial excision cases lived five months (average). The complete excision cases lived longest.

*Meller* reports that of 8 cases involving the lower jaw and necessitating complete removal of one-half of the jaw he found 2 cures, as follows:

One case, fifty-three years old. The angle of the jaw and the submaxillary glands were involved. The patient was alive six years and three months subsequently without recurrence. One case, fifty-eight years old. The disease was about the same in extent as in the preceding case. One-half the jaw was removed, and there was made a dissection

Fig. 281.—Carcinoma of the upper jaw, man, thirty-eight years old. Originated probably in the antrum. Note the fullness of the cheek and the displacement of the eyeball upward; also the deformity of the right ala of the nostril (Morestin).

of the neck. This case was alive three years and one month subsequently.

The **prognosis** of carcinoma of the jaw is far more unfavorable than that of sarcoma of the jaw.

Martens gives the average time of recurrence of carcinoma of the jaw as nine to ten months after operation. Stein, in 10 cases, finds the average time of recurrence 3.6 months, and death in eleven months. Behm records one

case which showed a recurrence eleven years after operation.

Perthes had one case in which he did a partial resection of the lower jaw for carcinoma. Three years later there was a recurrence. The patient had nothing done for two years, and then five years after the first operation a complete exarticulation was done. This illustrates how late the recurrence after operation may be. It is hardly wise to consider a case cured after having had an operation for carcinoma. The patient is to be congratulated so long as no recurrence appears.

RESECTIONS OF THE UPPER JAW—STATISTICS COLLECTED FROM THE LITERATURE BY DR. EMILIO COMISSO

| Author. | Time and Clinic. | Total Resection. | | | Partial Resection. | | | Total. | | |
|---|---|---|---|---|---|---|---|---|---|---|
| | | No. | Deaths Per Cent. | | No. | Deaths Per Cent. | | No. | Deaths Per Cent. | |
| Rabe | 1827–1873 | 277 | 74 | | 152 | 18 | | 429 | 92 | |
| Hofmokl | 1852–1870 Vienna | | | | | | | 43 | 8 | |
| Ohlemann | 1856–1874 Göttingen | 20 | 3 | 25.2 | 12 | 0 | 1.1 | 32 | 3 | 20.6 |
| Krönlein | 1868–1873 Zürich | 9 | 0 | | | | | 9 | 0 | |
| Winiwarter | 1868–1875 Vienna | | | | | | | 10 | 5 | |
| Küster | 1871–1887 Vienna | 29 | 8 | | 8 | 0 | | 37 | 8 | |
| Bayer | 1873–1883 Prague | 17 | 1 | | 2 | 0 | | 19 | 1 | |
| Beckmann | 1878–1885 Würzburg | 9 | 0 | 20.3 | | | 5.6 | 9 | 0 | 17.3 |
| Martens | 1875–1896 Göttingen | 74 | 23 | | 12 | 1 | | 86 | 24 | |
| Schlatter | 1881–1900 Zürich | 35 | 1 | | | | | 35 | 1 | |
| Schulz | 1887–1897 Greifswald | 18 | 4 | | 16 | 1 | | 34 | 2 | |
| Petzold | 1889–1892 Erlangen | | | | | | | 17 | 2 | |
| Total | .. | 488 | 114 | 23.4 | 202 | 20 | 9.9 | 760 | 146 | 19.6 |

# CHAPTER VI

## THE DIAGNOSIS AND OPERATIVE TREATMENT OF MALIGNANT DISEASE OF THE UPPER AND LOWER JAWS

CONTENTS OF CHAPTER:

I. Diagnosis: Considerations of age.—Considerations of sex.—Situation of growth.—Consideration of duration and rate of growth.—Considerations of jaw involved.—Considerations of trauma.—Character of tumor.

II. Principles underlying the treatment of malignant disease of the upper jaw: Operative treatment: Preliminary steps: Cleansing the mouth; Stomach-tube; Morphin.—Anesthetic: Method of administration.—Position of patient.—Tracheotomy.—Control of hemorrhage: Ligation of the carotid; Historic; Temporary compression of carotid; Permanent ligation of carotid; Pharyngeal tamponade and intubation of the pharynx.—Details of operation of excision of upper jaw: Removal of the orbital plate; Dissection of the neck.—Principles of operative treatment.—Osteoplastic total resection of the upper jaw.—Excision of one-half of the inferior maxilla.

### DIAGNOSIS

THE growths of the jaws considered in the foregoing pages are epulis, sarcoma, the fibroma group of tumors, pure odontoma, carcinoma, the adamantine epithelioma, and the dentigerous cyst.

The detailed differentiation of these several growths has been carefully made in the description of each form.

To facilitate the diagnosis of these tumors the surgeon should consider—(*a*) The history of the tumor; its exact time of appearing; its precise location at the beginning; its size when first detected; the rate of its growth; the jaw involved; the possibility of trauma; the condition of the teeth in early and adult life; associated conditions of pain, discomfort, and deformity; he should consider the presence of glandular enlargement, metastatic growth, cachexia, syphilis,

and tuberculosis. (*b*) The surgeon should make a careful examination of the tumor, to determine its physical characteristics. If an accurate history and a satisfactory examination of the tumor are possible, and if the facts thus obtained are interpreted upon the basis of the story of individual growths as related in these pages, there should be comparatively little difficulty in arriving at a positive diagnosis.

*Considerations of Age.*—Sarcoma of the jaw thrives before fifty years of age. Between fifty and seventy years of age carcinoma of the jaw flourishes. The adamantine epithelial tumor appears between twenty and forty years of age.

Old age and the age of the milk teeth rarely see the adamantine tumor.

*Considerations of Sex.*—Men are more likely than women to have carcinoma of the jaw. Women, more often than men, develop an adamantine epithelial tumor.

*Considerations of the Initial Seat of the Growth.*—Epulis rarely originates behind the last molar tooth. It appears most commonly near the canine and bicuspid teeth. It starts on the inner, rather than the outer, side of the alveolar process. Epulis is almost never seated on the body of the lower or upper jaw.

Sarcoma involves the body and alveolar process.

Epithelioma (carcinoma) involves the jaw first along the alveolar border.

The periosteal osteosarcoma starts in the body of the jaw, near the angle, rather than in the alveolar process or ramus.

*Considerations of the Duration and Rate of Growth.*—A tumor of the jaw that has existed for several years was not malignant at its origin, and probably is not malignant at all.

However, the tumor of long life may contain areas of malignant degenerated tissue. Especially is this true if there have been periods of rapid growth.

The adamantine tumors, the dentigerous cysts, the mixed tumors of bone, cartilage, and possibly myxomatous tissues, all may have existed for years before they are brought to the physician for treatment.

Carcinoma and sarcoma could not exist in the jaw for three years without causing death or extreme local discomfort, necessitating surgical consultation.

When a history is obtained from a patient that a jaw tumor has existed for several years and has been of gradual growth, the tumor is probably benign in character.

A very rapidly growing tumor suggests at once a round-cell sarcoma, a perithelial angiosarcoma, a rapidly filling dentigerous cyst, an infected adamantine epithelial growth, or a carcinoma.

The adamantine tumor may be detected when as small as an English walnut; it may grow to the size of a large grapefruit. The adamantine tumor is usually of slow growth. It may continue as many as twenty years in duration.

Carcinoma of the jaw progresses rapidly, without intermissions. A patient with carcinoma of the jaw rarely lives longer than two years after the first appearance of the disease.

*Considerations of the Jaw Involved.*—The lower jaw is more often the seat of epulis than the upper jaw. The lower jaw is more often the seat of the adamantine epithelial tumor than the upper jaw. The adamantine tumor is seated on one side of the body, or on the alveolar border, near the angle.

The upper jaw is the seat of carcinoma more frequently than the lower jaw. The upper jaw is the seat of sarcoma more frequently than the lower jaw.

*Considerations of Trauma.* –A history of previous trauma always should suggest that the tumor is a sarcoma. Trauma is probably not of the same etiologic importance in carcinoma of the jaw that it is in sarcoma of the jaw.

*Character of the Tumor.*—Any tumor appearing in the jaw after the time of the full development of all the teeth cannot be an odontoma.

The adamantine tumor grows most often from the angle of the jaw.

The kidneys should be palpated carefully in every case of tumor of the jaw in which there is any good reason for suspecting a metastatic hypernephroma. This is one of the unusual possibilities, but is to be kept in mind. The metastatic tumor may be the evident growth.

All jaw tumors should be regarded as malignant until every means has been exhausted to demonstrate their benign character.

A bony growth that is situated upon the alveolar process of the jaw (upper or lower) suggests a benign tumor.

The periosteal sarcoma (ossifying sarcoma) does not arise in the alveolar border—it arises from the body of the bone.

At the angle of the lower jaw, extending along the ramus, grows the periosteal round- and spindle-cell sarcoma. It is so malignant that it soon becomes incurable by operation.

## THE OPERATIVE TREATMENT OF MALIGNANT TUMORS OF THE JAW

**Principles Underlying the Treatment of Malignant Disease of the Upper Jaw.** The malignant forms of sarcoma and carcinoma of the jaw are rarely cured by operation. It is the exception, rather than the rule, to find cured cases with well-authenticated pathologic reports.

Very thorough removal of the disease in its beginning will eradicate it.

In malignant disease of the upper jaw, whether carcinoma or sarcoma, complete excision of the jaw is the best plan. Partial operation upon the upper jaw for carcinoma is to be employed only in exceptional cases of squamous-cell carcinoma of the alveolar border.

The operative attack in carcinoma of the upper jaw should have little regard for anatomic structure. If the orbital tissues are involved directly, or if they lie close to the carcinoma, the eye should be removed, and the orbital space cleared of its contents at the primary operation. All structures which prevent a thorough and complete removal of the disease should be sacrificed.

The operation for removal of a tumor of the upper jaw demands, on the part of the surgeon, technical skill and an appreciation of the details of operative work second to no other operative procedure.

**Preliminary Steps.** – *Cleansing the Mouth.* The buccal and nasal cavities are cleansed with difficulty. Probably they can never be made absolutely aseptic. An attempt, however, should be made to render them clean. A proper cleansing of the cavities of the nose and mouth will conduce to rapid healing of operative wounds, and will dimin-

ish the liability to infection from an ulcer through the cut surface.

A dentist should be employed to remove or care for all carious teeth. Any teeth remaining should be thoroughly scaled and burnished. This should be done three or four days previous to operation. The tooth-brush should be used after each feeding, up to the time of operation. A mouth-wash of a mild alkaline mixture, such as Dobell's solution, alkalol, or Seiler's tablets, should be employed at least three times daily previous to operation. If it is possible to cleanse the nose by douches and sprays, this should be done before operations which are likely to open the nasal cavity.

This attempt at cleansing the mouth and nose previous to operation will diminish the number of pathogenic bacteria present in these parts. It is a fact, moreover, that parts thus approximately cleansed heal more readily and kindly than parts not thus cleansed.

*Stomach-tube.*—For several days previous to a contemplated operation the patient should be taught to use the stomach-tube in feeding himself. He will then become accustomed to its use. After operation, for at least one week, feeding should be accomplished through the stomach-tube. The parts about the jaws are thus afforded more complete rest. The likelihood of infection is lessened, and healing is facilitated. A mouth-wash should be used each time after the stomach-tube is employed.

*Morphin* ($\frac{1}{6}$ grain) and atropin ($\frac{1}{120}$ grain), if given hypodermically one-half hour before operation, will make the administration of the anesthetic (ether) easier, and will

also render the patient's recovery from the anesthetic less disagreeable.

**Anesthesia.**—The anesthetic to be employed in operations upon the jaws is ether. The patient may first be put to sleep by ether administered from an open cone over nose and mouth. The continuance of the anesthesia by nasopharyngeal tubage, as suggested by Crile, is most satisfactory. The pharynx is cocainized. Two flexible rubber tubes are introduced through the nostrils to the pharynx, just above the epiglottis. The tongue is drawn forward, and a gauze tamponade placed in the pharynx snugly enough to retain its position about the tubes without compressing them unduly. These tubes are united in a Y glass tube, which in turn is connected by rubber tubing with a glass tube containing a bulb for catching the ether, which condenses and collects in the apparatus. This latter glass tube is connected by a rubber tube with a glass funnel containing gauze for saturation with ether.

By this method of nasopharyngeal etherization the anesthetist is stationed away from the field of operation. The surgeon is not hampered by the immediate proximity of the anesthetist; the dangers from blood being inhaled are removed; the operative procedure can be carried out with greater thoroughness, because with less haste than by the older method; the patient may be operated upon in the upright or nearly upright position, with no trouble from blood in the pharynx. The danger of postoperative pneumonia is reduced to a minimum.

**The Position of the Patient During the Operation.**—For forty years or more the sitting or upright position has been employed for nearly all operations upon the upper and

lower jaws at the Massachusetts General Hospital, Boston. It is the position best suited to the convenience of the surgeon, and is satisfactory for the patient. To maintain this position most effectively the head must be held by an orderly during the whole period of the operation for the removal of the upper or lower jaw. The head can thus be moved or turned at the operator's command. If blood happens to get into the patient's mouth, a tilting of the head forward gives it an opportunity to run out.

**Tracheotomy** will almost never be required if the above methods are used. Tracheotomy is in itself an added risk to the operative procedure. An emergency alone would demand this operation.

**Assistants.**—It is necessary to have enough assistants readily to do the things required. There should be a first assistant, who shall assist in the performance of the operation, the handing of instruments, the tying of vessels, etc.; a second assistant, to retract and to watch the mucosa of the floor of the mouth, so as to keep all blood from the gauze in the pharynx; a third assistant, to administer the anesthetic; a fourth assistant, the nurse who attends to the sutures and sponges; a fifth assistant, who holds the head and jaw so long as it is needed.

Of course, this operation can be done with fewer assistants, but there is no operation which requires the full complement of assistants more than this one, if the technic is to run satisfactorily.

**Control of Hemorrhage.**—*Ligation of the Carotid: Historic.*—Martens estimated the mortality following excision of the upper jaw at Göttingen to be from 23 to 31 per cent. in 74 cases. Sixteen died from lung complications.

From Greifswaldse 18 resections of the upper jaw gave a mortality of 22 per cent. Bryant's group of 230 cases of resection gave a mortality of 14 per cent.

These mortality rates were recognized as high. It was also understood that hemorrhage at the time of operation into the pharynx and a sucking of blood into the lung caused many deaths from pneumonia.

Rose, in 1878, advocated operating with the head low (Rose position), so that the blood accumulating in the pharynx might be removed and an aspiration pneumonia avoided. Tracheotomy and the tamponade cannula were devised to prevent blood from entering the trachea. Methods of partial anesthesia were struggled with, hoping that the voluntary expulsion of blood from the pharynx and trachea might lessen the dreaded mortality.

Pirogoff, in 1840, and Madelung, in 1874, had raised the question of the wisdom of cutting off the blood-supply to the head in operations upon the head, to diminish hemorrhage.

Schlatter states that Professor C. Reyher, of St. Petersburg, first ligated the common carotid for the checking of hemorrhage in some 27 cases of head surgery. He had but one death. So fearful was Reyher of harm to the brain from this ligation that he was accustomed to practise intermittent compression of the vessels to be tied for eight days every hour for ten minutes previous to operation, to accustom the brain to the effects of the ligation.

Zimmerman found that after ligation of the common carotid there were 31 per cent. of deaths, 26 per cent. of these with brain symptoms, and 11.6 per cent. showing cerebral softening. Riese found, in 73 operations for ligation

of the common carotid, 17 deaths and 25 per cent. of cerebral disturbance. Lipps found that of 130 cases of ligation of the external carotid, there were 2 deaths.

Ligation of the common carotid lessened hemorrhage, but carried with it so high a mortality-rate in itself that it was dropped from common surgical practice. Ligation of the external carotid avoided the cerebral complications attending ligation of the common carotid, but introduced a new danger—cerebral embolism. It was found that, by placing the ligature upon the external carotid too near the bifurcation of the common carotid, a thrombus forming in the external carotid extended into the internal carotid, and in a number of cases a portion of this thrombus became detached and a cerebral embolism resulted.

Von Lesser, in 1882, temporarily ligated the common carotid in man successfully. Eberth and Schimmelbusch, in 1888, studied the effect in animal vessels of temporary compression. Senger, in 1895, demonstrated that the arteries of animals could be compressed temporarily without harm to the artery. He successfully temporarily compressed the external carotid upon man. Schoenborn, from the Königsberg clinic in 1896, used a temporary clamp for the carotid, and exhibited at the International Surgical Congress at Rome a clamp for this purpose.

Crile, in this country (1902), recorded his experiments upon dogs and man of temporary compression of the carotid. He published the details of 28 compressions, with the results. Crile's cases were operated upon between the years 1897 and 1901.

It will thus be seen, from this hasty outline, that today we have arrived at temporary compression of the large

vessels of the neck instead of ligation for operations upon the head, neck, and jaws. Temporary compression is safe and efficient. Ligation may be dangerous.

*Temporary compression of the external carotid* is usually efficacious in preventing undue bleeding in operations upon the jaws. Temporary compression of the *common* carotid may at times be advantageously employed in very large growths.

*Permanent ligation of the common carotid* had best not be done, because of the high mortality attending it, especially in those past fifty years—the age when these operations are likely to be needed.

*Permanent ligation of the external carotid*, if the ligature is placed well above the origin of the vessel, is comparatively safe.

Matas, in a large series of some 100 ligations of the external carotid, has had but 2 fatalities. These two fatalities were among the earlier cases done by him, when the ligature was placed low (personal communication).

If the ligature is placed above the superior thyroid and all branches of the external carotid are ligated separately, then there is no risk.

Temporary compression of the common carotid is perfectly safe and effective, and is the procedure of choice. Temporary compression of the external carotid is usually efficient.

In atypical operations and partial resections ligation, permanent or temporary, is unnecessary.

The choice of the place of compression of the common or external carotid is similar to the place for ligation—some little distance from the bifurcation.

One should always avoid unnecessary trauma to the artery itself. In ligation the walls of the vessel are to be firmly approximated, not crushed. Unless the compression of the vessel is carefully graduated, undue pressure upon the intima may damage it, thus causing a thrombus, from which later may go an embolus.

*The Pharyngeal Tamponade and Intubation of the Pharynx.*—Packing the pharynx was first suggested by Gosselin in 1855, for preventing blood from getting into the trachea. It was later practised by Verneuil. In 1869 it was employed by Nussbaum, together with a previous tracheotomy. In 1870 came Bellocq's balloon, Trendelenburg's tampon cannula, and Rosenbach's modification of the latter. A little later Rabe used a catheter in the glottis. Rose used his position that gravity might turn the flow of blood.

Today the administering of ether by the nasopharyngeal tube (Crile), which is surrounded by gauze in the pharynx, prevents what little blood may appear from getting further than the gauze pack. The employment of direct tubage to the larynx and trachea has no advantage in these cases.

**The Operation of Excision of the Upper Jaw.**—The patient for excision of the upper jaw, having been anesthetized and thoroughly relaxed, is placed in an upright sitting and partly reclining position. The chest and shoulders are carefully protected by warm coverings. The head is held upright by an orderly, who stands behind the patient's chair, holding the head in a firm grasp of both hands upon the sides. The head is thus held firmly at any angle desired by the operator—it is an intelligent hold.

A gag is placed in the mouth. The nasal tubes of Crile are introduced, and are seen to rest at the level of the back

of the epiglottis. The tongue is drawn forward by a thread passed through its center and caught in a snap.

At the time of the operation any bleeding ulcers or dirty ulcerations within the mouth should be burned with the actual cautery, to disinfect and dry the parts.



Fig. 282.—Showing the most satisfactory incision (Ferguson-Webber) to be used in excision of the upper jaw.

The pharynx is filled with sterile gauze packed fairly snugly around the rubber nasal tubes, so that little or no air enters excepting through the nasal tubes. Nasal breathing

PLATE VI

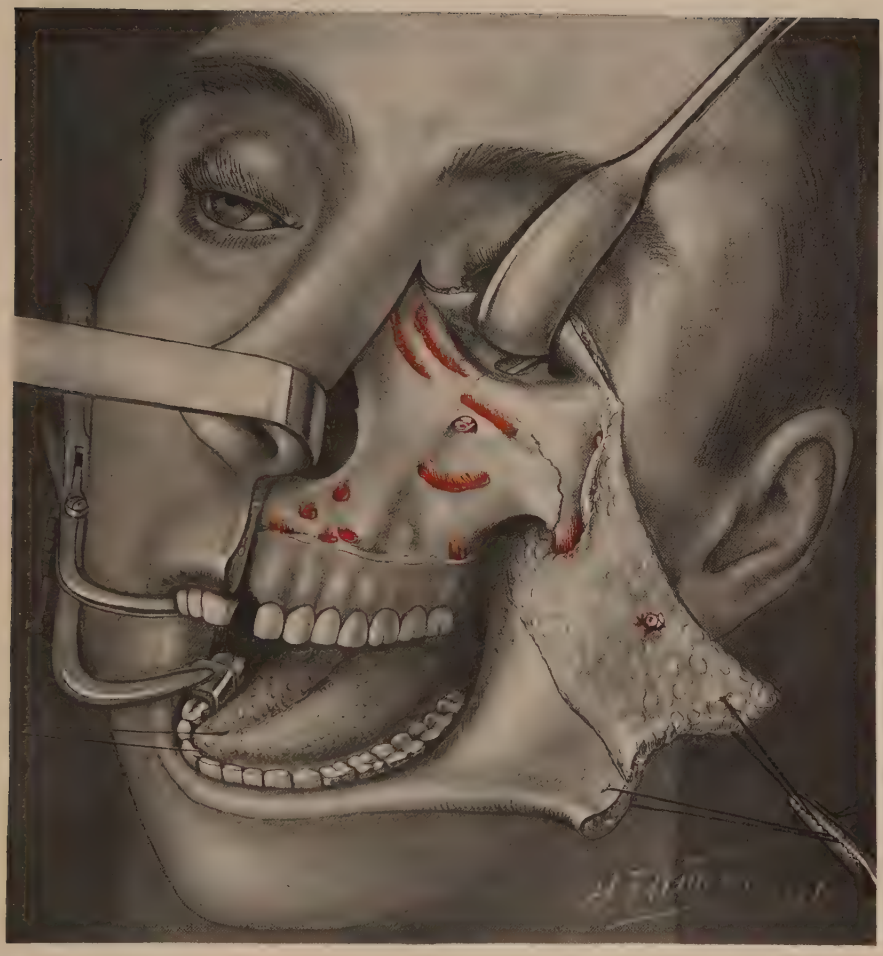

Showing the superficial flap reflected so as to expose the origin of the masseter; the loop through the tongue; the orbital contents retracted gently; the incisor tooth extracted; the nasal cavity opened. Note the gag *in situ;* the muscular attachments still adherent to the upper jaw; the infra-orbital foramen and its contents.

is favored, and pharyngeal soiling with blood is avoided, by the gauze tampon.

The incision, according to Dieffenbach or Ferguson, is made from the outer canthus of the eye to the inner canthus, down along the nose and cheek, in the lateral sulcus curving around the ala of the nose, to the median line of the upper lip

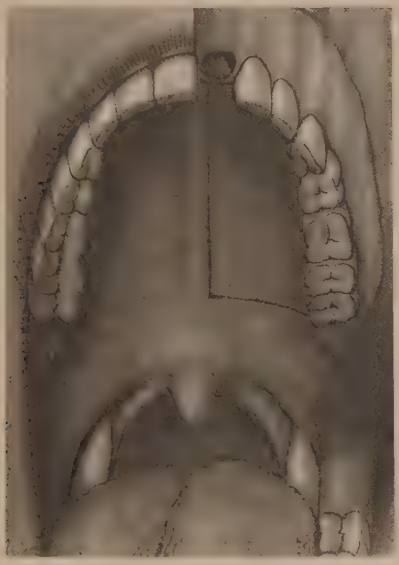

Fig. 283.—Showing (somewhat diagrammatically) the mouth wide open, incisor tooth extracted. Note the incision in the median line and at the junction of the hard and soft palates in the roof of the mouth.

and through the upper lip. This mucocutaneous flap is reflected back off the bone far enough to bring into view the anterior portion of the malar bone origin of the masseter muscle (Plate VI). The incisor tooth is extracted upon the side from which the bone is to be removed. There remain to be divided the bony attachments of the upper jaw. The hard palate is divided by a narrow-bladed saw introduced

into the nostril of the side to be removed. Before completing the saw cut the soft palate should be freed from the hard palate, and a median incision made with a knife down to bone along the hard palate.

The nasal process of the superior maxilla is divided by a small, sharp-pointed bone-forceps. The malar attachment is best partially divided by a narrow-bladed saw, and the division completed by the bone-forceps.

The pterygomaxillary attachment is now to be divided. A chisel is entered between the posterior edge of the superior maxillary alveolar process, just in front of the pterygoid plate. A sharp blow of the hammer upon the chisel thus placed severs this attachment. The orbital plate, if it is to be left *in situ*, is divided from the infra-orbital ridge by chisel or sharp, strong scissors or bone-forceps. If it is not to be retained, it is then removed with the entire bone intact.

The upper jaw is now grasped by lion forceps, holding the infra-orbital ridge and anterior alveolar border, and twisted out of place. Any remaining shreds of tissue holding the bone and tumor are divided by scissors.

Into the cavity left by the jaw and tumor is immediately thrust a large temporary gauze packing. This will probably check all bleeding. If, by chance, visible bleeding vessels are found after the pack has remained *in situ* a few moments, these are twisted or ligated.

The relatively superficial parts, the jaw and tumor, which have obstructed a view of the deeper important structures, having been removed, there follows, perhaps, the most important part of the operation—the minute inspection of all parts suspected of malignant disease. Keen has emphasized

the importance of observing very great care in clearing out all sinuses which may contain malignant disease. Those sinuses communicating with the nose directly should be carefully inspected. The posteriorly and anteriorly seated ethmoid, sphenoid, and frontal cells all require inspection.

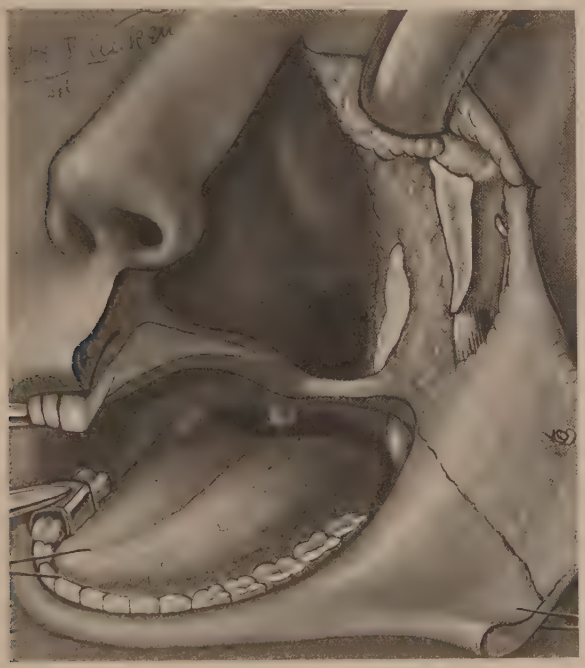

Fig. 284.—Showing the appearances after the removal of the upper jaw. Note the division of bony surfaces—the malar, the hard palate, the pterygoid plate. Note the soft palate intact.

It is into these remote recesses that malignant disease may grow, and they should be explored most assiduously if a recurrence of the disease is to be avoided. (See figures illustrating the sinus relations.)

The temporary packing having been replaced by a per-

manent iodoform packing, the external wound is closed. The edges of the skin should be very carefully approximated.

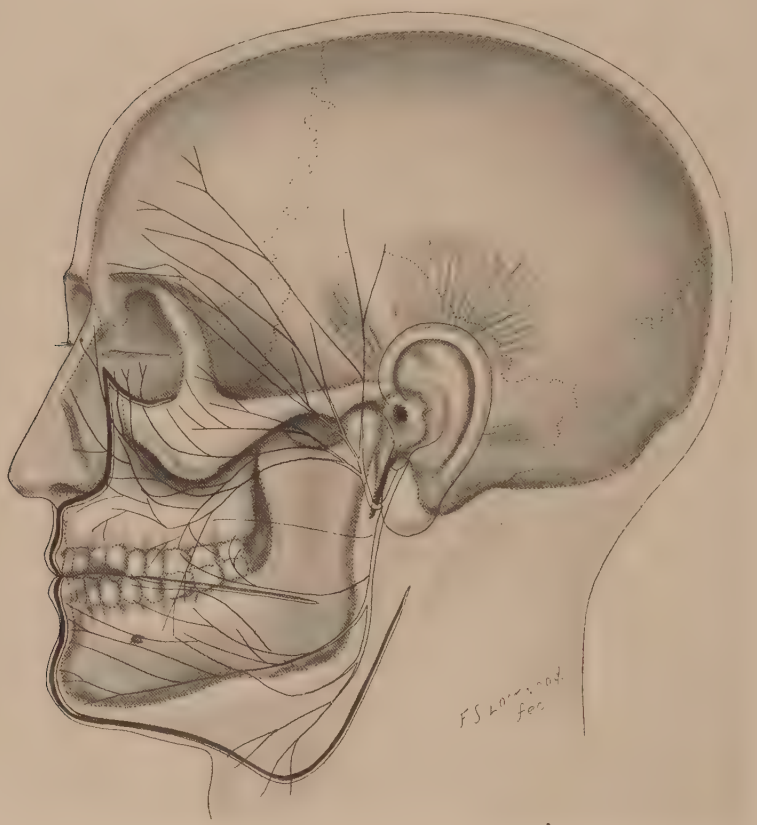

Fig. 285.—A diagrammatic drawing showing two commonly employed lines of incision—the upper one for excision of the upper jaw, the lower one for excision of one-half the lower jaw; the middle incision, from the angle of the mouth, is occasionally employed in operations upon the lower jaw. Note the relations of the seventh nerve to the lines of incision (after Bockenheimer).

The patient is put to bed, lying down at first. Subsequently he is allowed to assume a semi-sitting posture. The patient is permitted to be up and about two days following

the operation. The immediate shock from the operation is sometimes considerable, but ordinarily is not very marked.

Following the healing of the wound, there need be very slight visible cicatrix.

If the carotid, either external or common, has been temporarily compressed, it is wise to remove the compression before the final tamponade of the cavity is made, and before the skin sutures are placed, in order to be positive that no vessel still requires ligation. If ligation of either carotid has been done, the final tamponade should be just as rigorously placed as if no ligation existed.

*Removal of the orbital plate* of the upper jaw may result in such discomfort to the individual from diplopia, etc., that it is to be seriously considered before being attempted. If the disease cannot be removed thoroughly, *i. e.*, if the growth has invaded the orbital cavity or encroaches upon it at all, it is wise to remove the orbital plate. If the cavity of the orbit is involved in the disease,—I speak now of carcinoma especially,—then the eye and all the contents of the orbital space must be removed thoroughly. This is especially true of carcinoma starting in the superficial parts of the face. The moment it is detected extending to the parts of the orbit, no matter how superficially at first, then the whole of the orbital contents must be removed if safety is desired.

The orbital plate support may be provided by using, as suggested by König, a bit from the coronoid process of the inferior maxilla and its attached temporal muscle-fibers. Such a bone-flap, swung across under the eye, affords satisfactory support to the globe of the eye.

*Dissection of the Neck.*—In cases of sarcoma, unless the glands are palpable, dissection of the neck is probably

unnecessary. In cases of carcinoma of the upper jaw the neck should be dissected, and upon both sides, from the clavicle up to the base of the skull. Despite the fact that certain cases seemingly recover and live many years without a dissection of the neck, the operative attack in ordinary cases cannot be too vigorous.

All parts should be sacrificed that in any way may prevent a thorough and complete removal of the disease.

*Principles of Operative Treatment.*—Operations for the removal of malignant tumors of the upper jaw may be performed in two stages. It may be wise, under certain circumstances, to operate upon the jaw at one time, and upon the cervical glandular enlargements at another. The glandular dissection should precede the operation upon the jaw. The dissection of the neck should be most thorough.

Those cases without definite glandular enlargement are the ones in which it is best completely to dissect the neck. This dissection of the neck should be done at the primary operation, reserving for a second operation the removal of the jaw tumor.

The interval between the two operations should be short —at least two weeks. It is possible to recover well from a neck dissection within that time, whereas recovery from a jaw resection is attended with discomfort over a longer period of time. Therefore it seems wise to attack the jaw tumor after the neck dissection. In a few cases it may be perfectly feasible to do both operations at one sitting.

Prolonged shock, secondary hemorrhage, infection of the operative field, pneumonia, and meningitis following operation for the removal of the upper jaw are all practically eliminated today.

**Osteoplastic Total Resection of the Upper Jaw.** - Osteoplastic total resection of the upper jaw for growths lying posteriorly in the nasopharynx is the operation of Kocher. By it the jaw is turned to one side and afterward

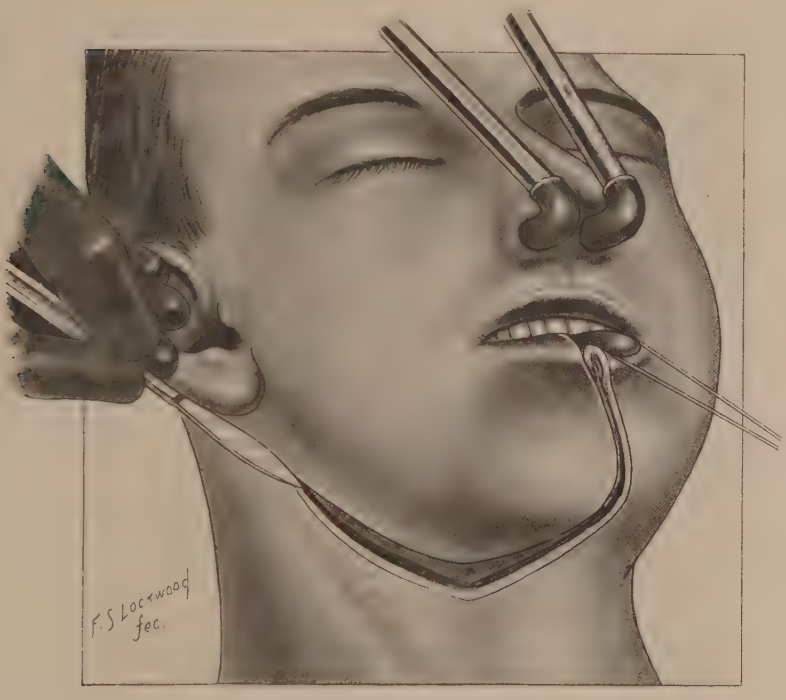


Fig. 286.—The incision through skin, superficial fascia, and platysma for operation of excision of one-half of the lower jaw. Note nasopharyngeal tubage for administration of anesthetic.

brought back into its normal relations. The steps of the procedure are similar, with modifications, to those for removal of the jaw. There are the same primary incision, without separation of the soft parts from the bone, a division of all the bony attachments of the upper jaw, and a division

of the malar process through a small skin incision. The superior maxilla, together with the attached skin, can then be reflected, and the nasopharynx, with its contained tumor, thoroughly exposed.

There have been 14 cases recorded in which such an osteoplastic resection of the upper jaw has been done. The

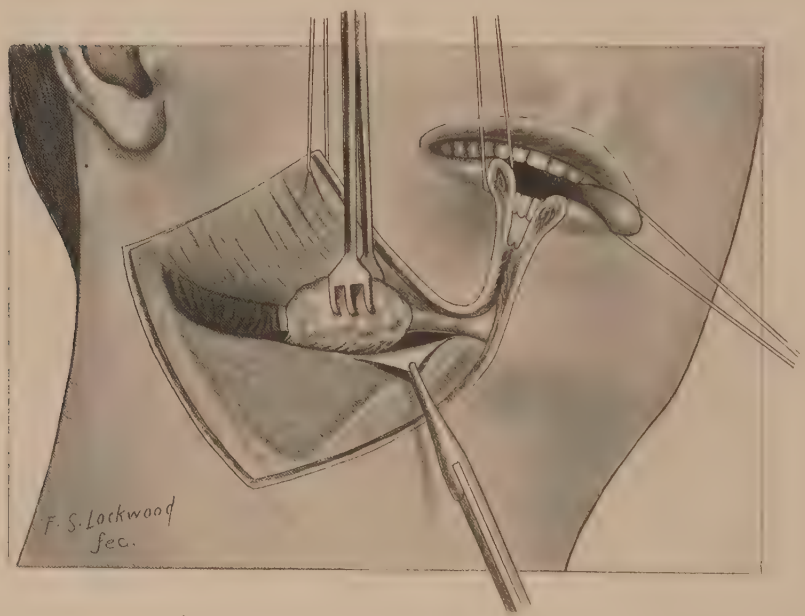


Fig. 287.—Upper flap drawn upward. Deep fascia incised. Submaxillary gland exposed and drawn upward.

operation is attended with very little hemorrhage, which may at all times be controlled by gauze packing, the tamponade being very efficacious.

Ligation of the external carotid or temporary compression of the carotid has not been thought necessary.

Kocher, Depaye, Enderlen, Payr, Streissler, Garré,

Hertle, Hoffmann, and von Bergmann record such cases of osteoplastic operation.

In these cases of osteoplastic resection of the superior maxilla the oral intubation suggested by Kuhn has distinct value.

Fig. 288.—Lower border of inferior maxilla cleared. Digastric muscle seen. Facial artery and vein divided between ligatures.

Streissler's patient (sarcoma) died of recurrence *in loco* several months later.

Hertle's patient was operated on (fibroma) again after three years for recurrence, with good results functionally and cosmetically.

**Excision of One-half of the Inferior Maxilla.**—Even though the old-time stated operations for malignant disease

are less frequently done today, yet there is an accuracy attained by following the conventional description.

The patient is most conveniently operated upon in the

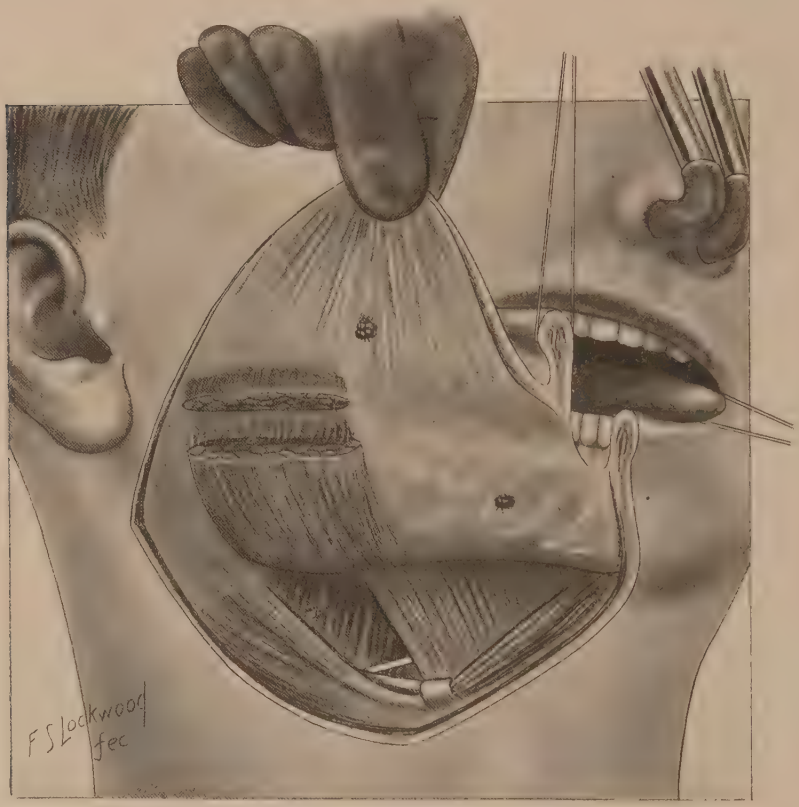


Fig. 289.—Submaxillary gland and attached planes of cellular tissue bearing lymphatic glands removed. Upper flap drawn upward. Mouth not yet opened along alveolar attachment of buccal mucosa. Masseter muscle divided. Hypoglossal nerve seen lying on hyoglossus muscle.

semi-recumbent position, with the head turned slightly to the side opposite to the disease. A thread of silk or silkworm gut is passed through the tongue an inch from the tip,

in the median line. This serves to control the position of the tongue at different periods of the operation, at the same time causing the minimum amount of trauma.

The placing of nasopharyngeal tubes, facilitating the administration of the anesthetic, and the packing of the

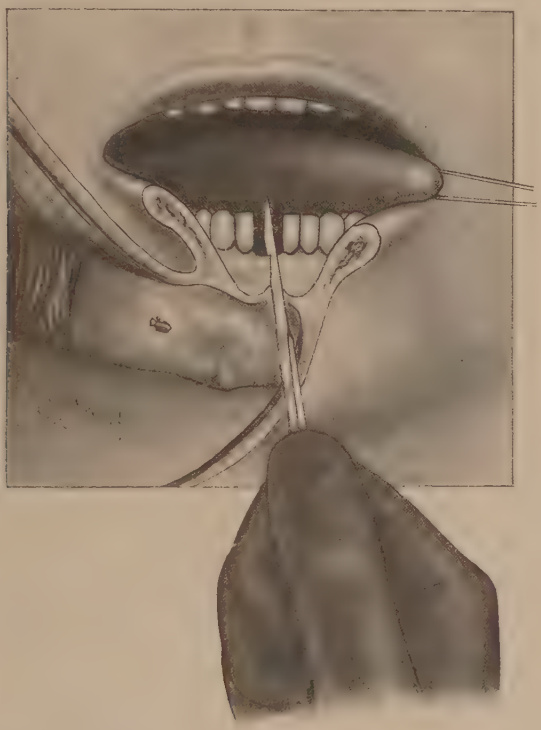

Fig. 290.—Central incisor tooth extracted. Sawing through the inferior maxilla.

pharynx with gauze, having been completed, ether is given with convenience and efficiency, and blood is hindered from trickling into the larynx by the pharyngeal gauze tampon. Rarely will any control of the circulation, such as compression or ligation of the carotid, be required.

The incision (see Fig. 286) beginning at the middle of the lower lip, extends in a downward curve to the level of the upper border of the thyroid cartilage, and from here upward

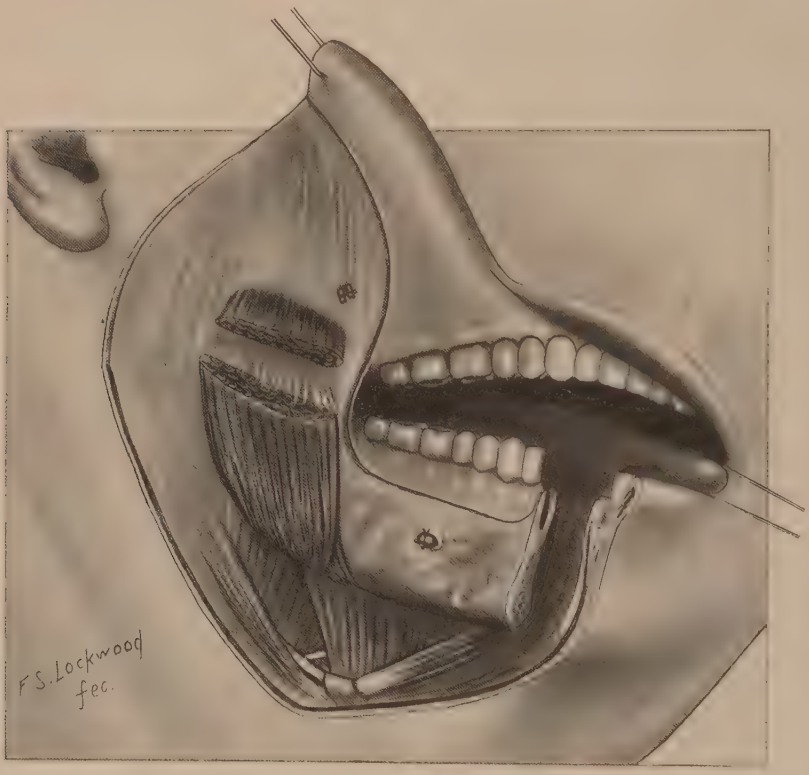


Fig. 291.—Inferior maxilla divided. Alveolar mucosa attachment being divided.

and still backward to a point in front of and below the lobe of the ear.

The incision includes the skin, subcutaneous tissue, and platysma muscle. The platysma is reflected with the skin in order that, by subsequently suturing the platysma, the skin may be more accurately approximated, and there may

be less subsequent traction upon the superficial scar by the deep cicatrix.

The reflection of this flap exposes the outer surface of the

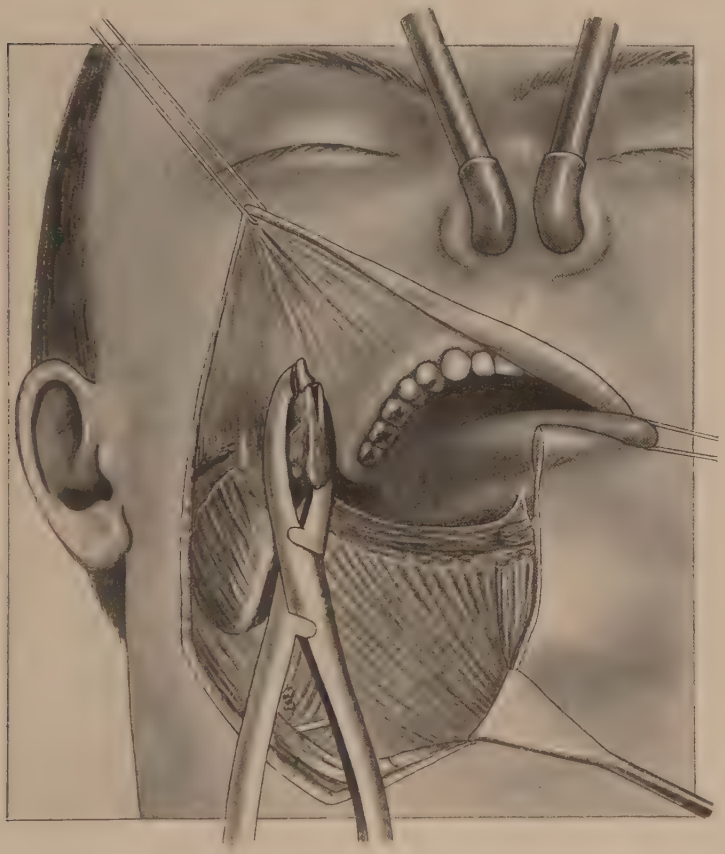

Fig. 292.—Inferior maxilla grasped by lion forceps, everted and depressed.

jaw and submaxillary region. The mucous membrane just to the outer side of the alveolar process is not yet divided. The mouth cavity is unopened throughout the great extent of the wound. (See Fig. 289.)

This incision avoids important facial nerve branches and affords convenient access to the whole submaxillary region.

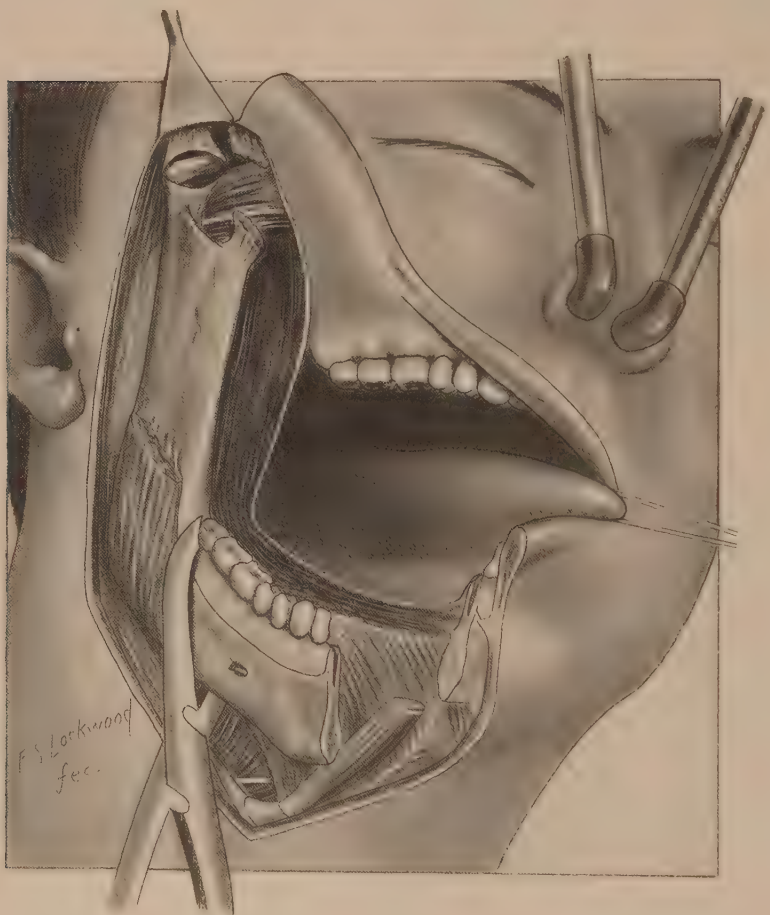

Fig. 293.—Inferior maxilla everted, rotated outward, and depressed, to expose the temporomaxillary joint. Capsule of joint incised. Temporal muscle coronoid attachment divided. External maxillary artery is seen near the border of the external pterygoid muscle.

The facial artery is immediately secured between two ligatures where it enters beneath the submaxillary gland.

The fascia covering the gland anteriorly is divided, the floor of the submaxillary triangle is uncovered, and its contents are carried upward with the gland.

The edge of the bony jaw is uncovered for its whole length. All the fascial and cellular tissue is detached from the jaw and turned down with the submaxillary gland and the submaxillary triangle contents.

The planes of cellular tissue carrying the lymphatics are followed *as planes* beneath the muscles of the floor of the mouth anteriorly. The submaxillary gland, lymphatics, and cellular planes of lymph tissue are removed *en masse*.

The jaw is freed of all attached tissue by blunt dissection upon the inner side as far as the mucous membrane of the floor of the mouth. The muscles anteriorly, the digastric, mylohyoid, and the geniohyoid, are divided or separated from the maxilla at their origins.

An incisor tooth is extracted. The jaw is divided by a saw from before backward. (See Fig. 290.) Before wholly dividing the bone by the saw, the bone forceps is used to complete the section. The attachment of the jaw to the mucosa is divided within and without the alveolar border; these two lines of section meet posteriorly beyond the last molar tooth. The jaw is held anteriorly by bone forceps for greater ease of manipulation. (See Fig. 292.)

Upon retraction of the flap near the angle of the jaw, and upon adducting the half of the jaw, the masseter muscle is divided; after abducting the jaw the internal pterygoid is divided; after depressing the jaw the attachment of the temporal muscle is divided -the greater part of this attachment is to the inner side of the coronoid process; upon still further depressing the jaw the external pterygoid is divided,

and the capsule of the joint is opened above the deep internal maxillary artery. (See Fig. 293.)

Great care must be used to avoid wounding the internal maxillary artery. It lies close to the neck of the condyloid process posteriorly and below the capsule.

The external lateral, the internal lateral, and the stylomaxillary ligaments are divided necessarily together with the division of the capsule of the joint and the external pterygoid muscle. The jaw is removed by a slight rotatory movement.

A careful search for enlarged glands is now made along the deep vessels in the lower part of the wound. If it is thought necessary, the neck may be cleared of the cervical lymphatics through an incision parallel with the sternomastoid.

The floor of the mouth may be carefully inspected and all suspected tissue removed.

Complete hemostasis is secured. The mucosa is sutured. Great care should be exercised in securing as tight closure of the oral cavity as possible. Infection of the neck is thereby prevented. The platysma muscle is sutured. The skin is sutured. Drains of rubber tissue are placed at the dependent parts of the neck wound. Concerning the employment of prosthetic apparatus see Chapter IX.

## ANATOMY OF THE SINUSES OF THE NOSE AND THEIR RELATION TO THE UPPER JAW

The very great importance of an intimate knowledge of these sinuses of the deep head and face, in connection with malignant disease of the upper jaw, prompted me to introduce the following illustrations of the anatomy of the regions in question.

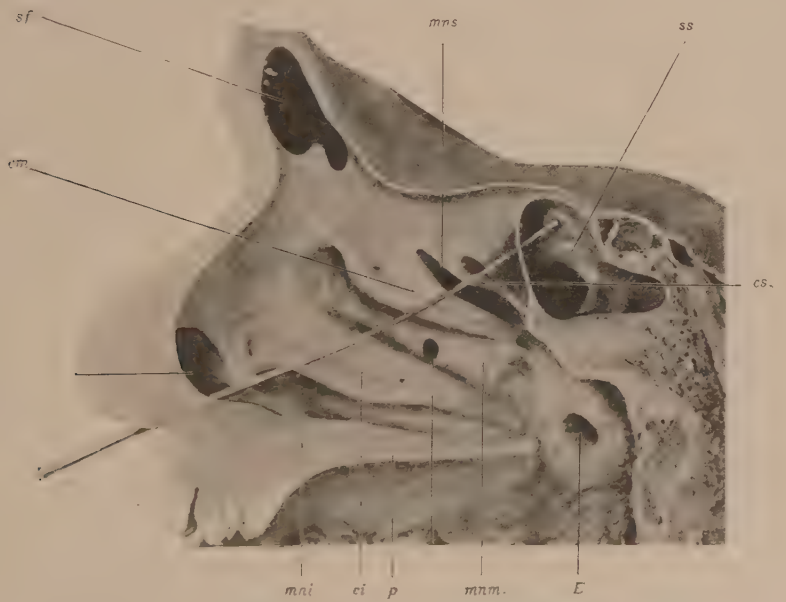


Fig. 294.—Note probe passing from superior meatus of nose into the sphenoid sinus. *sf*, Frontal sinus; *ss*, sphenoid sinus; *p*, hard palate; *E*, Eustachian tube. That malignant disease may readily extend is apparent (after Onodi). *cs*, Superior turbinate; *mns*, superior meatus; *cm*, middle turbinate; *mnm*, middle meatus; *ci*, inferior turbinate; *mni*, inferior meatus.

I believe that early and radical inspection of the sinuses by the surgeon at operation upon these parts, and more thorough removal of suspected tissue from the sinuses, will help to diminish the frequency of local recurrence following operation for malignant disease of the upper jaw.

Fig. 295.—Note the frontal sinuses and cells and the nasolacrimal duct (from Killian).

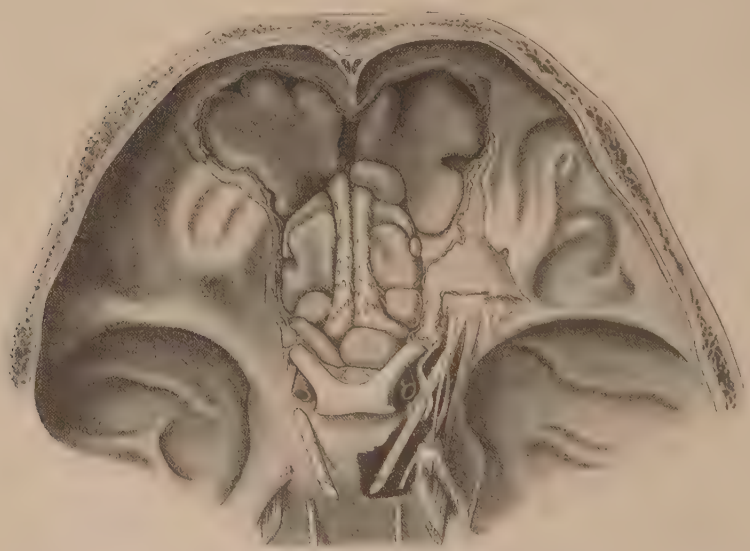

Fig. 296.—Note the ethmoid cells, the sphenoid sinuses, the frontal sinuses, and the superior longitudinal sinus. The base of the anterior fossa has been removed to expose the relative position of those structures. The close relation of the upper nasal sinuses to the meninges is evident (from Killian).

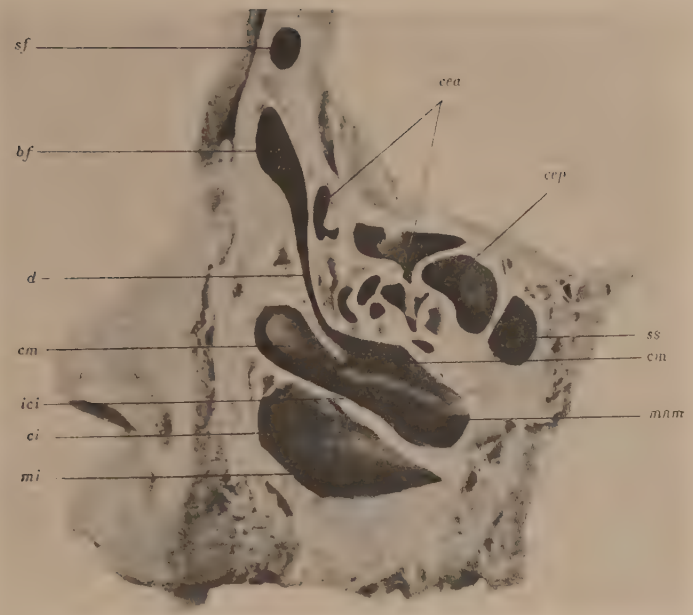


Fig. 297.—Note the passage connecting the bulla frontalis with the middle meatus of the nose. *sf*, Frontal sinus; *bf*, bulla frontalis; *d*, passage; *cm*, middle turbinate; *mnm*, middle meatus; *ci*, inferior turbinate; *ss*, sphenoid sinus; *cea*, ethmoid cells. A new-growth may extend along this passage from the nose (after Onodi).

Fig. 298.—Note the close proximity of the cerebral cavity to the frontal sinuses and ethmoid cells. *sfs*, Right frontal sinus; *sfd*, left frontal sinus; *bfs*, right bulla frontalis; *ce*, *ce*, *ce*, *ce*, *ce*, ethmoid cells; *s*, septum; *bfd*, left bulla frontalis (after Onodi).

Fig. 299.—Note relations of frontal sinus to anterior cranial fossa. Note the thin bony wall separating the orbit from the nasal fossæ, and separating the cranial cavity from the superior nasal fossa at *d*. *o*, Orbit; *sf*, frontal sinus; *s*, nasal septum; *p*, palate; *sm*, antrum (from Onodi).

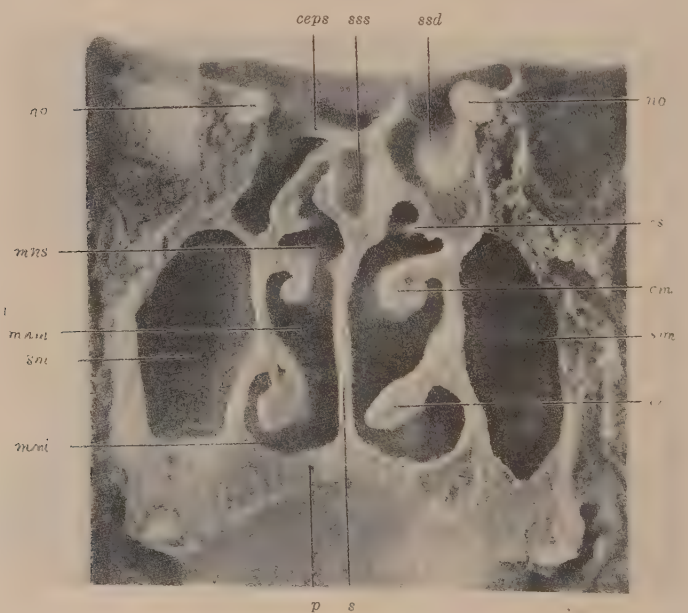


Fig. 300.—Note the relation of the ethmoid cells to the sphenoid sinuses. *no*, Optic nerve; *ceps*, ethmoid cells; *sss*, sphenoid sinus; *ssd*, ethmoid cells; *sm*, antrum; *mnm*, middle meatus of nose; *p*, hard palate; *s*, nasal septum; *cs*, superior turbinate; *cm*, middle turbinate; *ci*, inferior turbinate (from Onodi).

Fig. 301.—Note the depth from the skin surface to which search for disease in sphenoid sinus leads one. Note delicate walls of sinuses. *ss*, Sphenoid sinus; *ci*, internal carotid; *sm*, antrum; *s*, septum (after Onodi).

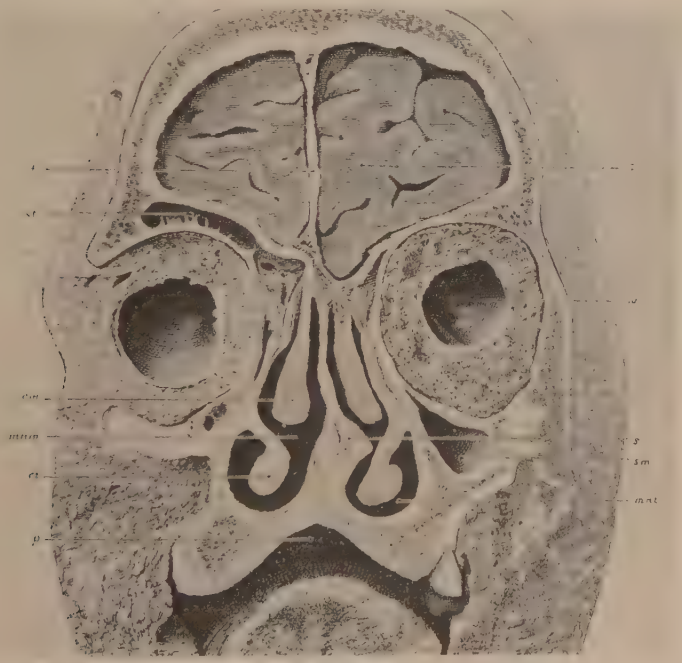

Fig. 302.—Note the intimate relation between the frontal sinus and the nasal sinuses: disease in one may extend easily to the other. *c*, Cerebrum; *f*, falx cerebri; *sf*, frontal sinus; *o*, orbital contents; *p*, mouth cavity; *sm*, antrum; *cm*, middle turbinate; *mnm*, middle meatus; *ci*, inferior turbinate; *s*, septum; *mni*, inferior meatus; *sm*, antrum (after Onodi).

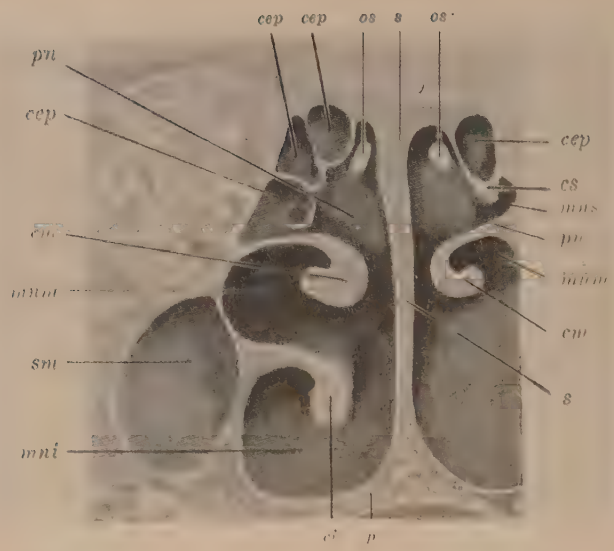


Fig. 303.—Note the opening *os* into the sphenoid cells from the superior meatus. Note angular wall of sphenoid cells. *pn*, *pn*, Superior meatus; *s*, septum; *cep*, ethmoid cells; *os*, entrance to sphenoid cells; *sm*, antrum; *p*, hard palate; *ci*, inferior turbinate; *cm*, middle turbinate; *cs*, superior turbinate (after Onodi).

Fig. 304.—Showing the anterior view of the neck, the symphysis of the jaw divided, tongue erect. Note the position of the glands upon the deep vessels high up, where the digastric crosses. These deep glands are the important ones to be removed in operations for malignant disease of the jaws. Note the lettered groups of lymphatics a, b, d, f, etc. (from Küttner).

# CHAPTER VII

## TUMORS OF THE PALATE

CONTENTS OF CHAPTER: Papilloma of the palate.—Dermoid tumors of the palate.—Sarcoma of the palate.—Melanotic sarcoma of the palate.—Carcinoma of the palate and uvula, operation for.—Mixed tumors of the palate.—Seventeen cases of palate tumors at the Massachusetts General Hospital clinic, tabulated from all cases of diseases of the palate, with end-results.

### PAPILLOMA OF THE PALATE

PAPILLOMATA of the palate are soft, slender, rounded outgrowths, having a body and a pedicle. These growths are not rare. They are attached to the uvula or soft palate at its free edge—never to the hard palate. They grow slowly. They almost never occasion disturbance until they cause a tickling of the throat and a cough. They occur more commonly in men than in women. It is wise to remove these growths.

### DERMOID TUMORS

The fact that the region of the palate is one in which there is an infolding of fetal structures makes it not at all surprising that dermoid tumors are found here.

Associated with these congenital growths are deformities of the jaws, tongue, and lips. The cases recorded have had points of attachment to the hard palate, soft palate, and anterior pillar of the fauces. Paget records a few cases.

After a tumor has reached a certain size it is difficult to determine its point of attachment until an operation is done for its removal.

## SARCOMA OF THE PALATE

Sarcoma of the palate is rather rare. It usually affects the hard palate. The tumor does not tend to ulcerate, as

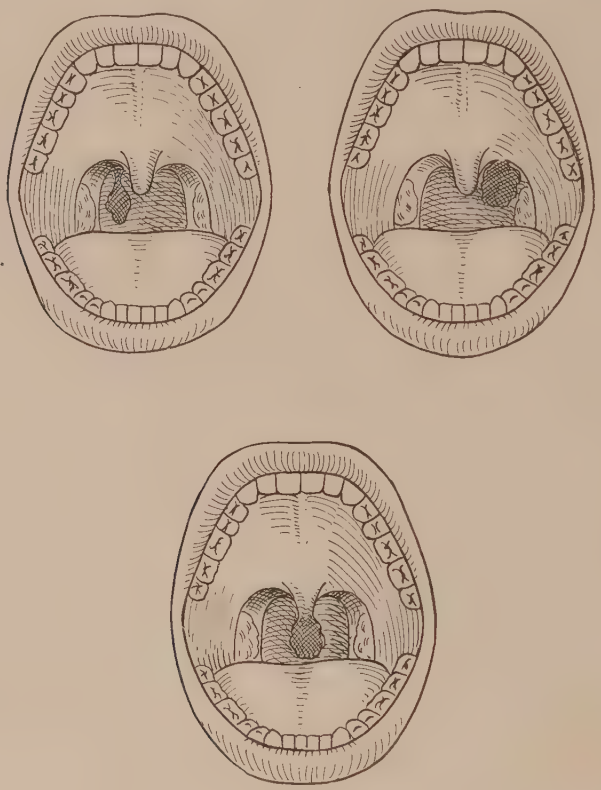

Fig. 305.—To illustrate the frequent seats of papillomata of the palate

carcinoma does. It occurs in adults and old people. The glandular enlargement in the neck is not infrequent.

Round-cell sarcoma seems more common than any other type of sarcoma.

PLATE VII

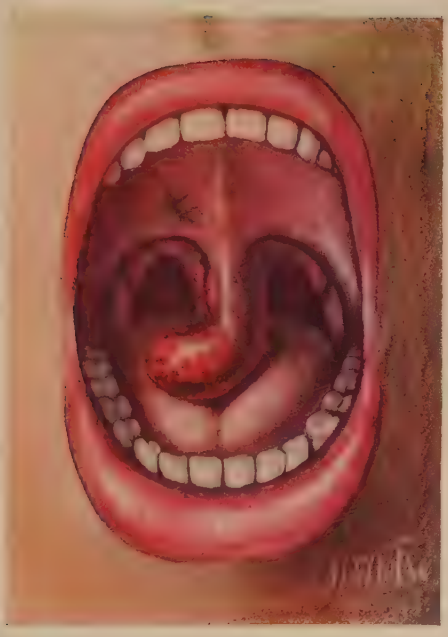

A telangiectatic tumor of the uvula involving the palate. Non-malignant. A girl eleven years old. For several months the uvula has been swollen and bluish in color, 1⅔ inches long and ½ inch wide. At the tip and sides of the uvula are several reddish-blue nodules about the size of a split-pea, and many small enlarged veins appear at the base of the uvula. (Case of F. L. Jack.)

Christopher Heath records two cases, one in an adult and one in a child. The result of the enucleation and cauterization of the adult tumor is not stated. The child died from an inoperable growth.

Sarcoma at an early stage of its growth is difficult to

Fig. 306.—A. S. Sarcoma of the hard palate (Massachusetts General Hospital clinic).

differentiate from a benign tumor. It grows rapidly and may ulcerate.

**Case of Sarcoma of the Hard Palate.**—A. S. Massachusetts General Hospital clinic, August 13, 1907. Thirty-six years old, married. Five months previous to operation he had pain in the left upper jaw and left ear. The swelling appeared in the hard palate, on the left side. It was

excised, but it returned. The external carotid was clamped, and the left upper maxilla was removed. He recovered from the operation. He was treated by the *x*-ray and Coley's serum. He left the hospital September 9, 1907, having recurrence in both the mouth and the pharynx.

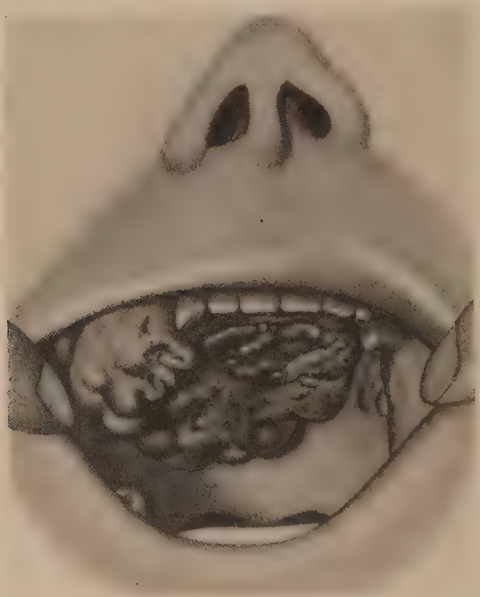

Fig. 307.—Melanosarcoma of the upper jaw, starting in the hard palate. A woman, forty-seven years old (from Mikulicz and Michelson's Atlas, 1892, Berlin).

### MELANOTIC SARCOMA OF THE PALATE

At the Massachusetts General Hospital clinic no cases of melanotic sarcoma have been seen. Gussenbauer, Treves, Billroth, Eisenmenger (from Albert's clinic), and Volkmann (from the Marburg clinic) each report one case.

Billroth's case and Albert's case were each inoperable. Round- and spindle-cells predominated in the tumors examined.

Liebold records one case—a man twenty-four years old, with a melanosarcoma primary in the hard palate. It was excised. It recurred in three months. The upper jaw was partially resected, and the microscope showed it to be a spindle-cell sarcoma without any trace of pigment.

In two and one-half months there was another local recurrence. Another portion of the maxilla and of the nasal septum were removed. This time the microscope showed the recurrence to be melanotic.

Gussenbauer's* case was of the hard and soft palate. He removed the disease (this was in 1886) with the curet and thermocautery. Recurrence took place in four years. It was excised this time and healed. No further history was given.

Treves† reports a case of melanotic spindle-cell sarcoma removed from the hard palate of a woman fifty-eight years old. Recurrence appeared within a year in the right nostril and neck.

### CARCINOMA OF THE PALATE AND UVULA

Primary carcinoma of the palate is very rare. Friedman‡ reports a case of primary carcinoma of the uvula in a man of forty-nine whose only symptom was pain on swallowing. The uvula was transformed into a reddish-yellow tumor about the size of a cherry. He says there are only four other cases in the literature, but gives no references and no illustrations.

Blauel and Vitaul§ record one case of primary epithelioma of the soft palate.

* Prag. med. Woch., Nov. 9, 1886, vol. iii, p. 171.
† Brit. Med. Jour., 1886, vol. ii, p. 862.
‡ Berlin. klin. Woch., April 10, 1905, vol. xlii, p. 444.
§ Loire med., 1900, vol. xix, pp. 120–127.

Smith* reports a case of primary carcinoma of the uvula in a man of fifty-one, a pipe-smoker, whose symptoms were difficulty in swallowing and dryness of the throat for nearly a year. On the uvula was a strawberry-like mass, with some erosion, and induration extending over the right side of the soft palate for half an inch. The tumor was removed, but recurred in a month. After a more extensive removal it recurred again in three months, and was again removed. Five months later the patient was well and free from recurrence.

McCaw† reports a case of primary carcinoma of the uvula in a woman of thirty-seven who, for eight months, had slight throat irritation and some soreness. She had a mass involving the uvula, velum palati, each posterior faucial pillar, the right lateral and a portion of the posterior wall of the pharynx. The growth was partly excised, cureted, cauterized, and she was treated with *x*-ray for six months, at the end of which time she was said to be cured. McCaw says there are 40 other similar cases in the literature, but gives no references or illustrations.

Squamous-cell carcinoma may begin in either the hard or soft palate, and may spread to any adjacent structures. It forms an ulcer with indurated base and elevated edges. The lymphatic glands of the neck are often involved.

**Removal of Tumors of the Palate.**—All benign tumors may be excised by incision near their attachments or they may be enucleated.

All malignant tumors should be given a wide berth, including much sound tissue in the portion excised.

* N. Y. Med. Jour., April 29, 1905, vol. lxxxi, p. 850.
† *Ibid.*, August 9, 1902, vol. lxxvi, p. 225.

Jacobson believes that when the growth is large, preliminary tracheotomy, plugging the fauces, slitting the cheek, and ligating the external carotid are all necessary to insure a radical removal of the disease. Jacobson has one case each of cancer and sarcoma alive, one four and a half years, and the other five years, after operation.

Whenever the growth is in the hard palate, it will be necessary to chisel through the sound bone. Enucleation alone will be unwise.

*Results of Operation for Malignant Disease of the Palate.*—There are, unfortunately, very few cures following operations for carcinoma and sarcoma of the palate. In cases followed for some months after operation recurrence is found to have taken place.

## MIXED TUMORS OF THE PALATE

Synonyms: Endothelioma, adenoma, perithelioma, plexiform sarcoma, cylindroma, palatal epithelioma, glandular enchondroma.

**Pathology.**—These are growths of the palate which form a group of tumors having a distinct clinical picture, and being among the rarer tumors occurring in the palate. It is essentially the same tumor which is found in the parotid, and which is known as a mixed tumor.

Volkmann,* in an extensive study, reports at some length 6 cases and tabulates 138 others.

Eisenmenger† records 12 cases in 1894.

Paget‡ records 31 cases.

*Volkmann: Deut. Zeit. f. Chir., vol. xli, p. 1.

† Eisenmenger: *Ibid.*, vol. xxxix, p. 1.

‡ Paget: St. Bartholomew's Hosp. Reports, 1886, vol. xxii, p. 315.

Larabee* presents 9 cases of palatal tumors of this general type, and presents the French view as to their epithelial origin.

Wood,† from a study of the mixed tumors of the salivary glands and palate, concludes that—"There is a group of extremely complicated tumors occurring in the facial region which contain elements from both epiblast and mesoblast in most intimate relation to each other.

Fig. 308.—Sagittal section through the middle of the left upper jaw. The osseous envelop of the tumor and the mucosa, ulcerated at the lowest point, are well shown. A mixed tumor—endothelioma (H. Coenen).

"The complicated structure of the stroma, containing, as it does, elements such as embryonic connective tissue, cartilage, bone, fat, lymphoid tissue, and very rarely striated muscle, is explained most easily by the assumption of an embryonic misplacement of mesoblast.

"The structure of the parenchyma is so slightly characteristic in morphology that its epithelial nature can only be considered probable. The form and relationship of the cells

* Larabee: Arch. Gen. de Méd., 1890, vol. i, pp. 537–677.
† Annals of Surgery, Philadelphia, 1904, vol. xxxix, p. 57.

of the parenchyma do not furnish sufficient data to justify these cells as being of endothelial origin.

"The theory of early embryonic displacement of epiblastic tissue during the process of formation of the parotid and submaxillary glands and the branchial arches may ac-

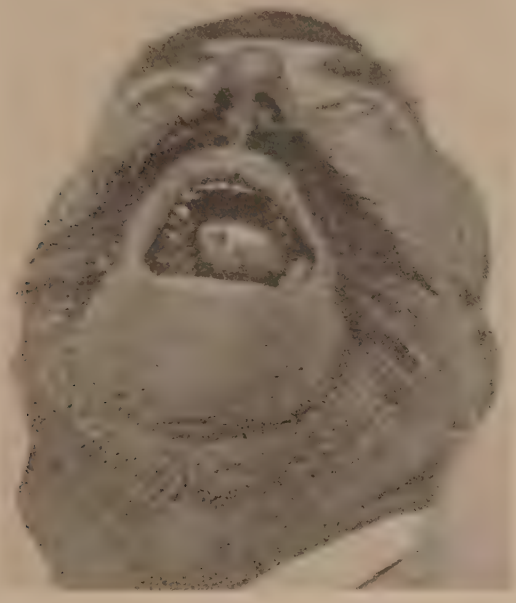

Fig. 309.—Shows a mixed tumor of the palate *in situ*—"a cylindroma." A man, forty-nine years old. Tumor is hard and elastic. Is up against the left alveolus, not touching the right side. The nose is free. There are no glands. Operation, but sufficient time has not elapsed to report (Coenen).

count for many of the morphologic peculiarities of the cells of these tumors, especially the lack of many typical features which we associate with epithelioma."

Three distinct opinions are, therefore, held as to the origin of these mixed tumors: (1) The German pathologists believe

them to be endothelial in origin. Volkmann and his successors hold to this explanation, that they are endothelial in nature and derived from the endothelium of the lymph-spaces; (2) the French school believes that they are epithelial, and derived either from a misplaced portion of the parotid or from a misplacement of the mesoblast and epiblast; (3) there is a third theory, that the tumors contain both endothelial and epithelial elements. This latter theory seems the most satisfactory.

It is difficult to apply a suitable name to this group of tumors. It seems, from a study of the evidence as presented by Wood, that the term mixed tumor is the most satisfactory. As Wood points out—"The problem of the exact nature of these growths cannot be definitely settled so long as we must rest our distinctions upon morphologic or histologic differences."

So far as the explanation of the presence of cartilage in these tumors is concerned, the main weight of the evidence seems to be on the side of the theory of the congenital misplacement of cells which have the power to form either cartilage or myxomatous tissue.

Clinically, these mixed tumors of the palate are found more commonly in the soft than in the hard palate, and upon the left side more frequently than upon the right side. They are never found in the median line. They occur in young and middle-aged individuals, and occasionally in youth and old age; the middle period of thirty-five to fifty seems to be the customary one.

Ordinarily they present as tumors of small size—as large as a walnut, a hazel-nut, or an olive. They are usually rounded or oval, nodular or lobular, circumscribed, slightly

movable, smooth, and elastic, sometimes displacing the uvula. The mucous membrane covering the tumor is smooth, normal in color, and movable, usually without ulceration, and perhaps showing one or two enlarged veins. There is ordinarily no glandular enlargement.

If the tumor contains much fibrous tissue, it is firm. If the tumor contains cartilage and little else, it is distinctly harder. If it be made up of more cellular elements, even with a few scattered hyaline cartilage islets, it is soft to palpation.

These tumors are quiescent tumors, existing possibly unrecognized by the patient for many years. They are usually painless growths. They cause little discomfort until they attain some size, and become, from their mere mechanic presence, disturbing to speech, to deglutition, or to breathing.

As Paget has pointed out, if the tumor advances toward the tonsil, it becomes ill defined, is without its capsule, and this method of growth is a bad sign. If the tumor advances forward, lying in the soft or hard palate, or moves inward toward the median line, it probably will shell out—it can be more readily enucleated than the tumor of the first type.

The lymphatic glands are almost never involved. The metastases of these mixed tumors are local and remote. The local recurrence is of the same type as the original tumor. When the recurrences extend over a long period, the tumor gradually may lose its characteristic morphology and resemble a sarcoma. If the capsule of the tumor is penetrated and the growth is at all vascular, it may recur and spread rather rapidly, thus giving it a malignant type. These cases then resemble sarcomata very closely.

The malignancy of any of these tumors may be intimated

roughly by its physical characteristics. The firm, slowly growing tumors will be most benign, while the softer, more rapidly growing tumors will be malignant. No explanation has yet been given for a sudden change from apparent benignity to one of very great malignancy.

These mixed tumors, if enucleated, do not tend to recur. If, for any reason, they are not easy to enucleate, recurrence is likely.

The 7 cases of enchondromata* and cylindromata recorded by Hoffmann are undoubtedly instances of the mixed tumors described above. Three of these cases had their origin in the soft and 3 in the hard palate. Of the first 3, which seemed to be pure enchondromata, 1 recurred, and the patient finally died after total resection of the upper jaw.

One of the 7 cases occurred in the Jena clinic. He was a man of fifty-six years. The tumor of the palate had existed two years. It was removed by partial excision, leaving the soft palate. Recurrence took place after one month. The Paquelin cautery destroyed this recurrence, and the patient is alive one and a half years after the cauterization, without further recurrence.

### PALATAL TUMORS AT THE MASSACHUSETTS GENERAL HOSPITAL CLINIC

I have discovered 17 cases of palate tumor in the records of the hospital for the last few years. Doubtless other cases have come to the throat department clinic which have never been admitted to the hospital for operative treatment. Of these 17 cases, inquiry was made by letter. Seven letters were returned unanswered. Five cases could not be heard from, leaving a reply from 5 of the 17.

* Langenbeck: Arch. f. klin. Chir., vol. xxxviii, p. 98.

The facts about these 5 cases are as follows:

Case 1.—B. C. Hospital Record, vol. cc, p. 245. Man, thirty-six years old. Had for five months a rapidly growing pedunculated tumor, the size of a small hen's egg, upon the right side of the hard palate. This was removed and recurred one month later, when it was again excised, and the base of the growth cauterized with the actual cautery. The tumor was a benign growth.

Nineteen years later there had been no recurrence of the growth. The man was then killed accidentally.

Case 2.—C. T. P. Hospital Record, vol. cccxciii, p. 174. A man, seventy-three years old, had for two years a slowly progressive ulceration near the posterior edge of the hard palate, just to the median line, with slightly indurated, elevated margin. This ulcer was the size of a nickel. The bone was uninvolved. No cervical lymphatic glands were enlarged.

This man was a constant pipe-smoker and wore a plate of false teeth.

The ulcer was excised. Upon examination it proved to be an epithelioma. Six months later he died of a severe recurrence of the growth. *X*-ray treatment did him no good.

Case 3.—L. A. R. Hospital Record, vol. xxxvii, p. 122. A woman, sixty-nine years old, had for six years a slowly growing tumor on the right side of the soft palate, involving the pillar of the fauces. It was the size of a walnut, firm, resistant, and not tender.

The tumor was excised. The pathologic report from W. F. Whitney, pathologist to the hospital, stated that it was an epidermoid cancer.

Eight years subsequently she reports no recurrence of the tumor of the palate. She has had a second operation for epithelioma of the skin of the eyelid.

Case 4.—M. E. F. Hospital Record, vol. cclxii, p. 214. A woman, twenty-seven years old, had an extensive ulceration of the hard palate for one and a half years. A partial resection of the upper jaw was done. Diagnosis, tuberculosis.

Recurrence in the nose. The palatal tuberculosis has been held in check by constant treatment. She has never been free from the disease during the past seventeen years, but has been under constant treatment, either in this country (America) or in Turkey.

Case 5.—S. E. W. Hospital Record, vol. clxxxvii, p. 253. A boy, eighteen years old, has had a rapidly growing tumor for one year, occupying the front and upper part of the mouth, the hard palate, and involving the space of the three front teeth. The growth has been twice cauterized, but has each time recurred. It was then excised with the underlying bone and true teeth. It was an epithelioma. Twenty-eight years later there is no recurrence and he is in good health.

CASES OF TUMOR OF THE PALATE FROM THE MASSACHUSETTS GENERAL HOSPITAL CLINIC

| Case No. | Sex. | Age. | Location. | Duration. | Operation. | Recurrence. | Pathology. | Result. |
|---|---|---|---|---|---|---|---|---|
| 1 | Male. | 36 | Hard palate (right). | 5 mos. | Excised. Excised, cautery. | Yes. No. | Benign. | Died after nineteen years, accidentally. |
| 2 | Male. | 73 | Hard palate (posterior). | 2 yrs. | Excised. | Yes in 6 mos. | Epithelioma. | Dead six months later of disease. |
| 3 | Female. | 69 | Soft palate. Right side. No ulcer. | 6 yrs. | Excised. | No. | Epithelioma. | Well eight years after. |
| 4 | Female. | 27 | Hard palate. Ulceration. | 1½ yrs. | Partial excision of upper jaw. | Yes. | Tuberculosis. | Living seventeen years later, with extensive disease. |
| 5 | Male. | 18 | Hard palate. Anteriorly (tumor). | 1 yr. | Cauterization. Excised with teeth. | Yes. No. | Epithelioma. | Twenty-eight years later no recurrence. Well. |

# CHAPTER VIII

## LEONTIASIS OSSEA*

CONTENTS OF CHAPTER: Definition.—Etiology.—Pathology.—Symptoms.—Course of the disease.—Treatment.—Relief from cerebral compression: A study of reported cases (Kanavel).—Intervention in cases of contraction of the orbital cavities: Study of case reports (Kanavel).—Involvement of the nasal fossæ.

LEONTIASIS ossea (Virchow) is a localized or diffuse hyperostosis of any or all the bones of the cranium and face. It so uniformly involves the jaws, both upper and lower, that it is very properly considered here. Moreover, there are certain direct operative surgical problems involved, which, although not possible to settle at once, are important to discuss.

Ziegler speaks of the disease as a partial gigantism which affects the bones of the cranial vault, as well as those of the face.

The **etiology** is obscure. The disease usually begins about puberty, with an insidious onset. Virchow believed it might be due to an inflammatory process—possibly to an infection of some sort. A primary trauma, rachitis, tuberculosis, syphilis, a trophic disease, bear no likely relation to the origin of this malady, although each has been thought to be of etiologic moment by different observers.

The disease corresponds to elephantiasis in the soft parts. Acromegaly and von Recklinghausen's disease have little in common with it.

* The material for this chapter has been taken very largely from the recent complete study by Kanavel (Surgery, Gynecology, and Obstetrics, June, 1907).

**Pathology.**—According to Simmons, pathologically, leontiasis has been termed a hypertrophy, a form of new-



Fig. 310.—Case of leontiasis ossea (Beck). A widow, thirty-nine years old; eighteen months' duration. Tissues were removed to relieve pain. No lime salts were present. The finger-tips were bulbous. The bony phalanges were without lime salts.

Fig. 311.—Case of leontiasis ossea. The posterior view of Fig. 310 (Beck).

growth, and an ostitis, but at present it certainly cannot be regarded as either of the first two of these, and there is some question as to whether it is an ostitis, although the changes are strictly

Fig. 312.—Case of leontiasis ossea. Note bulbous fingers and the tumor of upper jaw (Beck).

Fig. 313.—Case of leontiasis ossea. Another view of case in Fig. 312 (Beck).

Fig. 314.—Case of leontiasis ossea. A lateral view of case in Fig. 312 (Beck).

of an inflammatory character. The process begins usually in the upper jaw, near the nasal spine, more commonly on the right side, but it soon becomes symmetric, although it may start in the frontal bone, or, rarely, in the lower jaw. Later, as the disease progresses, all the bones of the face, as well as those of the cranium, are involved to a greater or less extent, the anterior portion showing usually the most change.




Fig. 315.—Drawing from tumor seen in Fig. 312, at its periphery, showing red blood-corpuscles in the lacunar spaces (Leitz obj. No. 7; eyepiece No. 4; tube length, 160 mm.) (Beck).

In the advanced cases the bones are all thickened, and those of the face are distorted, showing hyperostoses and eroded surfaces as the result of periostitis. The skull, on account of this thickening, is much increased in weight, the dried specimen often weighing five kilograms, or five times as much as the normal. (See Figs. 318, 319.) The appearance

of the bone is that which results from an ostitis, and in this respect the skulls somewhat resemble those observed in hereditary syphilis. In the vertex, where the process can best be studied, the bone is often four centimeters in thickness. This new formation of bone takes place on both the inner and the outer tables, with a corresponding increase in the girth of the head and a diminution in size of the brain cavity,




Fig. 316.—Showing microscopic appearance of tissue removed from case seen in Fig. 312 (Leitz obj. No. 3; ocular No. 4; tube length, 170 mm.) (Beck).

into which, at times, small hyperostoses project. The bone is of almost ivory-like hardness, and the diploe is usually obliterated, the growth, therefore, being both an exostosis and an enostosis. In acromegaly and hypertrophic conditions, on the other hand, the relation of the diploe to the cortical bone is approximately normal, and the cortical bone is of normal consistence. At the base of the skull the changes

are, as a rule, very slightly marked, and it is a fact that the foramina are usually of normal diameter in spite of the thickened bone. In some cases the sella turcica has been narrowed, while in others it is somewhat increased in size.

Fig. 317.—*X*-ray of hand of case seen in Fig. 312. Note terminal phalanges. Bone salts have evidently disappeared from terminal phalanges (Beck).

In the upper jaw the pathologic process appears as a diffuse thickening of the entire bone, in the form of enostoses and exostoses, and occasionally as tuberous prominences, the latter being seen near the nasal spine, where the process commonly begins, or over the malar bone. This increase in

the size of the bone may fill up the antrum or block the nasal cavity, in which case necrosis and changes due to secondary infections are commonly seen. If the hard palate is involved, it may be pushed down into the mouth to the level of the borders of the alveolar process, and involvement of the latter is associated with a loss of the teeth. Growth into the orbit from either the superior maxilla, the frontal bone, or the sphenoid causes a narrowing of that cavity, forcing the eye out. In the frontal bone there is often an associated inflammation of the sinus.

The other bones of the body are usually normal, and changes of the soft parts, except those secondary to pressure and sepsis, are practically unknown. Starr, however, mentions a case in which there was some extension of the process to the two upper vertebræ.

Pathologically, then, this disease is a new-formation of tissue resulting in a possible myxo-chondro-osteo-fibromatous new-formation.

**Symptoms.**—The disease usually begins insidiously during the early years of life. Simmons, from a study of the literature, finds that it may begin in the spine of the superior maxilla, causing an appearance of flattening of the base of the nose. From this starting-point it progresses slowly and symmetrically to the frontal bone and jaws.

If the nasal cavity becomes involved, it may be closed, resulting in anosmia, or a nasal discharge dependent upon an infection of the antrum of Highmore.

Neuralgic pains in the face are noticed. Optic neuritis is sometimes found, due to various causes. Epiphora is occasionally present. Proptosis is not uncommon. Certain symptoms due to cerebral compression may exist, viz.,

convulsions, mental impairment even to dementia, headaches. Eye symptoms were notably absent in many of these cases, with symptoms associated with possible cerebral compression. The eye symptoms may have been due to

Fig. 318.—Leontiasis ossea (Army Medical Museum, Washington, D. C.).

changes in the orbital cavities and not to the intracranial compression.

Deafness and vertigo are sometimes present, as well as tinnitus aurium and paralysis of the cranial nerves.

The **course of the disease** is slow, and, according to Kanavel, may become arrested at any stage, while accord-

Fig. 319.—Leontiasis ossea (Army Medical Museum, Washington, D. C.).

ing to Simmons, the disease is always fatal—there is never retrogression.

The symptoms are the deformed appearances and those occasioned by an encroachment of the bony growth upon parts contiguous to it.

**Treatment.***—According to most observers, no treatment is of any avail. When the disease is recognized early and when it is confined to one jaw, excision of that jaw has been done to relieve pressure upon the eye and nose.

No operative procedure is available to cure the disease. Kanavel advocates a decompression operation for the relief of intracranial pressure.

"The most serious sequelæ appear because of contraction of the nasal fossæ, the orbital cavities, and the cranium; the long course of the disease, and its arrest at certain stages, offer hope that if these complications can be removed, the patient's life and general health may be preserved for a number of years, and in case of arrest, permanent relief from symptoms may be hoped for" (Kanavel).

Fifteen of the cases analyzed showed symptoms that might be attributed to cerebral compression. No operation was deliberately planned for the relief of compression.

**Relief from Cerebral Compression.**—Owing to the importance of this question, it will be studied in some detail.

As before mentioned, 15 cases showed symptoms that could be attributed to cerebral compression, but in no case was operation performed with the deliberate intention of relieving it. Kanavel's study of the reported cases is as follows:

The first case of Horsley (case 1) was observed when the patient was nineteen years of age, and he had complained of

* The study by Kanavel (Surgery, Gynecology, and Obstetrics, June, 1907) is here quoted in detail as the latest statement of the facts.

headache, with vomiting and epileptic fits, for five years; there is no history of optic neuritis. The swelling involved the left eyebrow most, but extended to the left parietal and occipital region. The right temporal and parietal bones were distinctly involved. The growth projected into the orbits and pushed the eyes downward. Here was a case in which decompressive operation could undoubtedly have been done with hope of relief, and Horsley himself states that it should have been undertaken.

In Horsley's fourth case (case 3) he had an opportunity to operate upon a patient who complained of pain in both frontal regions. One year later the patient was well, except for pain over the right side. The operation is described in detail later.

Sattler's case (case 8), unfortunately, showed no symptoms of cerebral compression except an optic neuritis, and, owing to the distortion of the orbital cavities and proptosis, this might have been construed as being due to the latter, so that the diagnosis of cerebral compression and the consequent necessity of decompressive operation would have been difficult to arrive at. The patient was active and cheerful until the convulsive seizures and coma developed, which ended in death after the disease had been observed nine years. At postmortem compression of the brain was demonstrated. Operation would certainly seem to have been indicated upon the orbits, and the condition found at operation might have demonstrated the necessity of further operative procedure of decompressive nature, if the possibility of such had been kept in mind by the surgeon.

Keen's case will be mentioned later, under the discussion of operation in the presence of eye signs.

Starr's patient (case 14) complained of numbness and impaired gait. No mention is made as to eye symptoms. All the bones of the skull and face were involved, and the possibility of decompressive operation should be considered. The same should be said concerning Putnam's first case (case 17).

Putnam's second case (case 18) might have been operated upon with hope of relief. The history states that the patient had repeated convulsions, and the mental condition was constantly growing worse. Headaches were frequent. The forehead was prominent, with two broad exostoses or thickenings on the skull, 2½ inches across. The patient had an optic neuritis.

Prince's case (case 21) presented the same indication. This was admitted by Dr. Prince at the postmortem, since, owing to the simultaneous thickening of the orbital plate of the frontal bone and the vertex, the frontal lobes were greatly compressed. Partial atrophy of the right optic nerve was present. There was some proptosis, however.

Wrany's case (case 24) showed cerebral symptoms. The vascular and nerve-canals were not contracted, and it is probable that palliative operation would have given considerable relief to the symptoms and prolonged life.

Schutzenberger's case (case 25) stands as a conspicuous example of possible palliation by decompressive procedures. The patient came under observation because of cerebral symptoms: epilepsy, headache, and final dementia. At postmortem none of the foramina, except the left posterior jugular foramen, was contracted. The anterior portion of the skull particularly was involved.

Kanavel concludes: Thus we see that of the 15 cases men-

tioned as showing symptoms of cerebral compression, there is justification for assuming that palliative operation might have relieved the patients for years, and in 9 of these there were symptoms which should have suggested the advisability of operation. Case 3 was operated upon by Horsley, not with the idea of cerebral decompression, however, while cases 18, 21, 24, and 25 were conspicuous examples of cases that could not only have been diagnosed, but also might have been operated upon with every hope of success.

**Intervention in Cases of Contraction of the Orbital Cavities.**—Kanavel says: The discussion of this phase of the question is of great interest, since definite results can be promised. Of the 34 cases, 17 showed involvement of the orbital cavities. Putnam's cases (3 and 4), Astley Cooper's case, and Stack's cases (cases 9, 19, 20, and 27) showed some thickening of the orbit, but no demonstrable change in the eye or its function. In the remaining 13 the information as to the optic neuritis is often indefinite; the description, however, is as follows:

Horsley (case 1): Eyes pushed downward.

Horsley (case 2): Proptosis of right eye; no diplopia; right eye has only perception of light, and left, impaired vision.

Horsley (case 4): Right eye depressed and somewhat protruded; no diplopia; no change in fundus.

Sattler (case 8): Epiphora at the age of eleven, proptosis of both eyes at the age of fifteen, and optic atrophy, most marked in the left, at nineteen.

Keen (case 11): Eyes pushed downward and forward; no optic neuritis present. This case was operated upon and will be discussed later.

Gunn (case 15): Proptosis; optic disc atrophied.

Putnam (case 18): Eyes prominent; optic neuritis of right eye; eyesight failed years afterward.

Prince (case 21): Eyes prominent; orbital cavities diminished in size, and partial optic atrophy in right.

Edes (case 22): Eyes somewhat prominent; double optic atrophy.

Ribel (case 23): Proptosis after thirty.

Howslip (case 28): Proptosis and impaired vision.

Kanavel continues: Thus we see that involvement of the orbits is an early and progressive change. The eyes are pushed out by the increasing bony deposit, and the frequent association of optic neuritis and displacement of the eyes leads us to consider this as of as much importance as the cerebral compression in the production of blindness.

When we consider the anatomy of the orbit and the relations of its vessels and nerves, we see that a considerable portion can be removed from the outer part and roof, giving relief to the contracted orbit. The removal of bone can be continued over to the optic foramen, releasing the optic nerve and artery if they be compressed. In two cases isolated hypertrophic bone has been removed, incidentally relieving the eye, although that may not have been the primary object of the operation. As long as these patients have been observed, however, no eye symptoms have developed.

Horsley's case (case 4) showed the right eye depressed one-half inch and somewhat protruded. There was no optic neuritis, however, although there was impaired vision, and the operation doubtless prevented changes, for years, at least. The tumor involved the whole frontal region on the right side.

Kanavel's study of the other cases previously classified

demonstrates that an operative procedure could have been instituted in like manner. In Sattler's case, for instance, proptosis developed at the age of fifteen, while optic atrophy did not appear until nineteen. Displacement practically always precedes the destruction of the nerve, and offers a clear indication for operation, with every hope of preserving the function of the eye. Horsley himself states that his first case (case 1) should have been operated upon. It is possible that in cases of extensive involvement operation in stages may be indicated.

**Involvement of the Nasal Fossæ.**—Kanavel finds that this complication is undoubtedly present much oftener than the histories show. While it is not so serious as the preceding sequelæ, yet the patients often complain bitterly of the nasal obstruction and continual discharge which the obstruction produces. Anosmia, while frequently present, would be seldom complained of by the patient. The involvement of the tear-duct is a more serious disaster, for which intervention could probably offer slight hope of relief. Epiphora was noted in 4 cases, and dacryocystitis in 3, this generally being one of the early signs of the disease. In those cases in which the nasal obstruction is complete the relief and satisfaction to the patient are marked, as was demonstrated in Kanavel's own case, where complete anosmia was demonstrated by Kahn and obliteration of both fossæ was present, with a constant purulent discharge. Kanavel does not believe that the antrum of Highmore was involved. The enlargement was so great as to have led earlier observers to diagnose bilateral osteomata. Under complete anesthesia the bony deposits on both sides were chiseled out, giving a free ingress to air. After some weeks of local treatment by Boddinger, the nasal discharge

ceased, and the patient makes no complaint except that he has some earache—whether due to local irritation or to involvement of nerves in bony deposit is still open to question. From a study, cases 2, 13, 23, 26, 27, and 28 might also have been relieved in like manner. The permanence of the relief depends, of course, upon the rapidity of growth. In Kanavel's case the bone had been growing for ten years, at least; seven years previously he had complained of dacryocystitis, so that there is every possibility that some years may elapse before a second operation is indicated.

Other operative attempts to relieve the neuralgia, prevent growth, and relieve deformity have been made as follows: Horsley (case 2) operated to determine whether the branches of the middle division of the fifth nerve were involved. An excision of the jaw was found to be the procedure which offered the best hope of relief, but this the patient would not consent to. The right upper and right lower jaws had been removed five years previously in this case.

The relationship between acromegaly and von Recklinghausen's disease cannot be stated at present. Leontiasis ossea certainly preserves its clinical individuality, although it cannot yet be classified as having a clear pathology.

**A Case of Leontiasis Ossea.**—Reported by James J. Cole, and observed in the clinic of Kanavel at the Postgraduate Hospital in Chicago:

J. W. Male. Age, twenty-two years. Single. Irish-American. The family history shows the presence of tuberculosis, alcoholism, and a probable syphilis in relatives.

The present illness dates back to the age of two and a half years, when he had his first attack. His speech left him, and he dragged both feet. After three months his

speech gradually improved. Unconsciousness did not accompany this attack.

When he was four years old he had his first convulsion, and was unconscious for four hours. The defect in his speech was again noticed, and he dragged both feet more than ever; the right arm was partially paralyzed also. From this time convulsions recurred as often as once a month, accompanied by unconsciousness, up to the time he was eleven years old, but since then, up to the present time, he has had no convulsions.

When the patient was seven years old a small hard swelling was noticed under the right eye, then similar swellings appeared on the lower and upper maxillæ of the left side. These gradually increased in size up to the time of his entrance into the hospital. At this time bilateral exophthalmos was evident, and the patient stated that this had become marked, especially within the last two years.

Pain was present in the head,—more so over the frontal region,—and this pain had increased in severity for a year previous to his entrance into the hospital. For three years he had been unable to breathe through his nose, owing to the encroachment of the bony masses on the nasal cavities. Difficulty in walking, with dragging of both feet and partial paralysis of the right arm, was noticeable at the time he presented himself for treatment.

*First Operation.*—Removal of the excessive growth upon the two superior maxillæ; opening of the nares; enlarging the orbits so as to relieve the pressure upon the eyes. An incision was made along the right edge of the nose and below the right eyelid, making an L-shaped incision. Through this, with a chisel and hammer, the excessive tissue was removed. It was found to be of great hardness, but not like that of ivory. There was little cancelous bone. The excessive bony mass was removed, bringing the contour of the face down to its normal lines. At the upper edge the floor

Fig. 320.—Case of Kanavel and Cole: 1, Before first operation; 2, after first operation; 3, before second operation; 4, after second operation.

of the orbit was removed back into the orbit for a distance of 2½ cm., which seemed to remove the pressure on the eyeball and allow it to sink back into the orbit. Through the same incision,—the nose being retracted to the left,—with a chisel and hammer, an opening ¾ inch in diameter was made directly through the bone to the posterior pharyngeal vault. No evidence was seen of mucous membrane or of the nasal septum. The antra were apparently obliterated. The bone, however, was not of the hardness noted on the surface, and was removed without a great deal of difficulty, which may have been due to a partial cavity further back. The nose was then replaced in position, the skin sutured with a fine subcutaneous stitch, and packing placed in the nose.

On the left side the incision was made parallel with the edge of the normal position of the superior maxilla. Through this incision the excessive bone was chiseled away to bring this side also down to the normal outlines, and the osseous tissue underneath the eye in the orbit was removed in like manner to that on the right, when the eye assumed its normal position.

The wounds healed by primary intention, and the patient was well satisfied with the result upon his nose and the appearance of the face. It is now a year and a half since the operation, and there has been no return of the eye symptoms.

*Report of Eye-findings Before and After Operation (By G. F. Suker)*

(*a*) Bilateral proptosis, more marked on right than left.
(*b*) Marked turgescence of the conjunctival vessels of both eyes.
(*c*) Reduced sensibility in each cornea.
(*d*) Suppurative dacryocystitis on the right side.
(*e*) Marked enlargement of fundus vessels in each eye.
(*f*) Moderate dilatation of each pupil.
(*g*) Moderate choked disc in each eye—more in right.
(*h*) Marked encroachment upon size of orbit, particularly right.
(*i*) Increased palpebral aperture in each side, due to protrusion of globe.

(*j*) Pupillary reactions not prompt and limited in extent; same in both eyes.
(*k*) Slight limitation in excursion of globes.

Subsequent to the operation there was:

(*a*) Recession of proptosis.
(*b*) Return of normal palpebral aperture.
(*c*) Cessation of conjunctival vessel enlargement.
(*d*) Diminution of choked disc.
(*e*) Recession in the enlargement of the fundus vessels.
(*f*) Reappearance of corneal sensation.
(*g*) Apparent normal ocular excursions.
(*h*) Other conditions remained stationary.

*Second Operation.*—Four weeks after the first operation an incision was made underneath the angle of the jaw, the skin retracted, and the excessive bony tissue chiseled away, bringing this side of the face down to the normal outlines. Some doubt was felt as to whether this would relieve the pain, since we could not determine in what nerve it had its seat. It did, however, remove the unsightliness of that side, and the immediate result, at least, was to remove the pain. At the present time, however, he complains of some slight pain on that side, but not so marked as before operation.

*Third Operation.*—About nine months after the first operation the patient began to complain of headache, which had been increasing in severity for two months. The mother also felt that the patient was becoming more irritable and more difficult to control. Following this complaint the patient was examined, and it was deemed advisable to do a decompression operation. Accordingly, a semilunar incision was made on the left side, where an excessive growth of bone just above the ear appeared to be. An incision was made, 2½ inches in diameter, and the flap turned downward, including a portion of the temporal fascia and muscle. From this area, by means of a trephine and later with a chisel, a large area of the cranial bones was removed. In the anterior portion the bone was found to be about one-third of an inch in thickness; at the posterior end of the area, however, the

bone was nearly one inch in thickness. The dura was not opened, and, after removing the bone, the muscles and skin were sutured in place by the usual methods.

Following the operation the patient made an uneventful recovery. His headache ceased, and his mother reported that he was slightly less inclined to his uncontrollable attacks, although in this regard the result was not so marked as in the case of headaches, of which he has not complained since.

In this relation it was noted at the operation that there did not seem to be excessive tension underneath the dura.

At the present writing this patient is beginning again to show obstruction to the nasal breathing, and it is probable that further surgical interference will be necessary to remedy this condition.

# CHAPTER IX

## PROSTHESIS

CONTENTS OF CHAPTER: General observations.—Methods of prosthesis used by—Hahl, of Berlin; Fritzsche; Schröder; Boennecker; Partsch; Hoffmann and Kayser; Garré; Berndt; Bardenheuer; Wölfle; Wildt; König; Magnuson; Sykoff; Krause.—Conclusions regarding prosthesis.

### GENERAL OBSERVATIONS

FOLLOWING operations upon the jaws for the removal of a part or the whole of the upper or lower maxilla it is often wise to introduce some appliance that will fill the gap made in the jaw.

The details of this fitting of apparatus—the prosthesis—have, in this country, been left very largely to the dental surgeon. The operating surgeon is not usually informed as to the different kinds of prosthetic apparatus available. It is in order that the operating surgeon may somewhat understand the principles underlying the choice, manufacture, and application of prosthetic apparatus that this chapter is introduced here.

The surgeon should be familiar with the indications for and against the use of an immediate prosthesis, that is, at the conclusion of the operative removal of the diseased bone. The surgeon should be informed as to why it is better, under some circumstances, to postpone the use of prosthetic appliances until the wound is completely healed (secondary prosthesis).

In any given case the following questions arise:

Is some form of prosthesis desirable?

Shall it be immediate or secondary?

If immediate, what device will meet the requirement in the particular case?

If secondary, when shall it be applied and what apparatus will be best under the circumstances?

Will the particular individual be able to tolerate a foreign apparatus in the mouth constantly?

Will the mouth parts react too violently against the introduction of a foreign body into the tissues?

All these questions must be considered if the operating surgeon would deal successfully with the prosthesis following operation upon the jaws. There are many cases in which apparatus will not be tolerated—cases in which apparatus will not be employed. The post-operative deformity in certain cases will be very slight, and will not need prosthetic apparatus.

Familiarity with the forms of prosthesis available will assist the surgeon in adjusting apparatus to the wound resulting from certain operative technic.

Prosthesis, when employed, is intended—(1) To minimize deformity occasioned by loss of bone and soft parts—*i. e.*, it is used for cosmetic reasons; (2) to preserve the alinement of the teeth, so that chewing or biting may be employed in the mastication of food—*i. e.*, it is used for practical reasons.

Following resection of the lower jaw, the anterior sawn edges of the jaw tend to become approximated. After removal of the symphysis, for instance, not only is the chin less prominent and rounded, but it is more pointed; the two halves of the jaws tend to fall together. (See Figs. 51, 52, 53, 54, Chapter II.)

Immediately after operation for the removal of the symphysis and considerable bone extending back on each side to the angle of the jaw, the attempt to bring the bone remaining together so constricts the floor of the mouth and the parts posteriorly at the base of the tongue that respiration may be interfered with. Some apparatus is needed to keep these inferior maxillary bones apart and in their normal relations.

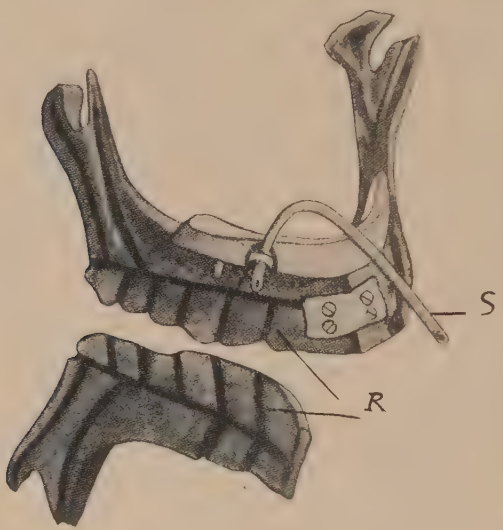


Fig. 321.—Immediate prosthesis (O. Martin) for exarticulation of one-half of the lower jaw. Apparatus is split to exhibit the system of channels for irrigation, *R*, and the rubber tube for introducing irrigation fluid, *S*.

If one half of the lower jaw is removed, the remaining half of the bone is approximated to the midline by the unopposed contraction of the internal pterygoid muscle of that same side. Not only does the primary pull of the pterygoid displace the bony stumps, but the subsequent cicatricial contraction adds its quota to the permanent deformity.

The use of an immediate prosthesis—*i. e.*, introduced into the mouth at the time of the operation, which may be replaced by a more permanent and durable splint at a later period—is described by Martin-Ollier, of Lyons, France.

The use of a prosthesis after the wounds are healed is advocated by Sauer-von Tropmann, of Berlin.

There are, of course, many modifications of these two

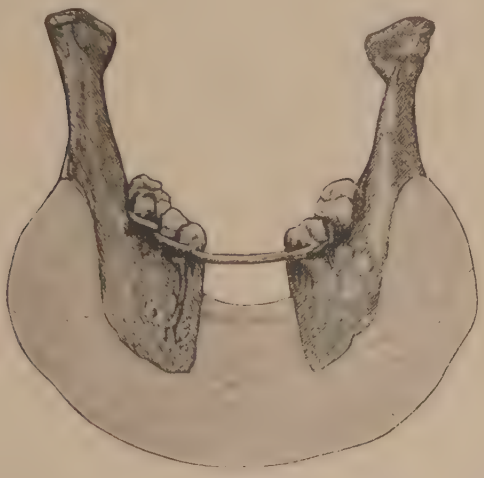

Fig. 322.—If two or three teeth remain in the jaw, it is possible to hold the two halves of the jaw apart by a heavy wire which is fastened about the teeth or fastened to a tooth-cap (Hahl).

fundamentally different methods. The more important modifications will be mentioned.

Ollier and Martin recommend the replacing of the defect at the time of the operation by an apparatus made of hard rubber, fixed *in situ*, and superseded by a smaller removable apparatus after healing has taken place.

In certain cases this apparatus may loosen teeth. The

attachments may have to be changed, and caps may have to be used.

The apparatus for the lower jaw, in cases of complete removal of one-half of the jaw, fits into the glenoid cavity directly. It is united to the bony stump by suture. It is cleansed by irrigation through many channels (Fig. 321).

Bergmann and Sauer apply prosthesis after healing is

Fig. 323.—Prosthesis used for replacing the symphysis. Note the elliptic plate to hold forward the chin. Note the metallic pins which, penetrating the cut surfaces of the two rami, hold the splint in firm position (Hahl and Witzel).

complete. A cast is taken by a dentist before operation, so as to have a guide as to the part to be replaced.

The splint rests in the mouth and is uncovered. The risk of infection of the buccal cavity is comparatively slight if the apparatus is kept clean. The apparatus should be cleaned and replaced immediately. If it is left out long it is difficult to replace it.

## METHODS OF PROSTHESIS

Hahl reports the methods of prosthesis employed in Berlin from 1887 to 1899 in the group of 45 lower and 81 upper jaw resections. The methods of use of prosthesis in these cases may be grouped as follows:

*First Group:* Those cases in which the chin or symphysis is removed. A wire of gold, aluminum, bronze, or nickeled steel is set in the place of the resected bone. If there are

Fig. 324.—If there are teeth only in one-half of the remaining jaw, then the above method may be used (Hahl).

teeth, the wire is wound about them to secure support (Fig. 322). If there are no teeth, then Boennecken's wire bridge, embracing the stumps of the teeth, is used, or a spindle-shaped metal body to support the lower lip, with two sharp ends which may be pushed into the bone and fastened by ligature, is used. (See Fig. 323.) As soon as healing is completed the wire splint is removed and a broad, hard-rubber splint with

ring-like processes is attached to the stumps, and is held by a special spring to an upper plate.

*Second Group:* Those cases in which a partial resection in continuity was done of part of the lower jaw. Into the gap thus formed was placed a piece of gold or aluminum bronze, about the size of a lead-pencil, the pointed ends becoming fastened directly into the spongiosum of the stumps of the bone. This usually healed *in situ.* (See Figs. 323 and 327.)

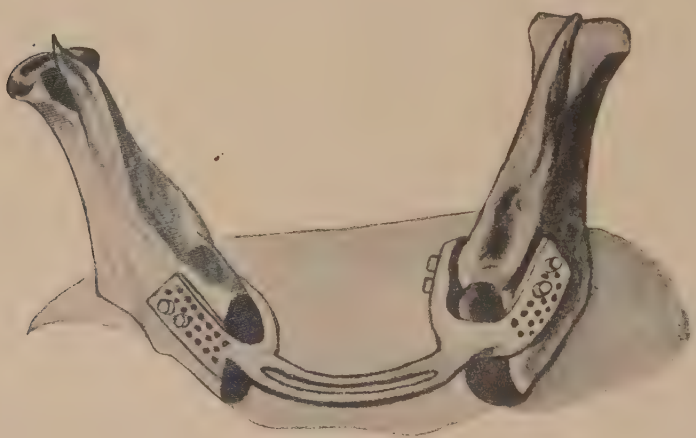

Fig. 325.—Apparatus intended to fill the gap made by removal of the symphysis of the lower jaw (after Boennecken).

*Third Group:* Those cases from whom the whole half of the jaw was removed. The slanting splint of Sauer was used here, in order to keep the jaw remaining over on the sound side. This splint was put in place at the time of the operation.

Fritzsche* suggests a tin splint, imitating as closely as possible the shape of the removed part of the jaw. (See Fig.

* Deut. Zeit. f. Chir., 1901, vol. lxi, pp. 560–576.

331.) This is inserted at the original operation, and sewed in place by splint carriers, which are wired to the jaw fragments. The splint, which is cast beforehand from a plaster mold, can be removed at each dressing and cleaned. When the jaw is exarticulated, a condyloid process is made on one end of the splint, and this fills the glenoid fossa. After three

Fig. 326.—An upper plate for a defect in the upper jaw, attached to the lower hard-rubber plate by means of springs (Boennecken).

or four weeks this splint is replaced by a permanent prosthesis of hard rubber, molded in the same form, which can be easily removed and reinserted by the patient.

Schröder improved somewhat upon the Fritzsche splint.

In resections of the toothless lower jaw associated with separation in continuity, in cases in which there is no ex-

articulation,* Boennecken recommends a metal splint with two ring-like processes on each side (Fig. 325). These embrace the stumps of the jaw. The stumps and the rings are bored through on each side, and the splint is secured with screws. After complete healing the splint is removed and the defect filled with a permanent prosthesis. This method was much improved by Hahl.

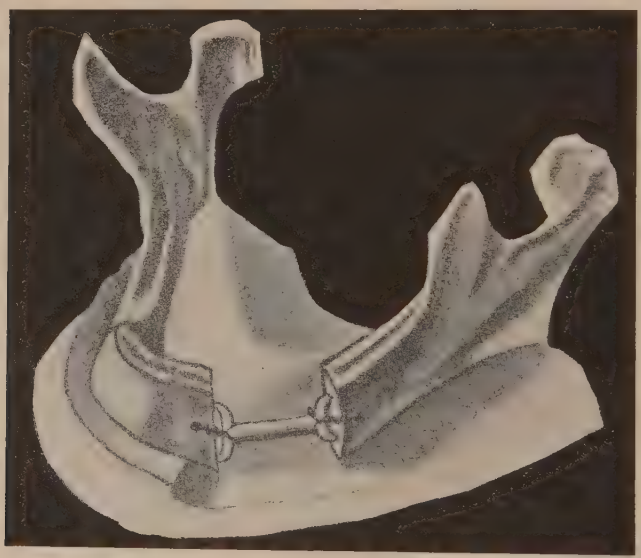

Fig. 327.—An aluminum bronze plate having forked teeth to penetrate the bone on either side of the gap made by the excised bone (Hahl).

Partsch† employs small perforated strips of metal, secured to the jaw-stumps by wire, as an immediate appliance to prevent contractions and displacements during healing, which is not at all impeded by their presence. When the wound closes, they are removed and replaced by a permanent

* Verhandl. d. Deut. odont. Gesellsch., vol. iv.

† Langenbeck: Arch. f. klin. Chir., vol. lv, p. 746.

prosthesis, secured in position by hard-rubber clamps fitting over appropriate metal crowns applied to the teeth (Fig. 329).

It is important to suture the mucous membrane over

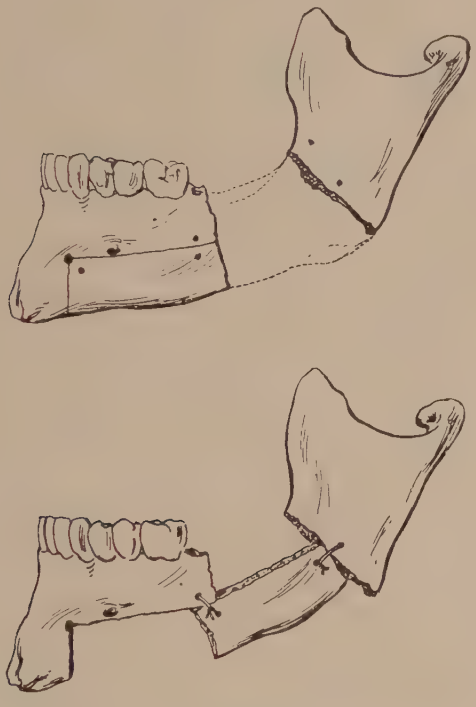

Fig. 328.—Bardenheuer's method of autoplasty to fill a defect in continuity of the jaw.

the splint with great care, in order to shut off the wound as far as possible from the oral cavity.

Hoffmann and Kayser* believe wire the best suture material for plastic repair of the lower jaw, and find that it heals in well, even in granulating wounds. They also employ

* Centralbl. f. Chir., 1904, vol. xxvii, p. 1145.

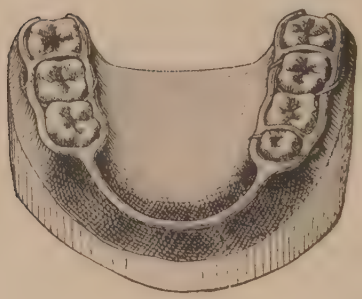

Fig. 329.—The symphysis is gone. A method for bridging the defect (Partsch).

Fig. 330.—An apparatus which is wired to the jaw-stumps. Used for symphysis defects. Perforated with holes for purpose of irrigation (Stoppany, Schlatter).

silver wire as a heteroplastic material, to fill in larger defects, and think such use better than autoplasty. Hoffmann describes a plastic operation in a thirteen-year-old boy for extensive necrosis which had destroyed the left angle of the lower jaw and the ascending ramus as far as the articular process. After removal of all carious material the upper and lower teeth were 2 cm. apart. A wire was then passed from without inward through a drill-hole in the articular

Fig. 331.—Parts of a splint to be constructed by fastening together with pins, to occupy the place of a resected lower jaw (Fritzsche).

process of the lower jaw, and the inner end carried within outward through a drill-hole in the stump of the horizontal ramus, and twisted with the other free end. This wire prosthesis, bent so as to reconstruct an angle for the jaw, soon became covered with granulations, and healed firmly in place, with excellent restoration of function. By this method he was able to restore more than half the lower jaw.

Garré uses and buries a thick, properly shaped piano

wire, fastened to one end of the divided jaw; the bent end or loop end articulates well without too great irritation.

Berndt* believes metal unsuitable for bone plastics, and

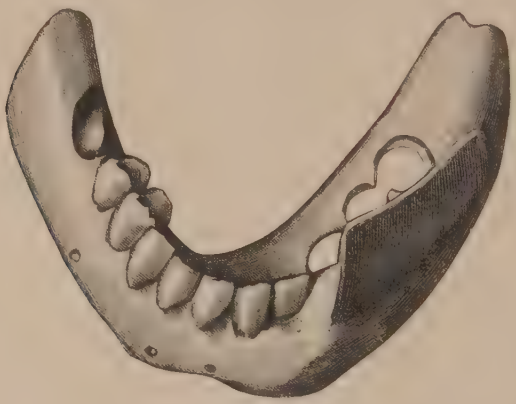

Fig. 332.—Sauer's vertical plate attached to a permanent lower jaw splint. The vertical plate prevents slipping of the apparatus.

thinks celluloid is the best heteroplastic material, on account of its sterilizability and low specific gravity. He uses the common celluloid ring employed for pessaries, which is

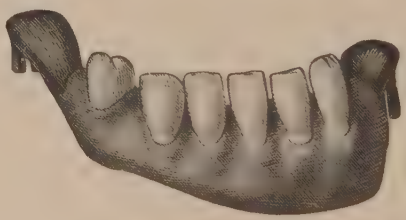

Fig. 333.—Martin's permanent prosthesis, to be applied after the removal of the temporary apparatus.

sterilized and made flexible by boiling, and can readily be bent into the form of the resected half of the jaw. This is placed in the wound and secured by packing, with secondary

* Langenbeck: Arch. f. klin. Chir., vol. lvi, p. 208.

suture after a few days. He reports 4 cases in which this method was applied, with excellent result: the prosthesis healed in place, though generally with a fistula for a time. Essential to healing is closure of communication between wound and buccal cavity; if this is not attained by primary suture of the mucous membrane, it is better to delay insertion of the prosthesis until granulation has begun.

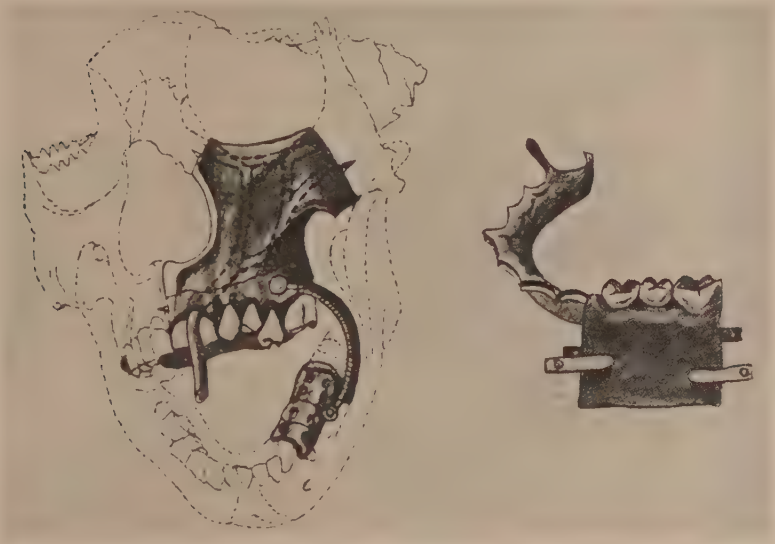

Fig. 334.—Ollier Martin's primary rubber apparatus for use after resection of the upper jaw. This is secured in position by screws and clamps and a lateral spring.

Bardenheuer* employs an osteoplastic flap from the forehead in certain suitable cases to fill in a bone-gap.

Wölfle† uses also an autoplastic flap, but he employs the skin of the neck and a piece of the clavicle.

Wildt‡ describes a method of Bardenheuer for replacing

* Langenbeck: Arch. f. klin. Chir., 1892, vol. xliv, p. 604; vol. xliii, p. 32.
† Centralbl. f. Chir., 1892, p. 80.
‡ *Ibid.*, 1896, No. 50, p. 1177.

a unilateral defect of the lower jaw. He removes a rectangular piece of bone, covered with periosteum, connected below and behind with the musculature, from the horizontal ramus of the jaw of the same side. This piece of attached



Fig. 335.—In case of removal of upper jaw, a vertical plate of sheet tin, covered by hard black rubber attached to a palate and horizontal plate bearing teeth, is used. This is held in position by a spring connection with clasps about the teeth of the lower jaw (Hahl).

bone is pushed backward into the defect and secured by wires passed through the holes previously drilled. (See Fig. 328.)

Others have used a transplanted, resected bit of rib to replace the bony defect following resection of the jaw. In one instance the rib was temporarily turned up in the skin-flap, and subsequently transferred to the jaw with a flap of

skin. In another instance a transplantation of periosteally covered resected rib was done.

König has successfully employed an ivory splint.

Magnuson* has demonstrated that ivory will heal kindly *in situ*, and that it will be replaced by bone.

Fig. 336.—Shows a plaster cast of the defect in the upper jaw, for which the apparatus (Fig. 335) was devised (Hahl).

Sykoff† has taken bone in a similar fashion from the right half of the jaw to fill a defect in the chin or symphysis.

Krause‡ employs skin-muscle-periosteum-bone flaps, taken from the lower border of the intact half of the lower jaw, and operates in two sittings: at the first he introduces a piece of ivory into the defect, the actual plastic work being done at the second sitting, in order to have reliable aseptic conditions.

* University of Penn. Med. Bull., 1908, vol. xxi, p. 103.

† Centralbl. f. Chir., 1900, No. 35, p. 881.

‡ *Ibid.*, 1904, No. 25, p. 767.

Fig. 337.—Permanent apparatus for upper jaw resection (see Fig. 338) (after Hahl).

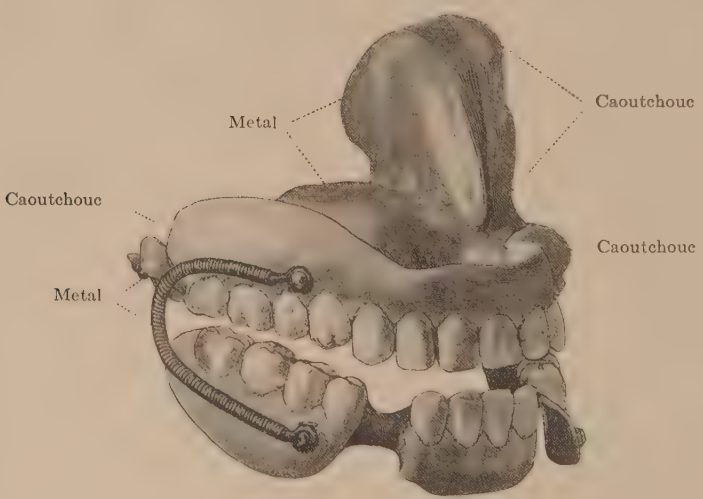


Fig. 338.—Permanent apparatus for resection of the upper jaw; orbital plate removed. The plate is made of aluminum bronze; the projecting knob is hard rubber covering sheet tin. This is attached by lateral springs to the teeth of the lower jaw (after Hahl).

Fig. 339.—Sarcoma of left lower jaw. Removed by resection of the left lower jaw. Prosthesis permanent (von Eiselsberg).

Fig. 340.—Same as Fig. 339.

Fig. 341.—Man, sixty-four years old. Carcinoma of lower jaw. Resection. Prosthesis. No recurrence after one year and a half (Pichler and Ranzi).



Fig. 342.—Same as Fig. 341 (Pichler and Ranzi).

## CONCLUSIONS REGARDING PROSTHESIS

If the defect remaining after operation upon the lower or upper jaws causes deformity or loss of function, this resulting deformity or loss of function should be overcome. Some form of prosthetic appliance should be employed. The temporary prosthesis should be followed by a permanent appliance. The permanent prosthesis ordinarily may be applied about one month or six weeks after the operation.

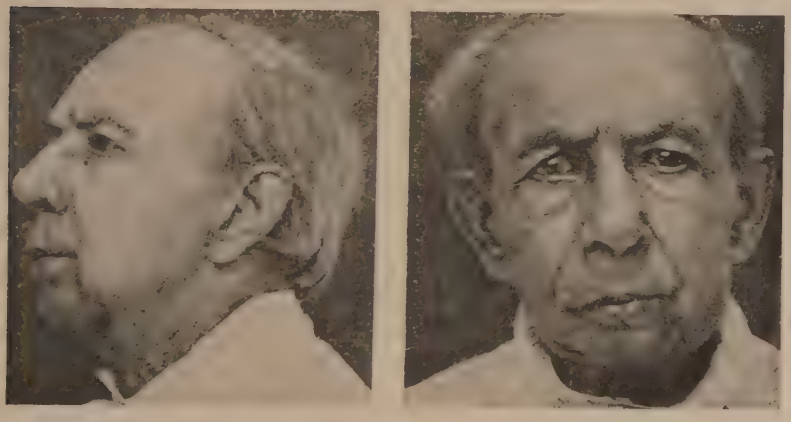

Fig. 343.—Carcinoma of floor of mouth and resection of the symphysis. Prosthesis (König).

The exact form of the prosthetic appliance will necessarily depend upon the conditions in each case. The material of which the temporary or permanent apparatus is made has been a matter of experiment. Hard rubber, magnesium, celluloid, fresh animal bone, old sterile bone, ivory, silver, aluminum, and other metals have all been tried. The simplest apparatus and the least irritating is best. Ivory and a small strong wire seem to meet best the requirements of a permanent and temporary prosthesis respectively.

Fig. 344.—Prosthetic appliance used in case shown in Fig. 343. *P*, the part under the tongue, and attached by *h* to sound teeth in the right side; *z*, artificial teeth in plate; *G*, the part articulating with the glenoid fossa, and forming the ascending ramus of the jaw (König).

Fig. 345.—Removal of one-half the lower jaw on the left side. Prosthetic appliance in place (case of König).

# INDEX OF NAMES


Albarran, 177, 222
Albert, 322
Allen, 92
Andrews, 174

Balch, 55, 56, 57
Bannister, 32, 33
Bardenheuer, 363, 367
Barrie, 197, 202, 208, 209, 211, 212
Batzaroff, 42, 55, 102, 242, 246, 260
Bauchet, 141, 144
Bayer, 55, 283
Beach, 61, 69
Beck, 334, 335, 336, 337, 338
Becker, 197
Beckmann, 283
Behm, 42, 55, 242, 282
Bellocq, 295
Bergmann, 115, 305, 358
Berjor, 146
Berndt, 366
Bigelow, 158
Billroth, 115, 322
Birnbaum, 42, 55, 242, 260
Bland-Sutton, 162, 234, 239
Blauel, 140, 143, 145, 323
Bloodgood, 17, 18, 20, 21, 22, 29, 30, 38, 39, 44, 52, 53, 54, 59, 65, 94, 123, 124, 126, 136, 177, 185, 186, 188, 189, 197, 198, 199, 208, 209, 214, 215, 253
Bockenheimer, 300
Boddinger, 347
Boennecken, 359, 360, 361
Bolles, 239
Bordenaave, 144
Borhaupt, 160
Borst, 197
Braun, 260
Broca, 30, 143, 209, 239
Brown, 121, 156, 212, 237, 238
Bryant, 83, 88, 292
Butlin, 83, 110, 114, 117, 118, 257

Cabot, 236
Chibret, 195, 197
Coenen, 326, 327
Cole, 348, 350
Coley, 58, 60, 65
Comisso, 83, 283
Conant, 279
Cooper, 345
Cousins, 217, 220, 221
Crile, 290, 293, 295
Cusack, 117

Darnell, 250
Dauphin, 41
Depaye, 304
Dieffenbach, 297
Donogany, 250
Dudley, 64, 80, 81, 82, 208, 209, 213, 249, 259, 260, 261, 266
Dupuytren, 117, 198

Eberth, 293
Eckert, 156
Edes, 346
Eiselsberg, 371
Eisenmenger, 322, 325
Elliot, 267

Enderlen, 304
Estlander, 41
Eve, 118, 239

Ferguson, 296, 297
Friedman, 323
Fritzsche, 360, 365
Fuchs, 261, 263

Garré, 304, 365
Gosselin, 295
Greenough, 241, 278
Gruet, 24
Gunn, 345
Gunzert, 24, 38
Gussenbauer, 261, 264, 322, 323
Gussenbaum, 98, 99

Haasler, 35
Hahl, 357, 358, 359, 362, 368, 369, 370
Halsted, 59, 185, 188, 189, 214, 215
Harrington, 248
Heath, 31, 117, 141, 142, 143, 144, 145, 148, 149, 150, 153, 222, 239, 321
Heisler, 239
Hertle, 304, 305
Hildebrand, 195, 196
Hingston, 146, 147, 148
offmann, 305, 330, 363, 365
ofmokl, 283
Horsley, 342, 343, 345, 347, 348
Howslip, 346

Jacobson, 325

Kahn, 347
Kanavel, 333, 341, 342, 344, 345, 346, 347, 348, 350
Kaposi, 103, 117, 255
Kayser, 363
Keen, 298, 343, 345
Killian, 245, 314
Kocher, 303, 304
König, 41, 84, 86, 101, 103, 108, 113, 115, 136, 139, 235, 261, 263, 264, 301, 369, 373, 374
Krause, 193, 194, 196, 197, 369
Kritz, 141
Krönlein, 102, 260, 263, 283
Kuhlo, 197
Kuhn, 305
Küster, 88, 91, 99, 102, 142, 260, 283
Küttner, 318

Langenbeck, 330, 362, 366, 367
Larabee, 326
Latham, 171, 173, 176
Lawson, 150
Lesser, 293
Levi, 65
Liebold, 323
Lipps, 293
Liston, 30, 31, 142, 143
Lothrop, 281
Lücke, 117
Lund, 54
Luther, 65

Madelung, 292
Magitot, 198
Magnuson, 369
Malassez, 172, 173, 197, 207, 208, 21 228
Maljutin, 250
Marburg, 322
Marshall, 163, 164, 165, 166, 167, 168, 169, 170, 171, 172, 173, 174, 175, 176
Martens, 42, 55, 84, 86, 87, 88, 91, 99, 100, 101, 103, 106, 113, 114, 139, 197, 235, 242, 245, 257, 260, 261, 282, 283, 291
Martin, 356, 366, 367
Matas, 134, 294
McCaw, 324
McCurdy, 24, 25, 27
Mears, 119
Meller, 240, 281

Menzel, 144, 155
Michelson, 322
Mikulicz, 74, 212, 251, 322
Mixter, 92, 93, 94, 266
Moore, 149
Morestin, 282
Mosetig-Moorhof, 234

Nélaton, 58
Nimmier, 140
Noyes, 175
Nussbaum, 295

Ohlemann, 260, 283
Oliver, 197
Ollier, 357, 367
Onodi, 230, 231, 313, 315, 316, 317, 318

Paget, 198, 319, 325, 329
Partsch, 26, 220, 226, 227, 232, 362, 364
Payr, 304
Perthes, 23, 26, 30, 34, 45, 138, 139, 141, 143, 145, 151, 152, 155, 156, 157, 223, 226, 229, 231, 232, 233, 234, 283
Petzold, 260, 283
Pilcher, 372
Pincus, 197
Pirogoff, 292
Piscocek, 141
Porter, 79, 84, 114, 116, 150
Prince, 344, 346
Putnam, 344, 345, 346

Rabe, 87, 88, 90, 91, 283, 295
Ranji, 372
Reyher, 292
Ribel, 346
Richardson, 134, 281
Riedel, 247
Riese, 292
Rigaud, 144
Rogers, 187, 202, 213
Rose, 292, 295
Rosenbach, 295

Salter, 38
Sattler, 343, 345, 347
Sauer, 357, 358, 360, 366
Scannell, 281
Schimmelbusch, 293
Schlatter, 255, 283, 292, 364
Schmidt, 42, 55, 146, 242
Schoenborn, 293
Schröder, 361
Schulz, 142, 283
Schutzenberger, 344
Schwenn, 250
Scudder, 278, 280
Senger, 293
Senn, 140,
Simmons, 334, 339, 341
Sirantoine, 197
Smith, 324
Southam, 158
Stack, 345
Starr, 339, 344
Steele, 88, 90
Steensland, 190, 191, 192, 196
Stein, 42, 55, 115, 240, 242, 260, 263, 282
Stoppany, 364
Streissler, 304, 305
Suker, 351
Sutton, 162, 234, 239
Sykoff, 369

Thompson, 151
Tomes, 239
Trendelenburg, 108, 252, 295
Treves, 322, 323
Tropmann, 357
Troutman, 250

Verneuil, 295
Vidal, 153

Virchow, 41, 140, 333
Vitaul, 323
Volkmann, 67, 157, 322, 325, 328
Von Bergmann, 115, 305, 358

Warren, 67, 108, 182, 201, 241
Wassermann, 38
Webber, 118, 296
Westmacott, 158, 159, 160
Whitney, 19, 20, 21, 46, 55, 62, 67, 70, 76, 85, 96, 122, 130, 132, 178, 179, 184, 218, 331
Wildt, 367
Williams, 42
Winiwarter, 260, 283
Witzel, 233, 358
Wölfle, 367
Wood, 326, 328
Wrany, 344
Wright, 62, 70, 149

Ziegler, 333
Zimmerman, 292
Zuckerkandl, 142

# INDEX


Abscess, alveolar epulis and, differentiation, 35
Accessory sinuses, carcinoma of, 250
Actinomycosis, epulis and, differentiation, 35
Adamantine epithelioma, 173. See also *Epithelioma, adamantine*
Adamantinoma, 175. See also *Epithelioma, adamantine*
Adenocarcinoma, 175. See also *Epithelioma, adamantine*
Adenoma of palate, 325
Adenosarcoma, 175. See also *Epithelioma, adamantine*
Aluminum bronze plate with forked teeth, 362
  wire prosthesis, 359
Alveolar border, 170
    carcinoma of, 248
  osteoma, 158
  periostitis, sarcoma and, differentiation, 79
Alveolo-dental periosteum, 171
Alveolus, normal, 159
Ameloblastic layer of teeth, 169
Anatomy of sinuses of nose, 313
Anesthesia, 290
  by nasopharyngeal tubage, 290, 295
  morphin before, 289
Angiosarcoma of lower jaw, inoperable case, 129
Anosmia in leontiasis ossea, 347
Antrum, carcinoma of, 250
    case, 241, 242, 253
  empyema of, in sarcoma and, 74, 78
Antrum, growths starting from, gaining access to, 97
  osteoma of, 156
  sarcoma in, treatment, 138
Aspiration pneumonia after operation, 292
Assistants for operation, 291
Autoplastic flaps, 367
Autoplasty, Bardenheuer's, 363

Balloon, Bellocq's, in operation, 295
Bardenheuer's autoplasty prosthesis, 363
  method for unilateral defect of lower jaw, 367
Bellocq's balloon in operation, 295
Benign lesions following trauma, 64
  tumors, 140
Boennecken's metal splint, 360, 362
  wire bridge, 357, 359
Bone prosthesis, 367

Cannula, tampon, in operation, 295
Carcinoma, 240
  adamantine epithelioma and, differentiation, 187
  age and, 241, 243
  bulging of antral wall in, 252
  central, of lower jaw, origin, 245
    of upper jaw, origin, 245
  course, 259
  cystic, 175. See also *Epithelioma adamantine*
  diagnosis, 259, 284
  edema of eyelid in, 256

Carcinoma, epulis and, relative frequency at different decades, 241–244
etiology, 247
extension anteriorly, 253
toward base of pyramid, 254
upward, 254
face ulcer and, 258
frequency, 240
gum ulcers and, 257
inoperable, case, 265
lymphatic involvement, 256
metastatic, 246, 258
mouth ulcerations in, 257
nasal hemorrhages in, 256
polypi and, 249
obstruction of tear-duct in, 256
of accessory sinuses, 250
of alveolar margin, 248
of antrum, 250
case, 241, 242, 253
of floor of mouth, prosthesis, case, 373
of lower jaw at symphysis, case, 259
Boston City Hospital cases, 281
case, 245, 261, 262, 266
diagnosis, 284
from sarcoma, with lymphatic involvement, case, 119
inoperable cases, 267
duration of life, 270
Massachusetts General Hospital cases, 272–281
metastases in, 258
operated on, cases, 272
death from, cases, 273
operation, 259
patients alive, 277
origin, 245
prosthesis, case, 372
recurrence, death from, cases, 274
remains of, 263
of mucous membrane, epulis and, differentiation, 36
Carcinoma of nasal fossæ, 250
of orbit, 250
of palate, 323
removal, 324
of upper jaw, Boston City Hospital cases, 281
case, 241, 242, 248, 252, 254, 256, 282
diagnosis, 284
inoperable cases, 267
duration of life, 270
Massachusetts General Hospital cases, 264–272
metastases in, 258
operated on, cases, 266, 270
operation, 259, 288
statistics, 283
origin, 245
summary of cases, 263
time of death after treatment, 264
ulcerating, case, 255, 257
of uvula, 323
operation for, 259, 288. See also *Operation*
origin, 244, 250
pain in, 251
plugging of nares, 254
prognosis, 282
recurrences, 260
time of, 282
sarcoma and, differentiation, 81
relative frequency, 43
at different decades, 241–244
sex and, 241, 243
symptoms, 250, 251
treatment, 259
results, 260
time of death after, 264
vision and, 254
Caries, epulis and, differentiation, 35
Carotid, common, compression of, 294
temporary, 293, 294
ligation of, 292, 294
external, compression of, 293, 294
ligation of, 293, 294

Carotid, external, ligation of, cerebral embolism after, 130
internal, ligation of, 293
ligation, brain symptoms, 292
historic, 291
in operation, 291
Cauterization of epulis, 37, 38
Cell-rests of teeth, 172
Celluloid for plastic repair, 366
Cementoma, 234
Central sarcoma, 44. See also *Sarcoma, central*
Cerebral compression in leontiasis ossea, 339
relief from, 342
embolism after ligation of external carotid, 130
Chîbret's work with adamantine epithelioma, 195
Chloroma of jaw, 24, 25
Chondroma, 146
age and, 147
benign, 146
calcification, 148
classification, 146
craniofacial, case, 149
glandular, of palate, 325
malignant, 147
of lower jaw, starting-point, 147
of orbit, recurrent, case, 149
of upper jaw, case, 150
starting-point, 147
operation for, recurrence, 150
origin, 146
rate of growth, 148
starting-point, 147
symptoms, 150
treatment, 151
Chondrosarcoma, 48, 51
Common carotid, ligation of, 292. See also *Carotid, common*
Compression of carotid in operation, 293, 294
Cord, epithelial, development, 165, 166
Craniofacial enchondroma, case, 149
Crile's nasopharyngeal tubage anesthesia, 290, 295
Cuspid, development, 169
section of, 176
Cylindroma of palate, 325
Cystadenoma of jaw, 175. See also *Epithelioma, adamantine*
papillary, from tooth-follicle, case, 215
Cysts, 197
bibliography, 239
dental, 223
case, 224
diagnosis, 224
rate of growth, 224
sarcoma and, differentiation, 80
section, 225
situation, 224
size of, 223
treatment, 225
dentigerous, 197
adamantine epithelioma and, 184, 219
differentiation, 184, 185
epithelioma with, 184, 186, 188, 189
age and, 198
contents, 211
diagnosis, 218, 284
etiology, 203
heterotopic, 198
lining membrane, 212
Malassez's theory, 207
multilocular, 175, 214. See also *Epithelioma, adamantine*
of lower jaw, 197
case, 200, 201, 202, 203, 204, 208, 209, 213, 222, 223
diagnosis, 284
of upper jaw, 197, 201
case, 198, 199
diagnosis, 284
pathology, 210
position of tooth in, 207
rate of growth, 199
situation of, 202

Cysts, dentigerous, tooth in, 211, 212
toothless, 212
tooth-like masses in, 219
treatment, 220
walls of, 211
epulis and, differentiation, 35, 36
follicular, 197. See also *Cysts, dentigerous*
periosteal, 197, 226. See also *Root-cysts*
root-, 197, 226. See also *Root-cysts*

Dental abscess, epulis and, differentiation, 35
cysts, 223. See also *Cysts, dental*
Dentigerous cysts, 197. See also *Cysts, dentigerous*
Dermoids, 212
of palate, 319
removal, 324
Diagnosis, 284
age in, 285
character of tumor in, 287
duration of growth in, 285
history in, 284
jaw involved in, 286
rate of growth in, 285
sex in, 285
situation of growth in, 285
trauma in, 287

Embolism, cerebral, after ligation of external carotid, 130
from ligation of carotid, 293
Embryo, lower jaw of, 164
Empyema of antrum, sarcoma and, 74, 78
Enamel organ, development, 166, 167
hood of, 169
Enchondroma. See *Chondroma*
Endothelioma of palate, 325
Enlarged glands of neck, 80, 81
Enucleation of eye in sarcoma, 114

Epithelial cord, development, 165, 166
odontoma, 175. See also *Epithelioma, adamantine*
rests of teeth, 172
Epithelioma, adamantine, 173
age and, 176
carcinoma and, differentiation, 187
characteristics, 184
Chîbret's work, 195
clinical course, 175
dentigerous cyst and, 184, 219
differentiation, 184, 185
dentigerous cyst with, 186, 188, 189
diagnosis, 184, 284
epulis and, differentiation, 36, 185
Hildebrand's case, 195
Krause's description, 193
of microscopic pathology, 193
lymphatics in, 181
mucous membrane of, 181
of lower jaw, case, 177, 178, 179, 180, 182
diagnosis, 284
of upper jaw, 178, 185
diagnosis, 284
origin, 173
pathology, gross, 187
microscopic, 191
prognosis, 196
rate of growth, 180
recurrences, 196
relation to jaw, 180
rupture into mouth, 184
sarcoma and, differentiation, 187
sex and, 177
situation, 177
size, 180
synonyms, 175
treatment, 195
of palate, 323, 325
removal, 324

Epulis, 17
actinomycosis and, differentiation, 35
adamantine epithelioma and, differentiation, 36, 185
age and, 242, 243
of occurrence, 18
alveolar abscess and, differentiation and, 35
beginning period, 24, 25
carcinoma and, relative frequency at different decades, 241–244
carcinoma of mucous membrane and, differentiation, 36
caries and, differentiation, 35
causes, local, 18
cauterization, 37, 38
consistence of, 32
course, 33
cyst and, differentiation, 35, 36
definition, 17
dental abscess and, differentiation, 35
diagnosis, 35, 284
epithelioma and, differentiation, 36
established period, 24, 27
excision, 37
extraction of tooth in, 37, 38
fibrous, 20
consistence of, 32
diagnosis, 37
large size, 30–32
prognosis, 34
treatment, 37
fungosity of gums and, 35
giant-cell sarcomatous, 21
diagnosis, 37
prognosis, 34
treatment, 37
granulomata and, differentiation, 35
gum-boil and, 30
differentiation, 35
in pregnancy, 24
large size of, 30–32
liability of two jaws, 18
lymphatic involvement, 35
Epulis, malignancy of, 17, 19, 20, 35
metastases in, 38, 39
neuralgia and, differentiation, 35
odontoma and, differentiation, 35, 36
of upper jaw, 30
oozing of blood from, 32
operation for, 38
palpation, 32
papillary growths and, differentiation, 35
periods in growth, 24
periostitis and, differentiation, 35
prognosis, 34
pushing out of teeth by, 19, 25
recurrence after operation, 37, 38, 39
retained wisdom teeth and, differentiation, 36
sarcoma and, relative frequency at different decades, 241–244
differentiation, 36
of upper jaw and, 71
sex frequency, 18
silver nitrate in, 37
site of, 19, 28, 30
stages of, 24
summary, 39
symptoms, 24
treatment, 37
safest, 38
ulceration period, 24, 33
varieties of, 20
well-defined period, 24, 27
Etherization, nasopharyngeal, 290, 295
Excision for leontiasis ossea, 342
of lower jaw, incision for, 300
prosthesis for, 360
of one-half lower jaw, 305
dividing jaw bone, 311
incision for, 308
inspection, 312
position of patient, 306
prosthesis for, 356, 358
case, 374

Excision of upper jaw, 295
after-treatment, 301
appearances after, 299
cleaning sinuses after, 298, 299
dissection of neck, 301
division of bony attachments, 297
Ferguson-Webber incision, 296
incision for, 296, 297, 300
inspection after, 298
position for, 295
prosthesis for, 360, 368
removal of orbital plate, 301
technic, 295
two stages, 302
Exhaustion after sarcoma operation, 91
Exostosis, hard odontoma and, differentiation, 237
osteoma, 156
External carotid, ligation of, cerebral embolism after, 130
Eye in sarcoma of upper jaw, 71, 72
removal of, in sarcoma, 114
Eyelid, edema of, in carcinoma, 256

Fibroma, 140
age and, 141
central, 141, 142
diagnosis, 145, 284
etiology, 143
histology, 140
of lower jaw, 142
case, 141
diagnosis, 284
of upper jaw, case, 140, 142
diagnosis, 284
origin, 140
periosteal, 141
symptoms, 144
treatment, 145
varieties, 141
Fibrosarcoma, 51
of upper jaw, prosthesis after resection, case, 134
Fibrous epulis, 20. See also *Epulis, fibrous*
Follicle, tooth, development, 168
sections, 171, 173
Follicular cysts, 197. See also *Cysts, dentigerous*
Fritzsche's tin splint, 360, 365
Fungosity of gums, epulis and, 35

Giant-cell sarcoma. See *Sarcoma, giant-cell*
sarcomatous epulis, 21. See also *Epulis, giant-cell sarcomatous*
Granulomata, epulis and, differentiation, 35
root, 35
Gum-boil, epulis and, 30
differentiation, 35
Gummata, sarcoma and, differentiation, 81
trauma and, 64
Gums, fungosity of, epulis and, 35
ulcers of, carcinoma and, 257

Hahl's apparatus for excision of upper jaw, 368, 369, 370
Hair, bulbous ends of, 163, 164
development of, similarity of tooth development, 163, 165
Hard odontomata, 234. See also *Odontoma, hard*
palate, leontiasis ossea of, 339
sarcoma of, 320
rubber prosthesis, 357
Hematoma from trauma, 64
Hemorrhage after sarcoma operation, 88
in operation, 291
Hildebrand's case of adamantine epithelioma, 195
Hoffmann's wire prosthesis, 365
Hood of enamel organ, 169
Hyperplasia of upper jaw, localized, 158

Incision for excision of lower jaw, 300
of one half lower jaw, 308
of upper jaw, 296, 297, 300
Ivory splint prosthesis, 369

Jaw and tooth, 170

Kocher's total resection of upper jaw, 303
Krause's description of adamantine epithelioma, 193
Kuhn's oral intubation in Kocher's operation, 305

Labor, tumor of rectus abdominis after, 64
Leontiasis ossea, 333
anosmia in, 347
bone thickening in, 336
case, 334, 335, 348
cerebral compression in, 339
relief from, 342
course, 341
ear symptoms, 340
etiology, 333
eye symptoms, 339, 340, 343, 344, 345, 351
relief from, 345
nasal fossæ in, 339, 347
neuralgia in, 339, 348
of palate, 339
of upper jaw, 336, 338
orbit in, 339, 340, 343, 344, 345, 351
pathology, 334
prognosis, 341
symptoms, 339
tear-duct in, 347
treatment, 342
Ligation of carotid in operation, 291
of external carotid, cerebral embolism after, 130
Lipoma, 152
Lower jaw of embryo, 164
Lymphangiosarcoma, case, 69
of lower jaw, cystic, case, 126
Lymphatics, carcinomatous involvement in sarcoma, case, 119
in adamantine epithelioma, 181
in carcinoma, 256
in mixed palatal tumors, 329
involvement of, in epulis, 35
removal of, in sarcoma, 138

Martin's permanent prosthesis, 366
Melanosarcoma, 65
of upper jaw starting in palate, 322
Meningitis, purulent, after sarcoma operation, 87
Metal splint, Boennecken's, 360, 362
Mixed sarcoma, 48. See also *Sarcoma, mixed*
Morphin before anesthetic, 289
Mosetig-Moorhof's plumbum of wax for root-cysts, 234
Mouth cleansing before operation, 288
Myositis from trauma, 64
Myxoma, 151
Myxosarcoma, 51, 151

Nasal cavities, cleansing before operation, 288
fossæ, carcinoma of, 250
in leontiasis ossea, 339, 347
polyp, sarcoma and, 70, 78
carcinoma and, 249
sinuses, anatomy, 313
relation to upper jaw, 313
Nasopharyngeal tubage, anesthesia by, 290, 295
Neck, dissection of, 301
glands, enlarged, case, 80, 81
Neuralgia, epulis and, differentiation, 35
in leontiasis ossea, 339, 348
infra-orbital, sarcoma and, 71

Neuralgia, sarcoma of upper jaw and, 68
Nitrate of silver in epulis, 37
Nose, plugging of, in carcinoma of jaw, 254

Odontoma, 162
bibliography, 196
classifications, 162
composite, 223
compound, 223
definition, 162
diagnosis, 284
epithelial, 175. See also *Epithelioma, adamantine*
epulis and, differentiation, 35, 36
follicular, 197. See also *Cysts, dentigerous*
hard, 234
case, 236, 237
diagnosis, 234
exostosis and, differentiation, 237
of lower jaw, pathology, 235
osteomyelitis and, differentiation, 237
of lower jaw, diagnosis, 284
of upper jaw, diagnosis, 284
sarcoma and, differentiation, 80
varieties, 163
Operation, 288
anesthesia, 290
assistants for, 291
Bellocq's balloon in, 295
carotid ligation in, 291. See also *Carotid*
cleansing mouth, 288
nasal cavities, 288
compression of carotid in, 293, 294
dissection of neck, 301
excision, 295. See also *Excision*
hemorrhage in, 291
Kocher's, 303
morphin before, 289
on upper jaw, 288
pharyngeal tamponade in, 295
Operation, pneumonia after, 292
position of patient, 290
preliminary steps, 288
principles of, 302
Rose position in, 292, 295
stomach-tube in, 289
tracheotomy in, 291
Trendelenburg's tampon cannula in, 295
Oral intubation in Kocher's operation, 305
Orbit, carcinoma of, 250
in leontiasis ossea, 339, 340, 343, 344, 345, 351
osteoma of, 153, 154, 160
Orbital plate, removal of, 301
in sarcoma, 114
Osteochondroma of upper jaw, case, 151
Osteochondromyxosarcoma, case, 92
removal of jaw and formation of new hard palate, 92
Osteofibrochondroma, case, 146
Osteofibroma of lower jaw, case, 155
Osteoma, 152
exostosis, 156
of alveolar process, 158
of antrum of Highmore, 156
of lower jaw, 160
case, 155, 157
of orbit, 160
case, 154
inner side, case, 153
of sinuses, 160
of upper jaw, 156
case, 153
origin, 152
sarcoma and, differentiation, 81
structure, 156
Osteomyelitis after trauma, 64
hard odontoma and, differentiation, 237
Osteoplastic flap, 367
total resection of upper jaw, 303
Osteosarcoma, 49, 51
case, 74

Osteosarcoma of lower jaw, 118
case, 127
periosteal, case, 65, 123, 124

Palate, adenoma of, 325
carcinoma of, 323
removal, 324
cylindroma of, 325
dermoids of, 319
removal, 324
enchondroma of, glandular, 325
endothelioma of, 325
epithelioma of, 323, 325
removal, 324
leontiasis ossea of, 339
papilloma of, 319
removal, 324
perithelioma of, 325
sarcoma of, 320
case, 321
melanotic, 322
plexiform, 325
removal, 324
tumors, 319
mixed, 325
at Massachusetts General Hospital, 330
case, 327
characteristics, 328
clinical pictures, 328
lymphatics in, 329
malignancy, 329
origin, 326–328
pathology, 325
recurrences, 329
situation, 328
synonyms, 325
removal, 324
Papilla, development, 167
epulis and, differentiation, 35
of palate, 319
removal, 324
Paradental epithelial débris, 172
Paraffin filling for root-cysts, 233
Parotid, sarcoma of, 79, 82
Partsch operation for root-cyst, 232
prosthesis apparatus, 362, 364
Periosteal cysts, 197, 226. See also *Root-cysts*
sarcoma, 44, 45. See also *Sarcoma, periosteal*
Periosteum, alveolo-dental, 171
Periostitis, alveolar, sarcoma and, differentiation, 79
epulis and, differentiation, 35
ossifying, after trauma, 64
Perithelioma of palate, 325
Permanent teeth, derivation, 165
Pharyngeal tamponade in operation, 295
Plastic repair, 363
Plexiform sarcoma of palate, 325
Plumbum of wax for root-cysts, 234
Pneumonia after operation, 292
after sarcoma operation, 90
Polyp, nasal, carcinoma and, 249
sarcoma and, 70, 78
Position of patient for operation, 290
Pregnancy, epulis in, 24
Prosthesis, 354
after total operation for fibrosarcoma of upper jaw, case, 134
aims of, 355
aluminum bronze plate, 362
wire, 359
Bardenheuer's autoplastic, 363
Boennecken's metal splint, 360, 362
bone, 367
cases, 371, 372, 373, 374
celluloid for, 366
conclusions, 373
for excision, 360
of one-half lower jaw, case, 356, 358, 374
of upper jaw, 368
for replacing symphysis, 356, 358, 359
for symphysis resection, 373, 374
Fritzsche's tin splint, 360, 365
general considerations, 354
Hahl's apparatus, 368, 369, 370

Prosthesis, hard-rubber, 357
immediate, 354
for exarticulation of one-half lower jaw, 356, 358, 374
ivory splint, 369
Martin-Ollier, 357
methods, 359
Partsch's apparatus, 362, 364
permanent, Martin's, 366
Sauer slanting splint, 360
Sauer-von Tropmann, 357
secondary, 354
wire, 365
Pulp of teeth, 169

Rectus abdominis, tumor of, after labor, 64
Resection of jaw, transplantation of rib after, 368
of one-half lower jaw, prosthesis for, 360
of upper jaw, Kocher's, 303
Rib, transplantation of, after jaw resection, 368
Rodent ulcer, case, 255
Root granulomata, 35
of teeth, 171
longitudinal section, 175
Root-cysts, 197, 226
contents, 227
development, 229
diagnosis, 232
Mosetig-Moorhof's plumbum of wax for, 234
of lower jaw, case, 227
of upper jaw, case, 226
origin, 227
paraffin filling for, 233
Partsch operation for, 232
pathology, 228
plumbum of wax for, 234
situation, 226
symptoms, 230
treatment, 232
Witzel's paraffin filling for, 233
Rose position in operation, 292, 295
Round-cell sarcoma, 52. See also *Sarcoma, round-cell*

Sac of tooth, development, 168
Sarcoma, 40
adamantine epithelioma and, differentiation, 187
age and, 41, 242, 243
carcinoma and, relative frequency, 43
at different decades, 241–244
central, 44
and periosteal, differentiation, 46
diagnosis, 284
epulis and, differentiation, 36
relative frequency at different decades, 241–244
etiologic importance of trauma, 58
etiology, 58
facts regarding, 40
frequency of jaw affected, 43
giant-cell, 44
of lower jaw, to left of symphysis, case, 55
of symphysis of lower jaw after trauma, case, 60
histologic groups, 41
Massachusetts General Hospital cases, 58
material studied, 43
melanotic, of palate, 322
mixed, 48
recurrence after operation, 51
of lower jaw, 55, 77, 115
case, 66, 76, 116, 125, 127, 247
diagnosis, 284
duration before operation, 124
facts regarding, 40
followed by carcinoma and invasion of lymphatics, case, 119
giant-cell, case, 128
treatment, 136

Sarcoma of lower jaw, inoperable, 139
cases, 129
lymphatic removal, 138
malignancy, 116
Massachusetts General Hospital cases, results, 122
melanotic, case, 128
near angle, case, 67
operation for, 136
duration before, 124
mortality, 117
partial, results, 115
partial vs. total, 136
recurrences, 139
results, 115, 118
total, results, 115
total vs. partial, 136
periosteal, treatment, 137
prosthesis, case, 371
rate of growth, 116
round-cell, inoperable case, 129, 130
treatment, 137
site, 53
spindle-cell, 120
case, 125, 127
treatment, 137
statistics of Massachusetts General Hospital, 109
treatment, 136, 138
varieties, 115
of palate, 320
case, 321
melanotic, 322
plexiform, 325
removal, 324
of parotid, 79, 82
of upper jaw, 67
beginning period, symptoms, 67
carcinoma and, differentiation, 81
cheek symptoms, 68, 72
clinical pictures, 67
cures, 98
cysts and, differentiation, 80
Sarcoma of upper jaw, diagnosis, 78, 284
dissection of neck in, 111
edema of eye in, 106
empyema of antrum and, 74, 78
epulis and, 71
extension to nose, orbit, cheek, and temporal region, 107
eye in, 71, 72
facts regarding, 40
general health, 72
giant-cell, case, 84
treatment, 137
glandular enlargement in, 72
gummata and, differentiation, 81
in antrum, treatment, 138
infra-orbital neuralgia and, 71
inoperable, 99, 100, 139
case, 112
ligation of external carotid in, cerebral embolism from, 130–134
lymphatic removal, 138
Massachusetts General Hospital cases, 103
mixed, 92
nasal polyp and, 70, 78
neuralgia and, 68, 71
odontomata and, differentiation, 80
operation for, 136, 288
causes of death after, 87
cures, 98
dissection of neck in, 111
early vs. late, 98
exhaustion after, 91
hemorrhage after, 88
in every case, 107
late vs. early, 98
mortality, 83
abroad, 86
partial, cases, 95
recurrences, 100, 102
results, 105, 106, 115

Sarcoma of upper jaw, operation for, partial vs. total, 94, 136
pneumonia after, 90
prolongation of life by, 106
purulent meningitis after, 87
recurrences, 113, 139
removal of eye, 114
of orbital plate, 114
repeated, case, 88
results, 104, 115
selection of cases, 108
sepsis after, 87
shock after, 91
total, recurrences, 102, 108
results, 104, 115
total vs. partial, 94, 136
osteomata and, differentiation, 81
periosteal, case, 74
treatment, 137
periostitis and, differentiation, 79
prognosis, 82
recurrence, 98, 113
recurrent, case, 117
removal of eye, 114
of orbital plate, 114
round-cell, case, 96, 97, 112
ligation of external carotid in, 130–134
partial operation for, futility, 95, 96
treatment, 137
jaw, site, 53
spindle-cell, case, 88, 89, 90
treatment, 137
statistics of Massachusetts General Hospital, 109
summary of clinical pictures, 73
symptoms, 67
established period, 71
late period, 72
syphilis and, 82
teeth in, 68
Sarcoma of jaw, total resection for, 99
treatment, 136
tumor of, 72
tumors of soft parts and, differentiation, 80
operation for, 288. See also *Operation*
origin, 40
part of jaw first attacked, 53
periosteal, 44, 45
and central, differentiation, 46
case, 74
rate of growth, 41
round-cell, 52
sex and, 43, 54
starting from antrum, gaining access to, 97
trauma and, 58
treatment, 136
Sauer slanting splint, 360
Sepsis after sarcoma operation, 87
Shock after sarcoma operation, 91
Silver nitrate in epulis, 37
Sinuses, nasal, anatomy, 313
relation to upper jaw, 313
osteoma of, 160
Skin-muscle-periosteum-bone flaps, 369
Slanting splint of Sauer, 360
Spindle-cell sarcoma. See *Sarcoma of upper jaw, spindle-cell*
Splint, ivory, for prosthesis, 369
metal, of Boennecken, 360, 362
slanting, of Sauer, 360
tin, of Fritzsche, 360, 365
Stellate reticulum of teeth, 169
Stomach-tube before operation, 289
Stratum intermedium of teeth, 170
Suture material for plastic repair, 363
Symphysis, removal of, prosthesis after, 356, 358, 359
resection of, in sarcoma, 61, 63
prosthesis, 373, 374
Syphilis, sarcoma and, 82

Tear-duct in leontiasis ossea, 347
obstruction of, in carcinoma, 256
Teeth, ameloblastic layer of, 169
development, 162, 163
similarity to hair development, 163, 165
enamel, development, 166, 167
hood of, 169
epithelial rests of, 172
expulsion of, by epulis, 19, 25
follicles, development, 168
sections, 171, 173
in dentigerous cysts, 211, 212
in sarcoma of upper jaw, 68
jaw and, 170
papilla of, development, 167
permanent, derivation, 165
pulp of, 169
roots of, 171
longitudinal section, 175
sac of, development, 168
section, 166
sockets of, 170
stellate reticulum of, 169
stratum intermedium of, 170
wisdom, retained, epulis and, differentiation, 36
Tin splint, Fritzsche's, 360, 365
Tooth-socket, 170
Total resection of upper jaw, osteoplastic, 303
Tracheotomy in operation on jaws, 291
Trauma, benign lesions following, 64
gumma and, 64
hematoma from, 64
in diagnosis, 287
myositis from, 64
ossifying peritonitis after, 64
osteomyelitis after, 64
sarcoma and, 58
Treatment, operative, 288. See also *Operation*
Trendelenburg's tampon cannula in operation, 295
Tumor of rectus abdominis after labor, 64

Ulcer, rodent, case, 255
Ulceration of epulis, 24, 33
Ulcers of face, carcinoma and, 258
of gums, carcinoma and, 257
Uvula, carcinoma of, 323

Vision, carcinoma and, 254

Wire as suture material for plastic repair, 363
Wisdom teeth, retained, epulis and, differentiation, 36
Witzel's paraffin filling for root-cysts, 233

## SAUNDERS' BOOKS

on

# Practice, Pharmacy, Materia Medica, Therapeutics, Pharmacology, and the Allied Sciences

## W. B. SAUNDERS COMPANY

925 WALNUT STREET PHILADELPHIA

9, HENRIETTA STREET, COVENT GARDEN, LONDON

### SAUNDERS' SUCCESSFUL PUBLISHING

AS is well-known, the lists of most publishers contain a number of books that have never paid, and for which the publisher will never get back the money invested. Messrs. W. B. Saunders Company would call attention to the fact that they have no such works on their list. In all the years of their business experience they have never published a book at a loss. This they confidently consider a most remarkable record, and submit the fact to the attention of the profession as an example of what might justly be called "Successful Publishing."

**A Complete Catalogue of our Publications will be Sent upon Request**

# Musser and Kelly on Treatment

**A Handbook of Practical Treatment.** By 78 eminent specialists. Edited by JOHN H. MUSSER, M. D., Professor of Clinical Medicine; and A. O. J. KELLY, M. D., Assistant Professor of Medicine, University of Pennsylvania. Three octavos of 900 pages each, illustrated. Per volume: Cloth, $6.00 net; Half Morocco, $7.50 net. *Subscription.*

**JUST READY—IN THREE VOLUMES**

**A PRACTICE FOR QUICK REFERENCE AND DAILY USE**

Every chapter in this work was written by a specialist of unquestioned authority. Not only is drug therapy given but also dietotherapy, serumtherapy, organotherapy, rest-cure, exercise and massage, hydrotherapy, climatology, electrotherapy, *x*-ray, and radial activity are fully, clearly, and definitely discussed. Those measures partaking of a *surgical nature* have been presented by *surgeons*.

**THE EMINENT CONTRIBUTORS**

Isaac A. Abt, M.D.
Sir Clifford Allbutt, M.D.
James M. Anders, M.D.
John F. Anderson, M.D.
Lewellys F. Barker, M.D.
Joseph C. Bloodgood, M.D.
George Blumer, M.D.
Sir Lauder Brunton, M.D.
Charles W. Burr, M.D.
Richard C. Cabot, M.D.
James F. Carroll, M.D.
John G. Clark, M.D.
Rufus I. Cole, M.D.
Warren Coleman, M.D.
Matthew H. Cryer, M.D.
Clinton T. Dent, M.C.
Francis X. Dercum, M.D.
George E. deSchweinitz, M.D
George Dock, M.D.
Isadore Dyer, M.D.
David L. Edsall, M.D.
William A. Edwards, M.D.
Arthur W. Elting, M.D.
John M. T. Finney, M.D.
Charles H. Frazier, M.D.
M. Howard Fussell, M.D.
Thomas B. Futcher, M.D.
John H. Gibbon, M.D.
Joel E. Goldthwait, M.D.
Samuel McC. Hamill, M.D.
Hobart A. Hare, M.D.
Charles Harrington, M.D.
Ludvig Hektoen, M.D.
Albion Walter Hewlett, M.D.
Guy Hinsdale, M.D.
Guy L. Hunner, M.D.
Chevalier Jackson, M.D.
Henry Jackson, M.D.
Theodore C. Janeway, M.D.
J. H. Jobson, M.D.
A. O. J. Kelly, M.D.
Maynard Ladd, M.D.
Egbert Lefevre, M.D.
James Hendrie Lloyd, M.D.
G. Hudson-Makuen, M.D.
Charles F. Martin, M.C.
Edward Martin, M.D.
Charles W. Mayo, M.D.
William J. Mayo, M.D.
R. Tait McKenzie, M.D.
Herbert C. Moffitt, M.D.
Jesse M. Mosher, M.D.
B. G. A. Moynihan, Esq.
George P. Müller, M.D.
John H. Musser, M.D.
Edward O. Otis, M.D.
Henry K. Pancoast, M.D.
Roswell Park, M.D.
Richard M. Pearce, M.D.
Charles W. Richardson, M.D.
David Riesman, M.D.
Milton J. Rosenau, M.D.
Joseph Sailer, M.D.
J. F. Schamberg, M.D.
Henry Sewall, M.D.
Bertram W. Sippy, M.D.
William G. Spiller, M.D.
J. Dutton Steele, M.D.
Alfred Stengel, M.D.
Charles G. Stockton, M.D.
James E. Talley, M.D.
E. W. Taylor, M.D.
James Tyson, M.D.
George H. Weaver, M.D.
J. William White, M.D.
Alfred C. Wood, M.D.
Horatio C. Wood, Jr., M.D.

# Cabot's Differential Diagnosis

**Differential Diagnosis.** Presented through an Analysis of 383 Cases. By RICHARD C. CABOT, M. D., Assistant Professor of Clinical Medicine, Harvard Medical School, Boston. Octavo of 750 pages, illustrated.

**JUST READY**

Dr. Cabot's work takes up diagnosis from the point of view of the *presenting symptom*—the symptom in any disease which holds the foreground in the clinical picture: the principal complaint. It groups diseases under these symptoms, and points the way to proper reasoning in coming to a correct diagnosis. It works backward from each leading symptom to the actual organic cause of the symptom. This the author does by means of *case-teaching*, a method used by him for the past eight years at the Harvard Medical School. No more practical book on this subject ever came from the press.

---

# Morrow's Diagnostic and Therapeutic Technic

**Diagnostic and Therapeutic Technic.** By ALBERT S. MORROW, M. D., Adjunct Professor of Surgery, New York Polyclinic. Octavo of 775 pages, with 815 original line drawings.

**JUST THE WORK FOR PRACTITIONERS—JUST ISSUED**

Dr. Morrow's book is decidedly a work for the physician in general practice. It tells just how to perform those procedures required of every physician daily; and it does so in a way never before approached for clearness, directness, and simplicity. It is not a book on drug therapy. It deals alone with physical or mechanical diagnostic and therapeutic measures. Each procedure, too, is plainly illustrated by original line drawings. There are 815 of these pictures, in themselves a course in practical technic.

# Bonney on Tuberculosis

**Tuberculosis.** By SHERMAN G. BONNEY, M. D., Professor of Medicine, Denver and Gross College of Medicine, Denver. Octavo of 955 pages, with 243 original illustrations. Cloth, $7.00 net.

**THE NEW (2d) EDITION**

Dr. Bonney's work embodies the results of wide personal experience in observing and treating tuberculous patients, especially those suffering from the pulmonary form. His book is a thorough and complete treatise of the entire subject of tuberculosis, taking up every region of the body and every secondary involvement that can occur. The section on Physical Signs of Pulmonary Tuberculosis is really a complete monograph on the physical diagnosis of diseases of the chest. As is to be expected, treatment is particularly full and practical. There are chapters on prophylaxis; open-air treatment, fully illustrated; diet; sanitarium and climatic treatments; therapeutic measures to alleviate distressing symptoms; and drug and vaccine therapeutics. There are nearly two hundred original pictures, including twenty in colors and sixty *x*-ray photographs.

**Maryland Medical Journal**

"Dr. Bonney's book is one of the best and most exact works on tuberculosis, in all its aspects, that has yet been published."

# Anders and Boston's Diagnosis

**A Text-Book of Diagnosis.** By JAMES M. ANDERS, M. D., PH.D., LL. D., Professor of the Theory and Practice of Medicine and of Clinical Medicine, Medico-Chirurgical College, Philadelphia; and L. NAPOLEON BOSTON, M. D., Adjunct Professor of Medicine, Medico-Chirurgical College, Philadelphia. Octavo of 1200 pages, with 300 original illustrations.

**READY IN FEBRUARY FOR THE PRACTITIONER**

This new work is designed expressly for the general practitioner. The methods given are practical and especially adapted for quick reference. The diagnostic methods are presented in a forceful, definite way by men who have had wide experience at the bedside and in the clinical laboratory. The text is profusely illustrated with original pictures, each one representing some point in technic or some diagnostic sign. It is a work for every practitioner.

# Kemp on Stomach and Intestines

**Diseases of the Stomach and Intestines.** By ROBERT COLEMAN KEMP, M. D., Professor of Gastro-intestinal Diseases at the New York School of Clinical Medicine. Octavo of 766 pages, with 279 illustrations. Cloth, $6.00 net; Half Morocco, $7.50 net.

**THIRD PRINTING IN EIGHT MONTHS**

Of the many works on gastro-intestinal diseases, this is perhaps the only one in which the needs of the general practitioner are given pre-eminent emphasis. It is the practitioner who first meets with these cases, and it is he upon whom the burden of diagnosis rests. After the diagnosis is established, the practitioner, if properly equipped, could frequently treat the case himself instead of transferring it to a specialist. This work is intended to equip the practitioner with this end in view. *Auto-intoxication* has been given unusual attention.

**The Therapeutic Gazette**

"The therapeutic advice which is given is excellent. Methods of physical and clinical examination are adequately and correctly described."

# Deaderick on Malaria

**Practical Study of Malaria.** By WILLIAM H. DEADERICK, M. D., Member American Society of Tropical Medicine; Fellow London Society of Tropical Medicine and Hygiene. Octavo of 402 pages, illustrated. Cloth, $4.50 net; Half Morocco, $6.00 net.

**A WORK LONG NEEDED**

This is a practical work, one laying special stress on diagnosis and treatment, and one, therefore, that will prove of the greatest service. It is the only book in any language describing the third cycle of the malarial parasite—the parthenogenetic cycle—and the account given of hemoglobinuric fever is full and clear. The chapters on diagnosis and treatment are conspicuous for the clearness of expression, the exactness of statement, and the intuitive way in which the author has grasped the needs of the physician and supplied them. It is a *necessary* book—one that you will want.

**Frank A. Jones, M. D.**

*Professor of Clinical Medicine and Physical Diagnosis, Memphis Hospital Medical College.*

"Dr. Deaderick's book is up to date and the subject matter is well arranged. We have been waiting for many years for such a work written by a man who sees malaria in all its forms in a highly malarious climate."

# Tousey's
# Medical Electricity and X-Rays

**Medical Electricity and the X-Rays.** By SINCLAIR TOUSEY, M. D., Consulting Surgeon to St. Bartholomew's Hospital, New York. Octavo of 1116 pages, with 750 practical illustrations, 16 in colors.

Cloth, $7.00 net; Half Morocco, $8.50 net.

**FOR THE PRACTITIONER**

This new work by such an eminent authority is destined to take a leading place among books on this subject. Written primarily for the general practitioner, it gives him just the information he wishes to have regarding the use of medical electricity, the therapeutic results obtained, etc. At the same time it tells the specialist how the most eminent electrotherapeutists are securing results, the latest authorities in every country having been consulted for details of practical value. The work gives explicit directions for the care and regulation of static machines, *x*-ray tubes, and all apparatus. The author *tells how to make x-ray pictures* by a practical technic easily followed. *Dental radiography* the author has made his own.

**The Military Surgeon**

"The whole subject of medical and surgical electricity is covered in these pages. Not only is it covered, but in great detail."

# McKenzie on Exercise in Education and Medicine

**Exercise in Education and Medicine.** By R. TAIT MCKENZIE, B. A., M. D., Professor of Physical Education and Director of the Department, University of Pennsylvania. Octavo of 393 pages, with 346 original illustrations.

Cloth, $3.50 net.

**ILLUSTRATED**

This work is a full and detailed treatise on the application of systematized exercise in the development of the normal body and in the correction of certain diseased conditions in which gymnastics have proved of value.

**D. A. Sargeant, M. D.,** *Director of Hemenway Gymnasium, Harvard University.*

"It cannot fail to be helpful to practitioners in medicine. The classification of athletic games and exercises in tabular form for different ages, sexes, and occupations is the work of an expert. It should be in the hands of every physical educator and medical practitioner."

# Anders' Practice of Medicine

**A Text-Book of the Practice of Medicine.** By JAMES M. ANDERS, M. D., PH. D., LL. D., Professor of the Practice of Medicine and of Clinical Medicine, Medico-Chirurgical College, Philadelphia. Handsome octavo, 1326 pages, fully illustrated. Cloth, $5.50 net; Half Morocco, $7.00 net.

**THE NEW (9th) EDITION**

The success of this work is no doubt due to the extensive consideration given to Diagnosis and Treatment, under Differential Diagnosis the points of distinction of simulating diseases being presented in tabular form. In this new edition Dr. Anders has included all the most important advances in medicine, keeping the book within bounds by a judicious elimination of obsolete matter. A great many articles have also been rewritten.

**Wm. E. Quine, M. D.,**
*Professor of Medicine and Clinical Medicine, College of Physicians and Surgeons, Chicago.*

"I consider Anders' Practice one of the best single-volume works before the profession at this time, and one of the best text-books for medical students."

# DaCosta's Physical Diagnosis

**Physical Diagnosis.** By JOHN C. DACOSTA, JR., M. D., Associate in Clinical Medicine, Jefferson Medical College, Philadelphia. Octavo of 557 pages, with 212 original illustrations. Cloth, $3.50 net.

**ORIGINAL ILLUSTRATIONS**

Dr. DaCosta's work is a thoroughly new and original one. Every method given has been carefully tested and proved of value by the author himself. Normal physical signs are explained in detail in order to aid the diagnostician in determining the abnormal. Both direct and differential diagnosis are emphasized. The cardinal methods of examination are supplemented by full descriptions of technic and the clinical utility of certain instrumental means of research.

**Dr. Henry L. Elsner,** *Professor of Medicine at Syracuse University.*

"I have reviewed this book, and am thoroughly convinced that it is one of the best ever written on this subject. In every way I find it a superior production."

# Sahli's Diagnostic Methods

**A Treatise on Diagnostic Methods of Examination.** By PROF. DR. H. SAHLI, of Bern. Edited, with additions, by NATH'L BOWDITCH POTTER, M. D., Assistant Professor of Clinical Medicine, Columbia University (College of Physicians and Surgeons), New York. Octavo of 1229 pages, illustrated. Cloth, $6.50 net; Half Morocco, $8.00 net.

**JUST READY—THE NEW (2d) EDITION, ENLARGED AND RESET**

**Containing all the Matter of the New Fifth German Edition—And More**

The American edition of Dr. Sahli's great work met with the immediate success accorded the original German. The reason for this success is obvious. It is a practical diagnosis, written and edited by practical clinicians. So thorough has been the revision for this edition that it was found necessary practically to reset the entire work. Every line has received careful scrutiny, adding new matter, eliminating the old.

**Lewellys F. Barker, M. D.**

*Professor of the Principles and Practice of Medicine, Johns Hopkins University*

"I am delighted with it, and it will be a pleasure to recommend it to our students in the Johns Hopkins Medical School."

# Friedenwald *and* Ruhräh on Diet

**Diet in Health and Disease.** By JULIUS FRIEDENWALD, M. D., Professor of Diseases of the Stomach, and JOHN RUHRÄH, M. D., Professor of Diseases of Children, College of Physicians and Surgeons, Baltimore. Octavo of 764 pages. Cloth, $4.00 net.

**THE NEW (3d) EDITION**

This new edition has been carefully revised, making it still more useful than the two editions previously exhausted. The articles on milk and alcohol have been rewritten, additions made to those on tuberculosis, the salt-free diet, and rectal feeding, and several tables added, including Winton's, showing the composition of diabetic foods.

**George Dock, M. D.**

*Professor of Theory and Practice and of Clinical Medicine, Tulane University.*

"It seems to me that you have prepared the most valuable work of the kind now available. I am especially glad to see the long list of analyses of different kinds of foods."

# Oertel on Bright's Disease

**The Anatomic Histological Processes of Bright's Disease.**—By HORST OERTEL, M. D., Director of the Russell Sage Institute of Pathology, New York. Octavo of 227 pages, with 44 illustrations and 6 colored plates. Cloth, $5.00 net; Half Morocco, $6.50 net.

**JUST READY**

These lectures deal with the anatomic histological processes of Bright's disease, and in a somewhat different way from the usual manner. Everywhere relations are emphasized and an endeavor made to reconstruct the whole as a unit of interwoven processes. In the preparation of his lectures the author had in mind a twofold aim: To present the visual picture of nephritis and to prepare the proper way for the understanding of the genesis of the disease.

# Fenwick on Dyspepsia

**Dyspepsia.**—By WILLIAM SOLTAU FENWICK, M. D., of London, England. Octavo volume of 485 pages, illustrated. Cloth, $3.00 net.

**RECENTLY ISSUED**

Dr. Fenwick takes up this important disease in a thoroughly systematic way. He discusses the causes, pathology, symptoms, diagnosis, prognosis, and treatment with a clearness, a definiteness, and, withal, a conciseness that makes his work the most practical and useful on this subject. Dyspepsia is a condition so frequently met with by every practitioner that this work will undoubtedly appeal most strongly as supplying a need long felt. The text is illustrated.

# Slade's Physical Examination and Diagnostic Anatomy

**RECENTLY ISSUED**

**Physical Examination and Diagnostic Anatomy.**—By CHARLES B. SLADE, M. D., Chief of Clinic in General Medicine, University and Bellevue Hospital Medical College. 12mo of 146 pages, illustrated. Cloth, $1.25 net.

This work is intended to serve as a text-book on the technic and fundamental methods and principles of Physical Examination. The subject matter is arranged to accord with the natural course the average student pursues in acquiring knowledge of this subject. The first thought in the preparation of the book was to make it practical. Exhaustive discussion and problems of diagnosis have been avoided, rather holding the attention of the student to the essential principles of the subject. The illustrations, too, have been drawn with the practical in mind.

## AMERICAN EDITION

# NOTHNAGEL'S PRACTICE

UNDER THE EDITORIAL SUPERVISION OF

## ALFRED STENGEL, M.D.

Professor of Clinical Medicine in the University of Pennsylvania

---

### Typhoid and Typhus Fevers

By DR. H. CURSCHMANN, of Leipsic. Edited, with additions, by WILLIAM OSLER, M. D., F. R. C. P., Regius Professor of Medicine, Oxford University, Oxford, England. Octavo of 646 pages, illustrated.

### Smallpox (including Vaccination), Varicella, Cholera Asiatica, Cholera Nostras, Erysipelas, Erysipeloid, Pertussis, and Hay Fever

By DR. H. IMMERMANN, of Basle; DR. TH. VON JÜRGENSEN, of Tübingen; DR. C. LIEBERMEISTER, of Tübingen; DR. H. LENHARTZ, of Hamburg; and DR. G. STICKER, of Giessen. The entire volume edited, with additions, by SIR J. W. MOORE, M. D., F. R. C. P. I., Professor of Practice, Royal College of Surgeons, Ireland. Octavo of 682 pages, illustrated.

### Diphtheria, Measles, Scarlet Fever, and Rötheln

By WILLIAM P. NORTHRUP, M. D., of New York, and DR. TH. VON JÜRGENSEN, of Tübingen. The entire volume edited, with additions, by WILLIAM P. NORTHRUP, M. D., Professor of Pediatrics, University and Bellevue Hospital Medical College, New York. Octavo of 672 pages, illustrated, including 24 full-page plates, 3 in colors.

### Diseases of the Bronchi, Diseases of the Pleura, and Inflammations of the Lungs

By DR. F. A. HOFFMANN, of Leipsic; DR. O. ROSENBACH, of Berlin; and DR. F. AUFRECHT, of Magdeburg. The entire volume edited, with additions, by JOHN H. MUSSER, M. D., Professor of Clinical Medicine, University of Pennsylvania. Octavo of 1029 pages, illustrated, including 7 full-page colored lithographic plates.

### Diseases of the Pancreas, Suprarenals, and Liver

By DR. L. OSER, of Vienna; DR. E. NEUSSER, of Vienna; and DRS. H. QUINCKE and G. HOPPE-SEYLER, of Kiel. The entire volume edited, with additions, by REGINALD H. FITZ, A. M., M. D., Hersey Professor of the Theory and Practice of Physic, Harvard University; and FREDERICK A. PACKARD, M. D., Late Physician to the Pennsylvania and Children's Hospitals, Philadelphia. Octavo of 918 pages, illustrated.

**SOLD SEPARATELY—PER VOLUME: CLOTH, $5.00 NET; HALF MOROCCO, $6.00 NET**

## AMERICAN EDITION

# NOTHNAGEL'S PRACTICE

### Diseases of the Stomach

By DR. F. RIEGEL, of Giessen. Edited, with additions, by CHARLES G. STOCKTON, M. D., Professor of Medicine, University of Buffalo. Octavo of 835 pages, with 29 text-cuts and 6 full-page plates.

### Diseases of the Intestines and Peritoneum

**Second Edition**

By DR. HERMANN NOTHNAGEL, of Vienna. Edited, with additions, by H. D. ROLLESTON, M. D., F. R. C. P., Physician to St. George's Hospital, London. Octavo of 1100 pages, illustrated.

### Tuberculosis and Acute General Miliary Tuberculosis

By DR. G. CORNET, of Berlin. Edited, with additions, by WALTER B. JAMES, M. D., Professor of the Practice of Medicine, Columbia University, New York. Octavo of 806 pages.

### Diseases of the Blood (*Anemia, Chlorosis, Leukemia, and Pseudoleukemia*)

By DR. P. EHRLICH, of Frankfort-on-the-Main; DR. A. LAZARUS, of Charlottenburg; DR. K. VON NOORDEN, of Frankfort-on-the-Main; and DR. FELIX PINKUS, of Berlin. The entire volume edited, with additions, by ALFRED STENGEL, M. D., Professor of Clinical Medicine, University of Pennsylvania. Octavo of 714 pages, with text-cuts and 13 full-page plates, 5 in colors.

### Malarial Diseases, Influenza, and Dengue

By DR. J. MANNABERG, of Vienna, and DR. O. LEICHTENSTERN, of Cologne. The entire volume edited, with additions, by RONALD ROSS, F. R. C. S. (ENG.), F. R. S., Professor of Tropical Medicine, University of Liverpool; J. W. W. STEPHENS, M. D., D. P. H., Walter Myers Lecturer on Tropical Medicine, University of Liverpool; and ALBERT S. GRÜNBAUM, F. R. C. P., Professor of Experimental Medicine, University of Liverpool. Octavo of 769 pages, illustrated.

### Diseases of Kidneys and Spleen, and Hemorrhagic Diatheses

By DR. H. SENATOR, of Berlin, and DR. M. LITTEN, of Berlin. The entire volume edited, with additions, by JAMES B. HERRICK, M. D., Professor of the Practice of Medicine, Rush Medical College. Octavo of 815 pages, illust.

### Diseases of the Heart

By PROF. DR. TH. VON JURGENSEN, of Tübingen; PROF. DR. L. KREHL, of Greifswald; and PROF. DR. L. VON SCHRÖTTER, of Vienna. The entire volume edited, with additions, by GEORGE DOCK, M. D., Professor of Theory and Practice of Medicine and Clinical Medicine, Tulane University of Louisiana. Octavo of 848 pages, fully illustrated.

**SOLD SEPARATELY—PER VOLUME: CLOTH, $5.00 NET; HALF MOROCCO, $6.00 NET**

# Goepp's State Board Questions

**State Board Questions and Answers.**—By R. MAX GOEPP, M. D., Professor of Clinical Medicine, Philadelphia Polyclinic. Octavo of 684 pages. Cloth, $4.00 net; Half Morocco, $5.50 net.

**Pennsylvania Medical Journal**

"Nothing has been printed which is so admirably adapted as a guide and self-quiz for those intending to take State Board Examinations."

## Stevens' Therapeutics

**New (5th) Edition**

A TEXT-BOOK OF MODERN MATERIA MEDICA AND THERAPEUTICS. By A. A. STEVENS, A. M., M. D., Lecturer on Physical Diagnosis in the University of Pennsylvania. Octavo of 675 pages. Cloth, $3.50 net.

Dr. Stevens' Therapeutics is one of the most successful works on the subject ever published. In this new edition the work has undergone a very thorough revision, and now represents the very latest advances.

**The Medical Record, New York**

"Among the numerous treatises on this most important branch of medical practice, this by Dr. Stevens has ranked with the best."

## Butler's Materia Medica

**New (6th) Edition**

A TEXT-BOOK OF MATERIA MEDICA, THERAPEUTICS, AND PHARMACOLOGY. By GEORGE F. BUTLER, PH. G., M. D., Professor and Head of the Department of Therapeutics and Professor of Preventive and Clinical Medicine, Chicago College of Medicine and Surgery, Medical Department Valpariso University. Octavo of 702 pages, illustrated. Cloth, $4.00 net; Half Morocco, $5.50 net.

For this sixth edition Dr. Butler has entirely remodeled his work, a great part having been rewritten. All obsolete matter has been eliminated, and special attention has been given to the toxicologic and therapeutic effects of the newer compounds.

**Medical Record, New York**

"Nothing has been omitted by the author which, in his judgment, would add to the completeness of the text."

## Sollmann's Pharmacology

**New (2d) Edition**

A TEXT-BOOK OF PHARMACOLOGY. By TORALD SOLLMANN, M. D., Professor of Pharmacology and Materia Medica, Western Reserve University. Octavo of 1070 pages, illustrated. Cloth, $4.00 net.

The author bases the study of therapeutics on systematic knowledge of the nature and properties of drugs, and thus brings out forcibly the intimate relation between pharmacology and practical medicine.

**J. F. Fotheringham, M. D.,** *Trinity Medical College, Toronto.*

"The work certainly occupies ground not covered in so concise, useful, and scientific a manner by any other text I have read on the subjects embraced."

## Arny's Pharmacy

PRINCIPLES OF PHARMACY. By HENRY V. ARNY, PH. G., PH. D., Professor of Pharmacy at the Cleveland School of Pharmacy. Octavo of 1175 pages, with 246 illustrations. Cloth, $5.00 net.

**George Reimann, Ph. G.,** *Secretary of the New York State Board of Pharmacy.*

"I would say that the book is certainly a great help to the student, and I think it ought to be in the hands of every person who is contemplating the study of pharmacy."

# Hinsdale's Hydrotherapy

**Hydrotherapy:** A Treatise on Hydrotherapy in General; Its Application to Special Affections; the Technic or Processes Employed, and a Brief Chapter on the Use of Waters Internally. By GUY HINSDALE, M. D., Fellow Royal Society of Medicine of Great Britain. Octavo of 466 pages, illustrated. Cloth, $3.50 net.

**RECENTLY ISSUED**

The treatment of disease by hydrotherapeutic measures has assumed such an important place in medical practice that a good, practical work on the subject is an essential in every practitioner's armamentarium. This new work supplies all needs. It describes fully the various kinds of baths, douches, sprays; the application of heat and cold; the internal use of mineral waters and all other procedures included under hydrotherapeutic measures. Then the use of hydrotherapy in the various diseases is detailed concisely, yet explicitly and adequately. Illustrations have been freely used throughout the text. As a practical work on this important subject, Dr. Hinsdale's book will be found to take first place.

# Swan's Prescription-writing and Formulary

**Prescription-writing and Formulary.** By JOHN M. SWAN, M. D., Associate Professor of Clinical Medicine in the Medico-Chirurgical College of Philadelphia. 12mo of 185 pages. Flexible leather, $1.25 net.

This work contains nearly 1050 prescriptions, selected because of their proved value. There is also other information often needed by the practitioner, such as prescription Latin, a chapter on the United States Pharmacopeia and its official preparations, tables of weights and measures, doses, incompatibility and number of ingredients, abbreviations, and miscellaneous considerations.

# Stewart's Pocket Therapeutics and Dose-book

**NEW (4th) EDITION**

**Pocket Therapeutics and Dose-book.** By MORSE STEWART, JR., M. D. 32mo of 263 pages. Cloth, $1.00 net.

This little book is a complete therapeutics as well as a dose-book, and it is so arranged that the information sought can be obtained at a glance. The work for this edition has been practically rewritten and entirely reset. It fits the pocket.

GET THE BEST

# American Illustrated Dictionary

THE NEW STANDARD

## The New (5th) Edition—Adopted by U. S. Army

**The American Illustrated Medical Dictionary.**—By W. A. NEWMAN DORLAND, M. D., Editor of "The American Pocket Medical Dictionary." Large octavo of 876 pages, bound in full flexible leather. Price, $4.50 net; with thumb index, $5.00 net.

**A KEY TO MEDICAL LITERATURE—WITH 2000 NEW TERMS**

**Howard A. Kelly, M.D.,** *Professor of Gynecologic Surgery, Johns Hopkins University.*
"Dr. Dorland's dictionary is admirable. It is so well gotten up and of such convenient size. No errors have been found in my use of it."

## Thornton's Dose-Book.

**New (4th) Edition**

DOSE-BOOK AND MANUAL OF PRESCRIPTION-WRITING. By E. Q. THORNTON, M.D., Assistant Professor of Materia Medica, Jefferson Medical College, Philadelphia. Post-octavo, 410 pages, illustrated. Flexible leather, $2.00 net.

"I will be able to make considerable use of that part of its contents relating to the correct terminology as used in prescription-writing, and it will afford me much pleasure to recommend the book to my classes, who often fail to find this information in their other text-books."—C. H. MILLER, M. D., *Professor of Pharmacology, Northwestern University Medical School.*

## Lusk on Nutrition

**New (2d) Edition**

ELEMENTS OF THE SCIENCE OF NUTRITION. By GRAHAM LUSK, PH. D., Professor of Physiology in Cornell University Medical School. Octavo of 402 pages. Cloth, $3.00 net.

"I shall recommend it highly. It is a comfort to have such a discussion of the subject."—LEWELLYS F. BARKER, M. D., *Johns Hopkins University.*

## Camac's "Epoch-making Contributions"

EPOCH-MAKING CONTRIBUTIONS IN MEDICINE AND SURGERY. Collected and arranged by C. N. B. CAMAC, M. D., of New York City. Octavo of 450 pages, illustrated. Artistically bound, $4.00 net.

"Dr. Camac has provided us with a most interesting aggregation of classical essays. We hope that members of the profession will show their appreciation of his endeavors."—THERAPEUTIC GAZETTE.

## The American Pocket Medical Dictionary — New (6th) Edition

THE AMERICAN POCKET MEDICAL DICTIONARY. Edited by W. A. NEWMAN DORLAND, M. D., Editor "American Illustrated Medical Dictionary." 598 pages. Flexible leather, with gold edges, $1.00 net; with thumb index, $1.25 net.

## Pusey and Caldwell on X-Rays — Second Edition

THE PRACTICAL APPLICATION OF THE RÖNTGEN RAYS IN THERAPEUTICS AND DIAGNOSIS. By WILLIAM ALLEN PUSEY, A. M., M. D., Professor of Dermatology in the University of Illinois; and EUGENE W. CALDWELL, B. S., Director of the Edward N. Gibbs X-Ray Memorial Laboratory of the University and Bellevue Hospital Medical College, New York. Octavo of 625 pages, with 200 illustrations. Cloth, $5.00 net; Half Morocco, $6.50 net.

## Cohen and Eshner's Diagnosis. — Second Revised Edition

ESSENTIALS OF DIAGNOSIS. By S. SOLIS-COHEN, M. D., Senior Assistant Professor in Clinical Medicine, Jefferson Medical College, Phila.; and A. A. ESHNER, M. D., Professor of Clinical Medicine, Philadelphia Polyclinic. Post-octavo, 382 pages; 55 illustrations. Cloth, $1.00 net. *In Saunders' Question-Compend Series.*

## Morris' Materia Medica and Therapeutics. — New (7th) Edition

ESSENTIALS OF MATERIA MEDICA, THERAPEUTICS, AND PRESCRIPTION-WRITING. By HENRY MORRIS, M. D., late Demonstrator of Therapeutics, Jefferson Medical College, Phila. Revised by W. A. BASTEDO, M. D., Instructor in Materia Medica and Pharmacology at Columbia University. 12mo, 300 pages. Cloth, $1.00 net. *In Saunders' Question-Compend Series.*

## Williams' Practice of Medicine

ESSENTIALS OF THE PRACTICE OF MEDICINE. By W. R. WILLIAMS, M.D., formerly Instructor in Medicine and Lecturer on Hygiene, Cornell University; and Tutor in Therapeutics, Columbia University, N. Y. 12mo of 456 pages, illustrated. *In Saunders' Question-Compend Series.* Double number, $1.75 net.

## Todd's Clinical Diagnosis

A MANUAL OF CLINICAL DIAGNOSIS. By JAMES CAMPBELL TODD, M. D., Associate Professor of Pathology, Denver and Gross College of Medicine. 12mo of 319 pages, with 131 text-illustrations and 10 colored plates. Flexible leather, $2.00 net.

## Bridge on Tuberculosis

TUBERCULOSIS. By NORMAN BRIDGE, A. M., M. D., Emeritus Professor of Medicine in Rush Medical College. 12mo of 302 pages, illustrated. Cloth, $1.50 net.

## Boston's Clinical Diagnosis — Second Edition

CLINICAL DIAGNOSIS. By L. NAPOLEON BOSTON, M. D., Adjunct Professor of Medicine and Director of the Clinical Laboratories, Medico-Chirurgical College, Philadelphia. Octavo of 563 pages, with 330 illustrations, many in colors. Cloth, $4.00 net.

## Arnold's Medical Diet Charts

MEDICAL DIET CHARTS. Prepared by H. D. ARNOLD, M.D., Professor of Clinical Medicine, Tuft's Medical College, Boston. Single charts, 5 cents; 50 charts, $2.00 net; 500 charts, $18.00 net; 1000 charts, $30.00 net.

## Mathews' How to Succeed in Practice

HOW TO SUCCEED IN THE PRACTICE OF MEDICINE. By JOSEPH M. MATHEWS, M. D., LL.D., President American Medical Association, 1898–99. 12mo of 215 pages, illustrated. Cloth, $1.50 net.

## Jakob and Eshner's Internal Medicine and Diagnosis

ATLAS AND EPITOME OF INTERNAL MEDICINE AND CLINICAL DIAGNOSIS. By DR. CHR. JAKOB, of Erlangen. Edited, with additions, by A. A. ESHNER, M. D., Professor of Clinical Medicine, Philadelphia Polyclinic. With 182 colored figures on 68 plates, 64 text-illustrations, 259 pages of text. Cloth, $3.00 net. *In Saunders' Hand-Atlas Series.*

## Lockwood's Practice of Medicine.

**Second Edition, Revised and Enlarged**

A MANUAL OF THE PRACTICE OF MEDICINE. By GEO. ROE LOCKWOOD, M. D., Attending Physician to the Bellevue Hospital, New York City. Octavo, 847 pages, with 79 illustrations in the text and 22 full-page plates. Cloth, $4.00 net.

## Barton and Wells' Medical Thesaurus

A THESAURUS OF MEDICAL WORDS AND PHRASES. By W. M. BARTON, M. D., and W. A. WELLS, M. D., of Georgetown University, Washington, D. C. 12mo of 535 pages. Flexible leather, $2.50 net; thumb indexed, $3.00 net.

## Jelliffe's Pharmacognosy

AN INTRODUCTION TO PHARMACOGNOSY. By SMITH ELY JELLIFFE, PH. D., M. D., of Columbia University. Octavo, illustrated. Cloth, $2.50 net.

## Stevens' Practice of Medicine

**New (8th) Edition**

A MANUAL OF THE PRACTICE OF MEDICINE. By A. A. STEVENS, A. M., M. D., Professor of Pathology, Woman's Medical College, Phila. Specially intended for students preparing for graduation and hospital examinations. Post-octavo, 556 pages, illustrated. Flexible leather, $2.50 net.

## Rolleston on the Liver

DISEASES OF THE LIVER, GALL-BLADDER, AND BILE-DUCTS. By H. D. ROLLESTON, M. D. (CANTAB), F. R. C. P., Physician to St. George's Hospital, London, England. Octavo of 794 pages, illustrated. Cloth, $6.00 net.

## Saunders' Pocket Formulary

**New (9th) Edition**

SAUNDERS' POCKET MEDICAL FORMULARY. By WILLIAM M. POWELL, M. D. Containing 1831 formulas from the best-known authorities. With an Appendix containing Posologic Table, Formulas and Doses for Hypodermic Medication, Poisons and their Antidotes, Diameters of the Female Pelvis and Fetal Head, Obstetrical Table, Diet-list, Materials and Drugs used in Antiseptic Surgery, Treatment of Asphyxia from Drowning, Surgical Remembrancer, Tables of Incompatibles, Eruptive Fevers, etc., etc. In flexible leather, with side index, wallet, and flap, $1.75 net.

## Gould and Pyle's Curiosities of Medicine

ANOMALIES AND CURIOSITIES OF MEDICINE. By GEORGE M. GOULD, M. D., and WALTER L. PYLE, M. D. Octavo of 968 pages, 295 engravings, and 12 full-page plates. Cloth, $3.00 net; Half Morocco, $4.50 net.

## Hatcher and Sollmann's Materia Medica

A TEXT-BOOK OF MATERIA MEDICA: including Laboratory Exercises in the Histologic and Chemic Examination of Drugs. By ROBERT A. HATCHER, PH. G., M. D., and TORALD SOLLMANN, M. D. 12mo of 411 pages. Flexible leather, $2.00 net.

## Eichhorst's Practice of Medicine

A TEXT-BOOK OF THE PRACTICE OF MEDICINE. By DR. H. EICHHORST, University of Zurich. Edited by A. A. ESHNER, M. D. Two octavos of 600 pages each, illustrated. Per set: Cloth, $6.00 net.